

Intraoperative Ultrasound an Economical Tool for Neurosurgeons: A Single-Center Experience

Abstract

Background: Over the past decade, the use of intraoperative image guidance in neurosurgery has gradually gained in importance. Apart from some sophisticated and very expensive techniques, intraoperative ultrasound (IOUS) is a simple and economical technique that allows the surgeon to localize deep-seated lesions under a real-time ultrasonic image display without dissection. The purpose of this study was to present our own preliminary experiences in various (n=1250) neurosurgical procedures carried out at our tertiary care centre in a developing country. **Materials and Methods:** A Prospective study was carried out in our department of neurosurgery at Grant Medical College and Sir J J Group of hospitals from January 2010 to May 2019. IOUS was used during various elective neurosurgical procedures done during this period as given in table no below. A total of 1250 patients, 850 supratentorial lesion, 290 infratentorial lesion and 110 spinal lesion, were included in this study. All studies were performed using an ultrasound machine with variable 3.5–7.5 MHz sector transducers. The echogenicity and pathomorphology between IOUS and computed tomography/magnetic resonance imaging (CT/MRI) of various disease entities were compared. **Results:** Intracranial structures could be well demonstrated by ultrasound once the skull was opened. Most of the intracranial lesions were hyperechoic, except those with a cystic component. IOUS was more sensitive in demonstrating non-enhanced solid lesions and lesions with a cystic component than was preoperative CT/MRI. The border between the tumor and healthy brain was better delineated on IOUS in all cases aiding in tumor resection. **Conclusions:** High-resolution real-time IOUS is a convenient and user-friendly method for identifying, localizing, and characterizing the pathological focus during an operation. Such information is very important and can enhance surgical results.

Keywords: Economical, intraoperative, neurosurgery, ultrasound

Introduction

Intraoperative imaging technology continues to evolve. Reliable intra-operative orientation is the most important aspect of neurosurgery. Frame-based and frame-less neuronavigation, intraoperative ultrasound (IOUS), intraoperative computed tomography (CT), and intraoperative magnetic resonance imaging (iMRI) help the neurosurgeons to localize lesions and their surrounding structures, aid in planning the neurosurgical approach and achieve safe maximal resection. Intraoperative MRI and CT are generally accepted methods to achieve this goal, but the enormous costs involved is the major obstacle in making them available at majority of neurosurgical units worldwide, especially in developing countries. IOUS is comparatively inexpensive, easy to use, and requires little

intraoperative equipment. Recent advances in technology have significantly improved the image quality of IOUS.^[1]

Intraoperative sonography has been used for many years and is an efficient imaging adjunct. Image resolution, as well as the size and engineering of probes, have improved considerably since 1978 when Reid first described the use of sonography for neurosurgical guidance. Three-dimensional (3D) sonography with navigation software, which has been introduced recently, solves the orientation problem experienced previously with 2D sonography. The ability to show real-time anatomical details intraoperatively is valuable and makes the surgical decision easy. Intraoperative sonography is a rapid and effective way to localize the lesions and reduces the risk of injury to surrounding neural structures.^[2]

This is an open access journal, and articles are distributed under the terms of the Creative Commons Attribution-NonCommercial-ShareAlike 4.0 License, which allows others to remix, tweak, and build upon the work non-commercially, as long as appropriate credit is given and the new creations are licensed under the identical terms.

For reprints contact: WKHLRPMedknow_reprints@wolterskluwer.com

How to cite this article: Velho V, Kharosekar HU, Bhople L, Domkundwar S. Intraoperative ultrasound an economical tool for neurosurgeons: A single-center experience. *Asian J Neurosurg* 2020;15:983-8.

Submitted: 05-Jul-2020

Revised: 22-Aug-2020

Accepted: 01-Oct-2020

Published: 21-Dec-2020

**Vernon Velho,
Hrushikesh
Umakant
Kharosekar,
Laxmikant Bhople,
Shilpa
Domkundwar¹**

*Departments of Neurosurgery
and ¹Radiology, Grant
Medical College, Sir J. J.
Group of Hospitals, Mumbai,
Maharashtra, India*

Address for correspondence:

*Dr. Hrushikesh Umakant
Kharosekar,
Department of Neurosurgery,
4th Floor, Grant Medical
College, Sir J. J. Group of
Hospitals, Mumbai - 400 008,
Maharashtra, India.
E-mail: hkhharosekar@gmail.com*

Access this article online

Website: www.asianjns.org

DOI: 10.4103/ajns.AJNS_332_20

Quick Response Code:



The purpose of this study was to review the technical aspects and utility of intraoperative sonography in various ($n = 1250$) neurosurgical procedures carried out at our tertiary care center in a developing country.

Equipment and technique

All ultrasound imaging at our institution was performed using the ultrasound machine of G E technology (no conflict of interest) [Figure 12]. Two scan probes with frequencies, MHz, and 7.5 MHz were used. Cerebral, cerebellar, and brainstem lesions were imaged with a 5MHz transducer, whereas a 7.5-MHz transducer is used for very superficial lesions and spinal lesions. Imaging was done with equal clarity before opening the dura and directly on the brain surface. A sterile surgical glove filled with jelly was used to cover the probe and better imaging, as shown in Figure 12. Ultrasound is safe and it can be used frequently as necessary during the surgery to assist the surgeon. As it provides immediate and accurate localization it usually shortens the operative time. IOUS can easily differentiate solid or necrotic tumors from cystic areas, in fact, better than either CT or magnetic resonance imaging. IOUS provides imaging of normal structures adjacent to various lesions, the relationship to these normal structures can be appreciated before, during, and after resection of a lesion.

Image characteristics– normal structures. (Anatomically constant structures):^[1]

1. Hyperechogenic (bright on iUS) structures include the falx, tentorium, choroid plexus, and pineal gland
2. Isoechogenic (isointense on iUS) structures include the normal brain tissue
3. Hypoechoic (dark on iUS) structures include the brainstem
4. Anechogenic (no signal) structures include the ventricles and basal cisterns [Figure 10].

Materials and Methods

A prospective study was carried out in our department of neurosurgery at Grant Medical College and Sir J. J. Group of hospitals from January 2010 to May 2019. IOUS was during various elective neurosurgical procedures done during this period as given in table no below. A total of 1250 patients, 850 supratentorial lesions, 290 infratentorial lesions, and 110 spinal lesions, were included in this study [Table 1]. IOUS was done in coronal and sagittal planes. Anatomically constant reference points as mentioned above were used for the localization of lesion. Imaging characteristics on IOUS were compared with CT or MRI images available.

Of 850 supratentorial lesions, the most common tumor was astrocytoma followed by meningioma and intraventricular tumors. IOUS was also used for significant number of vascular lesions and orbital tumors [Table 2]. Among the 290 infratentorial lesions, the most common was

Table 1: Site distribution

Site	Number of patients ($n=1250$), n (%)
Supratentorial	850 (68)
Infratentorial	290 (23.2)
Spinal lesions	110 (8.8)
Total	1250

Table 2: Supratentorial lesions

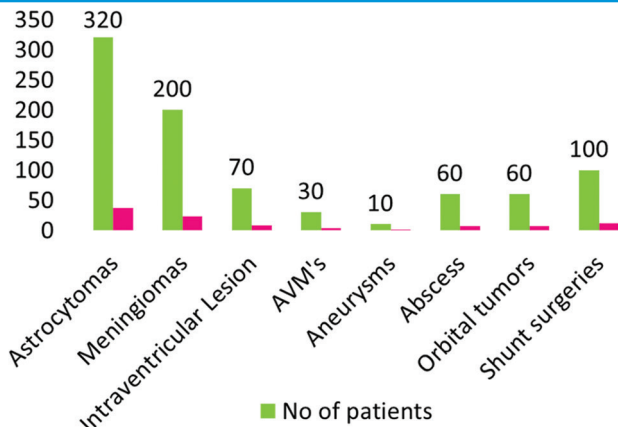


Table 3: Infratentorial lesions

Disease entities	Number of patients ($n=290$), n (%)
Medulloblastomas	80 (27.5)
CP angle meningiomas	50 (17.24)
Acoustic schwannomas	70 (24.13)
CP angle epidermoids	40 (13.79)
Metastasis	50 (17.24)
Total	290

CP – Cerebello-pontine

Table 4: Spinal tumors

Disease entities	Number of patients ($n=110$), n (%)
Intramedullary tumors	50 (45.45)
Ependymomas	30 (27.27)
Nerve sheath tumors	30 (27.27)
Total	110

medulloblastoma followed by cerebellopontine angle meningioma and acoustic schwannoma [Table 3]. For spine surgeries ($n = 110$), it was most commonly used for intramedullary lesions [Table 4].

When the image morphology was compared with CT scan images, out of 320 hypodense lesions on CT scan 300 were hypoechoic on IOUS. Eight hundred and forty lesions were hyperechoic on IOUS out of 860 hyperdense lesions on CT scan. Furthermore, all lesions which were isodense on CT scan were found to be isoechoic to the brain on IOUS [Figure 11].

Various lesions in which IOUS was used are shown below in images.

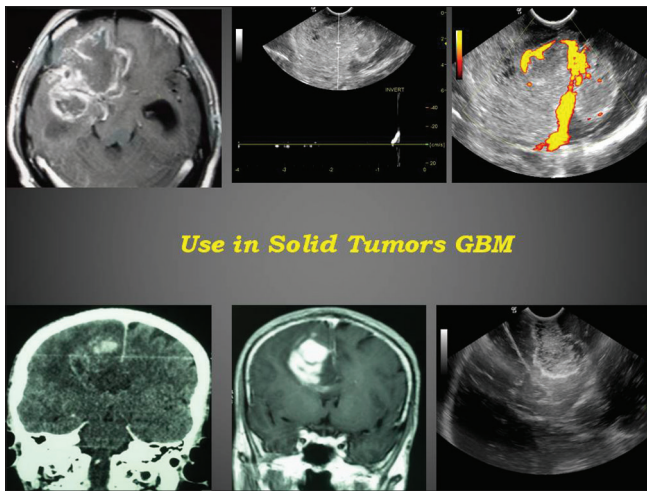


Figure 1: Intraoperative ultrasonography for high-grade glioma

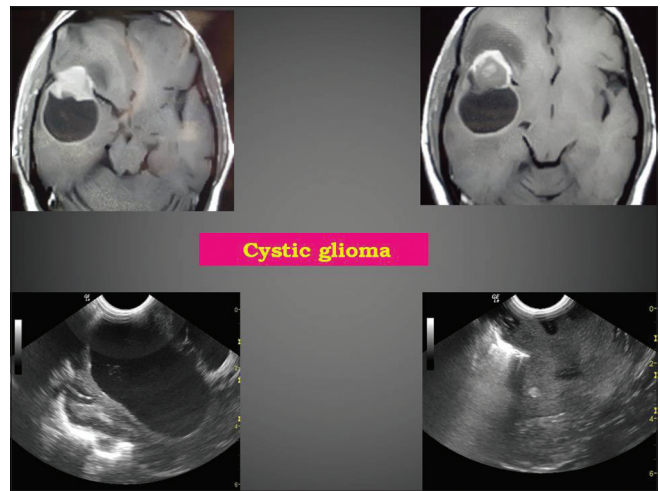


Figure 2: Intraoperative ultrasound in cystic glioma

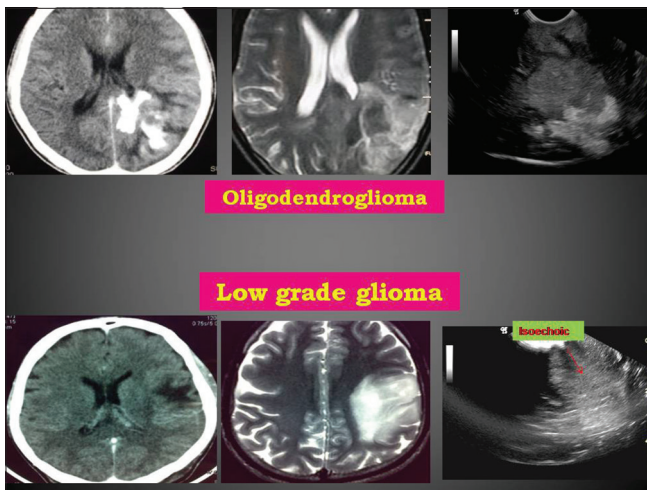


Figure 3: Intraoperative ultrasound in low-grade glioma

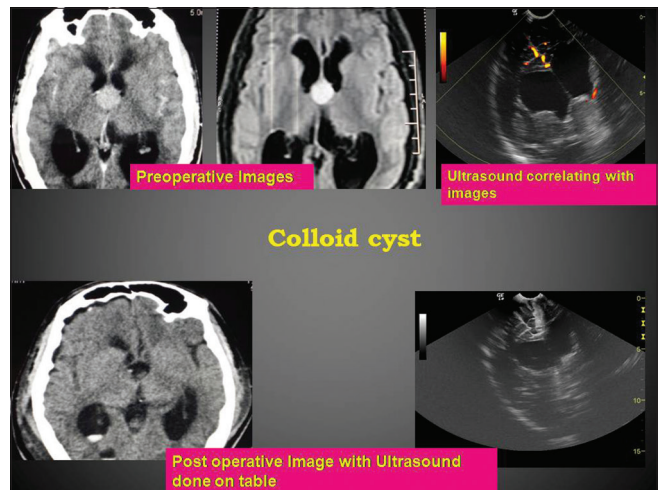


Figure 4: Intraoperative ultrasound for colloid cyst

Discussion

All intracranial tumors, abscess, vascular lesions, and the congenital lesion can be easily imaged using IOUS.

Tumors

High-grade gliomas

Large, high-grade gliomas are not difficult to locate during the surgery. IOUS imaging helps define the borders of a lesion, provides a safe trajectory for excision of nonsurfacing deep-seated tumor.

Figure 1 shows a well-localized corpus callosal glioma with a cystic center. Ultrasound has proven more accurate than CT scanning in differentiating cysts from necrosis since necrotic material is more echogenic also showing the vascularity.

Low-grade gliomas

Localizing a low-grade, infiltrating glioma can be difficult intraoperatively. Even though there may be a sizable and obvious abnormality on CT scanning, the tumor

appears similar to surrounding normal brain parenchyma intraoperatively. Figure 3 shows during IOUS imaging, the low-grade tumor was highly echogenic to the surrounding normal brain. However, still helps in both identification of the tumor and a much better definition of its borders as compared to CT/MRI images.

Metastatic tumors

Localizing a small, solitary, and subcortical metastatic lesion can be difficult and frustrating. With IOUS, lesions of virtually any size and location can be quickly localized and the safest trajectory of excision can be planned. Figure 1 demonstrates the preoperative CT and IOUS images of a small, left-sided, and subcortical metastasis. With this precise localization, an overlying sulcus was separated and the tumor was removed through a 10-mm incision at the base of the sulcus. Extent of tumor excision and residual part can also be confirmed with ultrasound imaging.

Figure 2 is an example of a cystic metastasis and the ultrasound image clearly demonstrates the solid and cystic

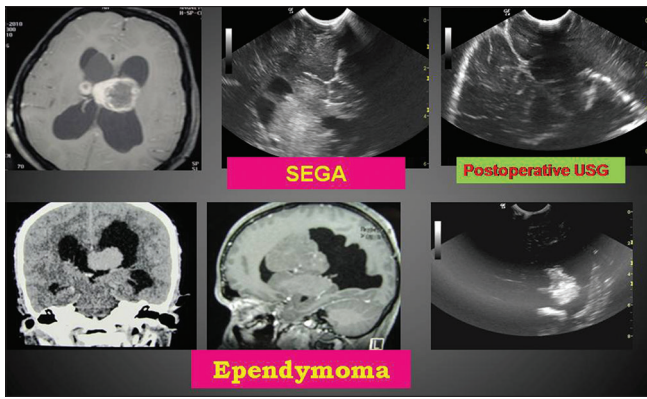


Figure 5: Intraoperative ultrasound in intraventricular lesions

portions of the tumor. This helps the operating surgeon while taking a biopsy of the solid portion of the tumor as well as in resection.

Other tumors

IOUS is useful in surgery for meningiomas which are located deep on the falx, at the base of the skull, intraventricular, or a convexity meningioma to plan the dural opening. Small posterior fossa tumors such as hemangioblastomas, dermoid, ependymomas, and medulloblastomas can be easily visualized with ultrasound and their relationship to the fourth ventricle can be defined [Figure 5].

Figure 4 demonstrates the ultrasound image of the colloid cyst with vascular channels around it preoperatively. Postoperative IOUS shows the complete excision of the colloid cyst.

Spinal tumors

IOUS is very useful during the surgery for spinal lesions for confirming the level and localizing the lesion. We have used IOUS very effectively for intradural extramedullary lesions such as neurofibromas as well as intramedullary lesions such as ependymomas, astrocytomas [Figure 9].

Infectious lesions

Abscesses of varying sizes and consistency can be visualized well with ultrasound. Depending on the stage of development of the abscess, the center may be of low, medium, or high echogenicity. Accurate intraoperative localization allows safe excision and immediate assessment of the residual abscess cavity as shown in Figure 6 in a tubercular abscess in the cerebellum as well as in the frontal lobe.

Vascular lesions

A variety of vascular lesions such as arteriovenous malformations (AVM), cavernoma can be visualized well with IOUS. Doppler mode of IOUS provides accurate imaging of arterial feeders and venous drainage on table. This mode is very helpful in AVM surgery as it shows real-time vascular flow. In tumor surgery, locating the main arteries and veins relative to a tumor, patency of the venous

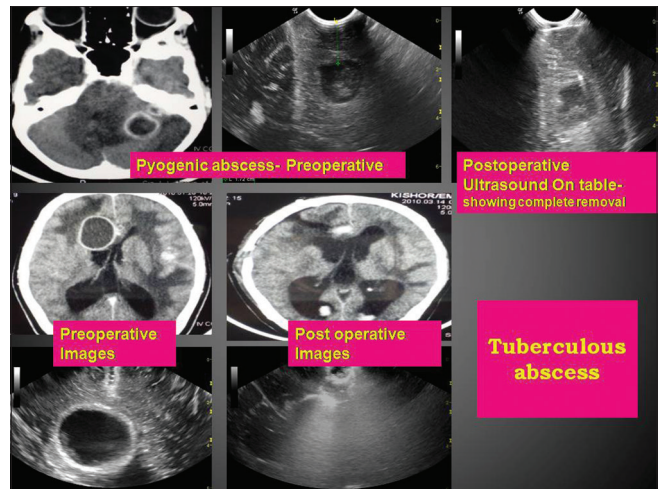


Figure 6: Intraoperative ultrasound in tubercular abscess

sinuses, demonstration of vascularity of the tumor, aid in safe resection. Figure 7.

Hematomas

Intracerebral hematoma, acute or subacute, are seen as hyperechogenic lesion.

Structural abnormalities

Virtually any variation of the ventricular system, including the fourth ventricle, can be imaged with ultrasound. This can be helpful when there are multiple septae within the ventricles during shunting procedures [Figure 8].

Postoperative complications

After dural closure and immediately before reposition of the bone flap, a final check with ultrasound allows the identification of an early intracerebral hematoma or hydrocephalus.^[1,3]

Disadvantages

In spite of the continued progress, IOUS does not deliver the same image quality as iMRI or good quality CT. Its use has a learning curve and is user dependant. Unlike neuronavigation, it is more difficult to point a site and rapidly identify it on the ultrasound screen. Intraoperative bleeding and metal instruments can interfere with image quality. As it does not penetrate the adult bone, it could not be used to plan a craniotomy.

Current and future developments in intraoperative ultrasound^[1]

Three dimensional ultrasound. Intraoperative 3D ultrasound enhances the quality of neuronavigation by allowing repeated intraoperative volumetric updates that can be fused with preoperatively MRI images.

Contrast

Ultrasound imaging with ultrasound contrast agents is an emerging technique for evaluating brain tumors.

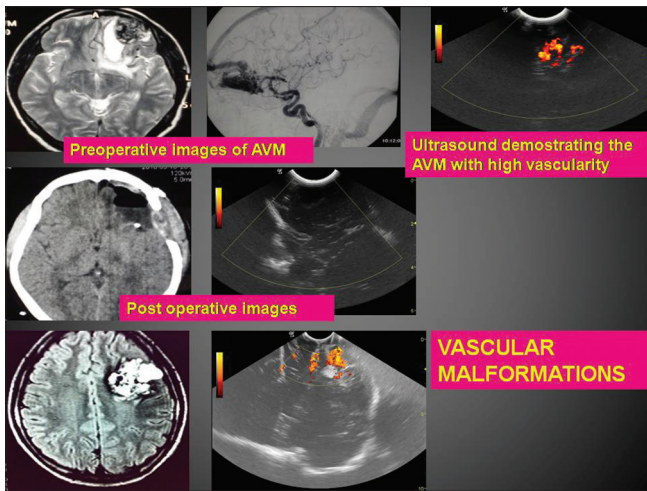


Figure 7: Intraoperative ultrasound in arteriovenous malformation surgery

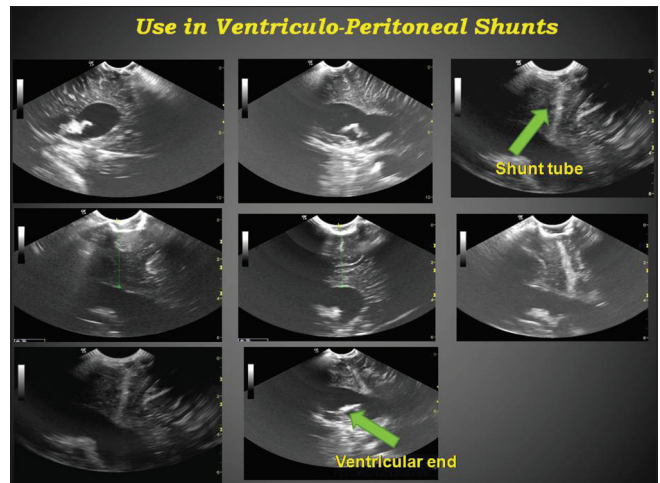


Figure 8: Use of intraoperative ultrasound in inserting Ventriculo peritoneal shunt

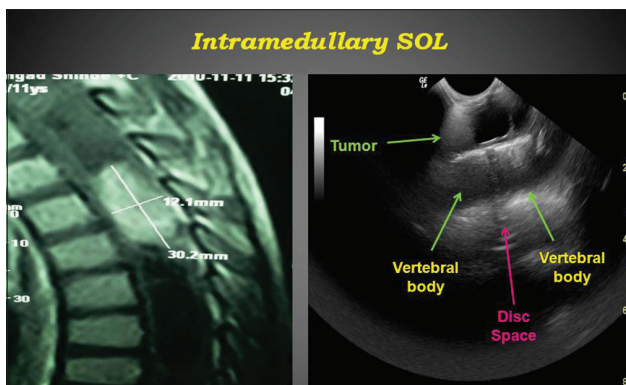


Figure 9: Intraoperative ultrasound in spinal tumors

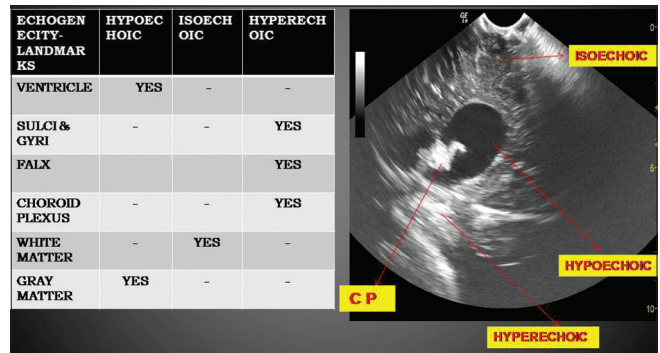


Figure 10: Reference points for intraoperative ultrasound

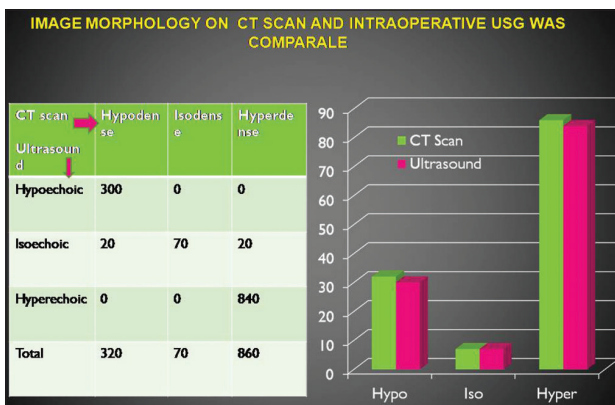


Figure 11: Comparative study of intraoperative ultrasound and computed tomography brain morphology

Contrast-enhanced ultrasound is helpful in the surgery for intracerebral vascular lesions.

Transendoscopic ultrasonography

Significant reductions in the size of ultrasound probes have facilitated the use of IOUS in endoscopic surgery.

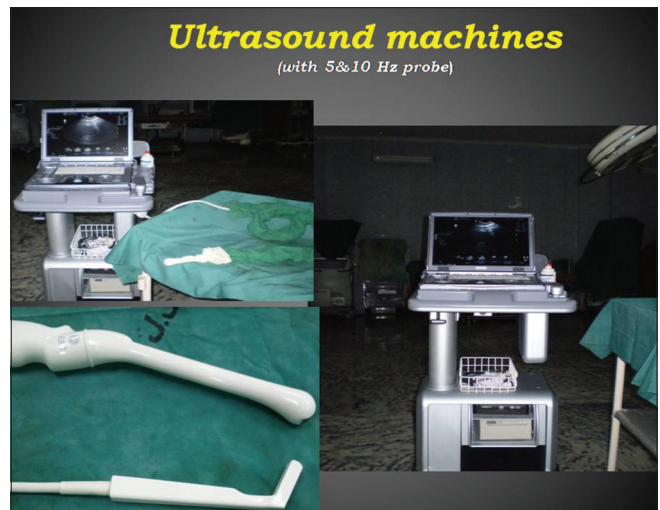

Figure 12: Ultrasound machine used intraoperatively in our department with two probes covered in sterile glove

Therapeutic applications

Magnetic resonance-guided focused ultrasound is a promising interventional method in the thermal coagulative treatment of tumors, vascular malformation, functional

disorders, even for targeted drug delivery, and gene therapy.

Functional imaging

Ultrasound was able to detect the increase in regional cerebral blood flow in the motor cortex compared to baseline during peripheral stimulation in experimental studies on dogs. This allowed the identification of the motor strip intraoperatively using a transdural color Doppler examination.

Conclusions

High-resolution real-time IOUS is a convenient and user-friendly method for identifying, localizing, and characterizing the pathological focus during an operation. Such information is very important and can enhance surgical results. The advantages include reduced exploration and surgical time and presumably,

decreased cost. It is a safe, noninvasive technique and economical tool for neurosurgeon which is easily available. With the advent of newer technologies, the paradigm of IOUS use is ever increasing in the field of neurosurgery.

Financial support and sponsorship

Nil.

Conflicts of interest

There are no conflicts of interest.

References

1. Ivanov M, Wilkins S, Pocata I, Brodbelt A. Intraoperative ultrasound in neurosurgery – A practical guide. *Br J Neurosurg* 2010;24:510-7.
2. Sosna J, Barth MM, Kruskal JB, Kane RA. Intraoperative sonography for neurosurgery. *J Ultrasound Med* 2005;24:1671-82.
3. Chandler WF, Rubin JM. Ultrasound in brain surgery. *World J Surg* 1987;11:558-69.