

C1–C2 Transverse Foramen Decompression by Anterolateral Approach as an Alternative Treatment in Bow Hunter's Syndrome

Abstract

Bow hunter's syndrome (BHS) is characterized with repeating paroxysmal vertigo, nystagmus and ataxia caused by mechanical compression of the vertebral arteries. There is no definite diagnostic and treatment protocol. 26-year-old female patient admitted to the outpatient clinic with complaints of dizziness and seldom falls. Stenosis in the right vertebral artery at the level of C1 and C2 was discovered by the diagnostic modalities. In our patient, we first performed hemilaminectomy by posterior approach. But the symptoms of the patient did not recede, thus we performed decompression with the anterolateral approach by opening the foramens atlas and axis without disrupting the dynamics of the vertebrae and without the need for stabilization. The symptoms of the patient disappeared after this intervention. The patient had complete relief of symptoms at the first year follow up. Surgery must be planned to preserve the life quality of the patient and relieve complaints of the patients. To achieve these goals anterolateral approach must be tried before attempting posterior stabilization.

Keywords: Bow Hunter's Syndrome, decompression, surgical treatment, vertebrobasilar insufficiency

Introduction

Bow Hunter's Syndrome (BHS) is the occurrence of vertebrobasilar symptoms by the mechanical compression of the vertebral arteries.^[1] Repeating paroxysmal vertigo, nystagmus, and ataxia with the rotation of the head are the characteristics of this syndrome.^[1] There is no algorithm for the management of these patients. In this article, we focused on the surgical and diagnostic workup of a patient who admitted with symptoms of paroxysmal vertebrobasilar system insufficiency.

Case Report

A 26-year-old female patient admitted with complaints of dizziness and seldom falling. Magnetic resonance imaging (MRI) and three-dimensional computed tomography (3D CT) imaging revealed stenosis in the right vertebral artery (VA) at the levels C1 and C2. Since the complaints of the patient aggravated by the rotation of her head to the left, dynamic digital subtraction angiography (DSA) imaging was performed. In the DSA imaging, mild VA stenosis was revealed on the right side [Figure 1]. In the angiography, while the patient's head was rotated to the left side,

near-complete occlusion was observed at the VA at C1–C2 levels [Figure 2]. The patient underwent C1 partial hemilaminectomy with the posterior approach, and the fibrous bands were liberated. However, there was no change in the symptoms of the patient. A second operation was needed. In the second operation, transverse foramens of the atlas and the axis were opened, and with the addition of opening the lateral part of the posterior tip of the superior articular process of the atlas, the VA was adequately mobilized. The patient had complete relief of symptoms at the 1st year follow-up.

Discussion

In BHS, hemodynamic vertebrobasilar insufficiency occurs with the narrowing of the vertebral arteries during the rotation of the head. It is characterized with vertigo, nausea, and blurry vision during the rotation of the head.^[1] BHS is usually asymptomatic because of filling from the contralateral VA or the polygon of Willis.^[2] Thus, symptomatic BHS is rare. For the VA which is constricted by the rotation to be symptomatic, the contralateral VA should be hypoplastic, stenotic, or the posterior communicating artery is either absent or insufficient.^[3] The compression

**Serdar Çevik,
Salim Katar¹,
Hakan Hanimoğlu²**

*Department of Neurosurgery,
Agri State Hospital,
Neurosurgery Clinic, Agri,
¹Department of Neurosurgery,
Selahaddin Eyyübi State
Hospital, Neurosurgery Clinic,
Diyarbakir; ²Department of
Neurosurgery, Istanbul Bilim
University, Istanbul, Turkey*

Address for correspondence:

*Dr. Serdar Çevik,
Agri State Hospital,
Neurosurgery Clinic, Agri,
Turkey.
E-mail: dr.serdarcevik@gmail.com*

Access this article online

Website: www.asianjns.org

DOI: 10.4103/ajns.AJNS_338_16

Quick Response Code:



How to cite this article: Çevik S, Katar S, Hanimoğlu H. C1–C2 transverse foramen decompression by anterolateral approach as an alternative treatment in Bow Hunter's Syndrome. *Asian J Neurosurg* 2018;13:411-3.

This is an open access journal, and articles are distributed under the terms of the Creative Commons Attribution-NonCommercial-ShareAlike 4.0 License, which allows others to remix, tweak, and build upon the work non-commercially, as long as appropriate credit is given and the new creations are licensed under the identical terms.

For reprints contact: reprints@medknow.com

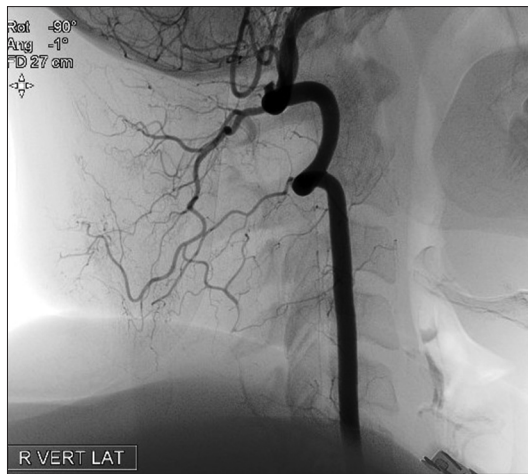


Figure 1: In the digital subtraction angiography imaging, there is mild vertebral artery stenosis in the neutral position

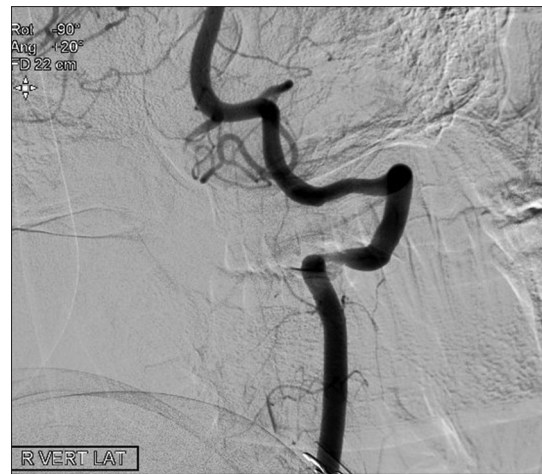

Figure 2: In dynamic digital subtraction angiography imaging, when the head is rotated to the left side, near-complete occlusion was observed at the right vertebral artery at C1–C2 levels

of the VA could be the result of atlantoaxial instability, tension in the paravertebral muscles, severe spondylolysis, and calcification or hypertrophy of the atlanto-occipital membrane.^[3-5] Stenosis of the VA in BHS is most commonly seen at the level of C1–C2, with C6 being the second most common level.^[4] Fibrous bands and formation of osteophytes at level C6 could cause VA stenosis.^[6]

No symptoms were seen when the head is in the neutral position, and occurrence of symptoms of vertebrobasilar insufficiency during the rotation of the head is diagnostic for BHS. It is quite challenging to separate these symptoms from dizziness and nausea caused by vestibular dysfunction.^[2] Thus, rotation of the head while the body is held in place could aid in this distinction. In our patient, MRI and 3D CT were performed to assess the dizziness with the rotation of the head to the left. Thus, dynamic cerebral angiography was performed. In the neutral position, right VA had mild stenosis. In the DSA performed with the patient's head in rotation, near-complete occlusion was observed at the level C1–C2.

There is no adequate guideline for the diagnosis and treatment of BHS. If the symptoms occur with the rotation of C1–C2, stabilization and fusion of C1–C2 could be adequate for the treatment of symptoms. Unfortunately, this technique has 50%–70% risk of preventing the rotation of the head. Utilization of a collar to inhibit the rotation of the neck is one of the noninvasive treatment modalities.^[7] Nonetheless, this treatment option was found useless by most of the patients. The patients reported that the symptoms did not alleviate and quite often they repeated.^[8] Decompression of the VA is another alternative treatment modality. Shimizu *et al.* treated the adhesions of the VA in the transverse foramen and arterial sulcus by C1 hemilaminectomy.^[5] Matsuyama *et al.* utilized VA decompression in nine patients and only reported that three patients did not benefit from the treatment. They performed C1–C2 stabilization and fusion in these patients. Most of

the patients in their study benefitted from decompression alone.^[7]

In our patient, initially, hemilaminectomy with the posterior approach was performed, but the patient's symptoms did not disappear. Thus, a second operation was performed, in which the transverse foramina of the atlas and the axis were cleared widely, and posterolateral part of the superior articular process was added to the decompression. We recommend the anterolateral approach, in which the motion could be preserved before attempt in the fusion of C1–C2, in patients where the posterior approach is unsuccessful. However, posterior C1–C2 stabilization is inevitably in patients who do not benefit from the anterior approach.

Conclusion

Diagnosis and treatment of BHS is quite challenging, and the current data are inadequate. Utilization for dynamic DSA during diagnosis plays an important role in pinpointing mechanical compression that needs to undergo surgical intervention. In patients who do not experience any improvement of symptoms after hemilaminectomy with the posterior approach, the anterolateral approach must be considered with stabilization reserved as the last option.

Financial support and sponsorship

Nil.

Conflicts of interest

There are no conflicts of interest.

References

1. Kuether TA, Nesbit GM, Clark WM, Barnwell SL. Rotational vertebral artery occlusion: A mechanism of vertebrobasilar insufficiency. *Neurosurgery* 1997;41:427-32.
2. Tissington Tatlow WF, Bammer HG. Syndrome of vertebral artery compression. *Neurology* 1957;7:331-40.
3. Bauer RB. Mechanical compression of the vertebral arteries. In:

- Berguer R, Bauer RB, editors. *Vertebrobasilar Arterial Occlusive Disease: Medical and Surgical Management*. New York: Raven Press; 1984. p. 45-71.
4. Mapstone T, Spetzler RF. Vertebrobasilar insufficiency secondary to vertebral artery occlusion from a fibrous band. Case report. *J Neurosurg* 1982;56:581-3.
 5. Shimizu T, Waga S, Kojima T, Niwa S. Decompression of the vertebral artery for bow-hunter's stroke. Case report. *J Neurosurg* 1988;69:127-31.
 6. Miele VJ, France JC, Rosen CL. Subaxial positional vertebral artery occlusion corrected by decompression and fusion. *Spine (Phila Pa 1976)* 2008;33:E366-70.
 7. Matsuyama T, Morimoto T, Sakaki T. Comparison of C1-2 posterior fusion and decompression of the vertebral artery in the treatment of bow hunter's stroke. *J Neurosurg* 1997;86:619-23.
 8. Grossmann RI, Davis KR. Positional occlusion of the vertebral artery: A rare cause of embolic stroke. *Neuroradiology* 1982;23:227-30.