

## Organized Chronic Subdural Hematoma Treated with Middle Meningeal Artery Embolization and Small Craniotomy: Two Case Reports

### Abstract

The most preferred treatment for organized chronic subdural hematoma (OSDH) remains controversial. Although a large craniotomy has been reported to be necessary and effective for the treatment of an OSDH, a craniotomy is associated with postoperative hemorrhagic complications and recurrence. Although middle meningeal artery (MMA) embolization has been reported to be effective for a refractory chronic subdural hematoma (CSDH), its efficacy for an OSDH remains unclear. We report two cases of OSDH treated with MMA embolization followed by hematoma removal via a small craniotomy under local anesthesia with good progress. Case 1: A 71-year-old man underwent a single burr hole irrigation for a CSDH, which failed due to a solid hematoma. He underwent a small craniotomy under local anesthesia after an MMA embolization. During the craniotomy, a small hemorrhage from the hematoma and its outer membrane was observed. Postoperatively, the symptoms disappeared immediately, and the hematoma did not recur. Case 2: A 77-year-old man underwent a burr hole irrigation, but the hematoma was not evacuated because of an OSDH, and he remained in motor aphasia. After an MMA embolization, a craniotomy was performed under local anesthesia. Intraoperative hemorrhage was minimal, and after the craniotomy, his neurological symptoms improved without any recurrence. MMA embolization and hematoma removal with a small craniotomy could be a treatment option for an OSDH.

**Keywords:** Craniotomy, embolization, middle meningeal artery, organized chronic subdural hematoma

### Introduction

An organized chronic subdural hematoma (OSDH) is a subtype of refractory chronic subdural hematomas (CSDHs), and the most preferred treatment for an OSDH remains unknown. An OSDH has been said to require a large craniotomy for radical treatment. However, a craniotomy is associated with a risk of postoperative hemorrhagic complications or recurrence.<sup>[1]</sup> Acute subdural hematomas and other common hemorrhagic complications have been reported in 6%–12% of craniotomies for an OSDH.<sup>[1–3]</sup> In addition, a CSDH, including an OSDH, develops in the elderly with several comorbidities. Some patients cannot undergo a craniotomy under general anesthesia because of underlying diseases.

Recently, the effectiveness of a middle meningeal artery (MMA) embolization for fluid CSDH has been reported. However, to the best of our knowledge, only few

cases have been reported regarding MMA embolization for an OSDH.<sup>[3,4]</sup> In this report, we present two cases of OSDHs treated with MMA embolization followed by a small craniotomy.

### Case Reports

#### Case 1

A 71-year-old man with a history of diabetes mellitus underwent a burr hole irrigation for CSDH. One month later, he visited our hospital complaining of easily falling. Neurologically, he was alert but had dysarthria and slight left hemiparesis. A head computed tomographic (CT) scan revealed a right CSDH with midline shift [Figure 1a]. A single burr hole irrigation was attempted on the day he was admitted, but the hematoma was solid and could not be evacuated via a single burr hole [Figure 1b].

He was subsequently diagnosed as having an OSDH and underwent

**Shigeomi Yokoya,  
Sho Nishii,  
Hidesato Takezawa<sup>1</sup>,  
Tetsuya Katsumori<sup>2</sup>,  
Yasufumi Takagi,  
Yukihiko Goto,  
Hideki Oka,  
Naoto Shiomi,  
Akihiko Hino**

*Departments of Neurosurgery,  
<sup>1</sup>Neurology and <sup>2</sup>Radiology,  
Saiseikai Shiga Hospital,  
Imperial Gift Foundation Inc.,  
Ritto, Shiga, Japan*

**Address for correspondence:**  
Dr. Shigeomi Yokoya,  
2-4-1 Ohashi, Ritto-City,  
Shiga 520-3046, Japan.  
E-mail: yokoya@  
ks.kyorin-u.ac.jp

#### Access this article online

**Website:** www.asianjns.org

**DOI:** 10.4103/ajns.AJNS\_341\_19

#### Quick Response Code:



This is an open access journal, and articles are distributed under the terms of the Creative Commons Attribution-NonCommercial-ShareAlike 4.0 License, which allows others to remix, tweak, and build upon the work non-commercially, as long as appropriate credit is given and the new creations are licensed under the identical terms.

For reprints contact: reprints@medknow.com

**How to cite this article:** Yokoya S, Nishii S, Takezawa H, Katsumori T, Takagi Y, Goto Y, *et al.* Organized chronic subdural hematoma treated with middle meningeal artery embolization and small craniotomy: Two case reports. Asian J Neurosurg 2020;15:421-4.

**Submitted:** 18Nov-2019 **Accepted:** 19-Jan-2020  
**Published:** 07-Apr-2020

an MMA embolization using trisacryl gelatin microspheres (Embosphere®; Nihonkayaku, Tokyo, Japan, 300–500  $\mu$ ) and three Target Helical Ultra (Stryker, Kalamazoo, MI, USA) [Figure 1c and d]. The following day, he underwent a small craniotomy for hematoma removal under local anesthesia. The oozing from the hematoma outer membrane (HOM) and between the HOM and dura mater was minimal during craniotomy, and the organized hematoma was easily evacuated because the intraoperative bleeding could be easily controlled. Postoperatively, his symptoms, dysarthria and slight hemiparesis, disappeared. Postoperative CT demonstrated the disappearance of the hematoma and absence of hemorrhagic complications [Figure 1e]. During 1½-year follow-up period, no recurrence of the right hematoma was found although asymptomatic left CSDH was newly revealed [Figure 1f].

### Case 2

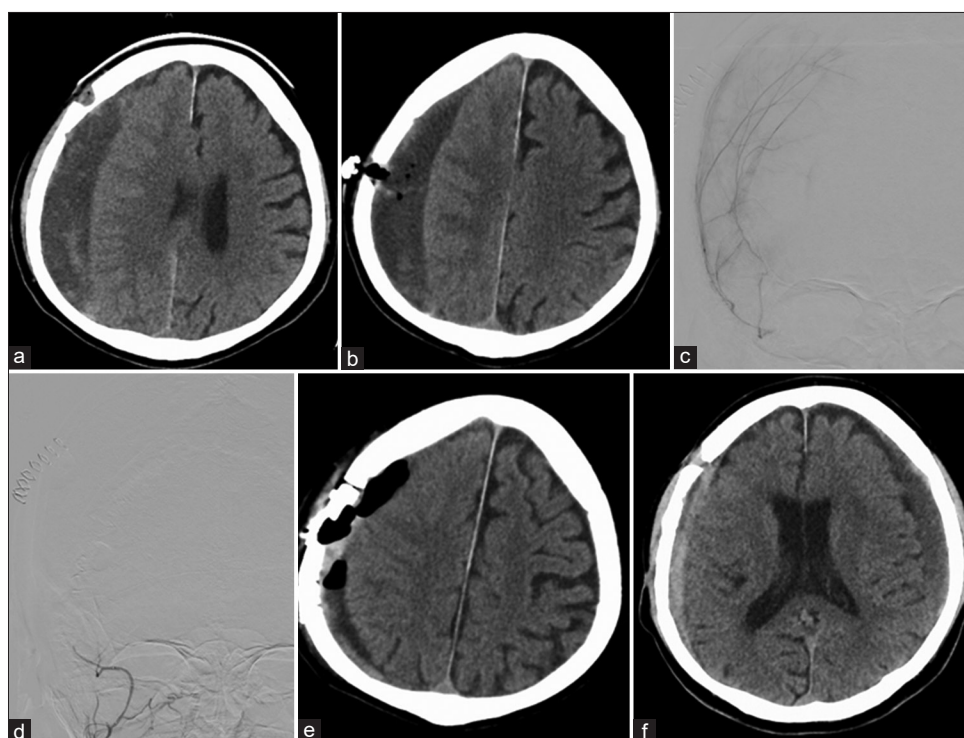
A 77-year-old male man admitted to a local hospital and underwent a burr hole irrigation for a left CSDH [Figure 2a]. The hematoma was organized, and his neurological symptoms of motor aphasia (the difficulty of word recall) and right mild hemiparesis did not improve. He was referred to our hospital for further treatment 2 weeks after the first burr hole surgery. On arrival, a CT scan disclosed a thick hematoma in his left convexity [Figure 2b].

After MMA embolization using Embosphere® (300–500  $\mu$ ) and three Target Helical Ultra (Stryker) [Figure 2c and d], a craniotomy for evacuation of the OSDH was performed under local anesthesia. During the surgery, there was almost no ooze from the HOM or from the hematoma itself [Figure 3]. After the craniotomy, his neurological symptoms improved. A postoperative CT scan showed no acute hemorrhagic complications although the OSDH remained [Figure 2e]. At 1-year follow-up, there was no evidence of any neurological deficits although a CT scan revealed that the hematoma remained [Figure 2f].

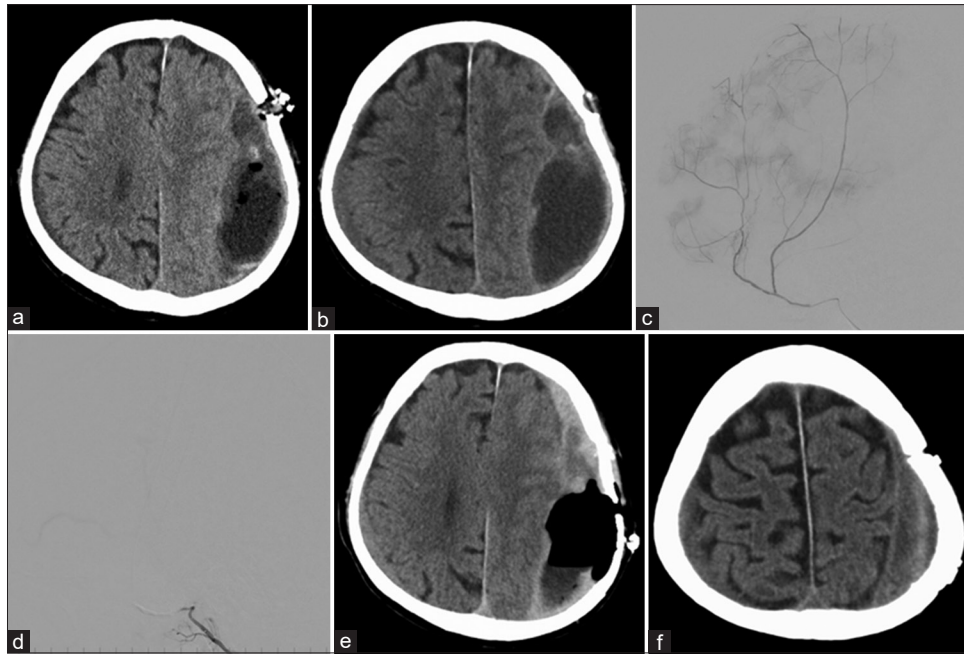### Discussion

These two cases highlighted some important issues. First, an MMA embolization for an OSDH may be useful to prevent recurrences. An MMA embolization for a refractory CSDH has been reported to prevent recurrence; the efficacy for an MMA embolization is more than 90%.<sup>[5,6]</sup> In addition, a recent systematic review reported that the recurrence rate after an MMA embolization for a CSDH is 3%–6%, not restricted to refractory cases.<sup>[7]</sup> A CSDH is considered to develop due to repeated hemorrhage from the outer membrane of a hematoma.<sup>[8]</sup> An MMA embolization is presumed to prevent the recurrence of a CSDH by blocking the blood supply via the dura mater to the outer membrane of the hematoma.<sup>[9]</sup>

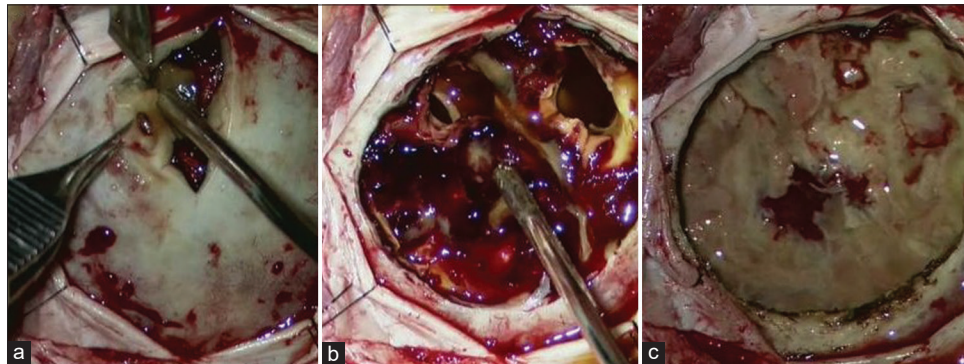
If the theory for preventing the recurrence of an MMA embolism is correct, it is reasonable to assume that an



**Figure 1:** Perioperative images of Patient 1. A 71-year-old man (Patient 1) with an organized chronic subdural hematoma (a) underwent a burr hole irrigation, which failed (b). The middle meningeal artery, having an abnormal vascular network, (c) was embolized using Embosphere® and detachable coils (d). After embolization, a minicraniotomy was performed for hematoma evacuation (e). Although a new asymptomatic left subdural hematoma appeared on the ½-year follow-up, no recurrence was seen on his operated right side (f)



**Figure 2:** Perioperative images of Patient 2. A 77-year-old man (Patient 2) underwent a burr hole irrigation on the left chronic subdural hematoma (a). He was referred to our hospital for further treatment of an organized chronic subdural hematoma 2 weeks after the surgery (b). The abnormal vascular network of middle meningeal artery (c) was embolized using Embosphere® and coils (d). He underwent a craniotomy under local anesthesia (e), and his symptoms were relieved. Although the organized chronic subdural hematoma did not disappear 6 months later at follow-up (f), he is currently asymptomatic



**Figure 3:** Intraoperative photographs of patient 2. During the surgery of Patient 2, a thick outer membrane (a) and liquid–solid hematoma (b), typical of organized chronic subdural hematoma, below the craniotomy site was evacuated (c). The ooze from the dura mater, hematoma, and outer membrane was minimal and was easily stopped by simple manipulation

MMA embolization will be effective for the treatment of an OSDH because an OSDH supplies blood from the MMA via fragile sinusoidal vessels at the junction of the inner and outer membranes.<sup>[2,10]</sup> A previous study has reported three patients treated with MMA embolization, which established its effectiveness in preventing postoperative recurrence of an OSDH.<sup>[3]</sup> Similarly, the two cases in the present study showed no recurrence.

Some precautions can be taken for effective and safe MMA embolization. First, the embolization target should be the distal part of the MMA, where the pre-embolization angiography shows an abnormal vascular network. Therefore, we considered that particle embolic materials were suitable for this procedure and that a coil was not suitable as an embolic material because it could not

embolize the distal part of MMA. Liquid embolic material can occlude the target, but it carries a risk of trapping the catheter. Second, we must be attentive toward dangerous anastomosis collaterals to avoid complications, where the embolic materials accidentally enter dangerous anastomosis collaterals, in particular, the recurrent meningeal artery. We should confirm the absence of a recurrent meningeal artery, guide the microcatheter to the horizontal segment of the MMA, verify that the microcatheter does not wedge the vessel, and embolize the MMA without pressure. Third, the MMA should be occluded at the microcatheter-guided site with a coil to prevent recanalization.

The second important issue is that an MMA embolization may enable hematoma evacuation using a small craniotomy by reducing the amount of intra- and post-operative bleeding.

As shown in Figure 3, hemorrhage was lesser in the craniotomy after the embolization than without precraniotomy embolization. As bleeding could be easily controlled, the operation time decreased and the craniotomy was small and performed under local anesthesia. We resected only a part of the HOM and hematoma beneath the craniotomy site. Although the HOM and hematoma remained, postoperative acute phasic hemorrhage did not occur.

These findings may be contrary to the established consensus that an OSDH requires a large craniotomy under general anesthesia as excision of the HOM is required. This consensus is derived from a report which concluded that partial hematoma removal and remnant HOM, containing fragile capillaries from the dura mater, cause postoperative hemorrhage and hematoma growth.<sup>[2,11-13]</sup> From our experience of these two cases, we hypothesize that partial resection of a hematoma is sufficient to eliminate symptoms and would be sufficient for the treatment of an OSDH under the condition that the blood supply via the dura mater is blocked. Therefore, the procedure would be favorable for patients with a poor general condition.

Whether the residual hematoma could be a cause for relapse is unknown. In fact, one reported case showed recurrence of an OSDH after an MMA embolization using polyvinyl alcohol particles and fibered coils. The recurrence was speculated to be due to the development of new collateral pathways in the HOM as a residual organized hematoma delay healing.<sup>[4]</sup> However, we often observed no increase in the size of the hematomas in patients with OSDH treated conservatively, despite the presence of an OSDH. This fact supports our approach of avoiding the total removal of hematoma in a craniotomy procedure. Although we cannot provide a detailed rationale as to why the MMA embolization was effective, we speculate that the MMA embolization suppressed inflammatory changes and local anticoagulation, contributing to the OSDH relapse.

## Conclusions

Partial removal of an OSDH after an MMA embolization may be a therapeutic option.

## Declaration of patient consent

The authors certify that they have obtained all appropriate patient consent forms. In the form the patient(s) has/have given his/her/their consent for his/her/their images and other clinical information to be reported in the journal. The patients understand that their names and initials will not be published and due efforts will be made to conceal their identity, but anonymity cannot be guaranteed.

## Financial support and sponsorship

Nil.

## Conflicts of interest

There are no conflicts of interest.

## References

1. Balevi M. Organized chronic subdural hematomas treated by large craniotomy with extended membranectomy as the initial treatment. *Asian J Neurosurg* 2017;12:598-604.
2. Callovini GM, Bolognini A, Callovini G, Gammone V. Primary enlarged craniotomy in organized chronic subdural hematomas. *Neurol Med Chir (Tokyo)* 2014;54:349-56.
3. Hayashi S, Nishimoto Y, Nonakla M, Higuchi S, Hosoda K, Miki T, *et al.* Craniotomy following middle meningeal artery embolization for organized chronic subdural hematoma: Three case reports. *Neurosurg Emerg* 2018;23:138-45.
4. Chihara H, Imamura H, Ogura T, Adachi H, Imai Y, Sakai N. Recurrence of a refractory chronic subdural hematoma after middle meningeal artery embolization that required craniotomy. *NMC Case Rep J* 2014;1:1-5.
5. Kim E. Embolization therapy for refractory hemorrhage in patients with chronic subdural hematomas. *World Neurosurg* 2017;101:520-7.
6. Tempaku A, Yamauchi S, Ikeda H, Tsubota N, Furukawa H, Maeda D, *et al.* Usefulness of interventional embolization of the middle meningeal artery for recurrent chronic subdural hematoma: Five cases and a review of the literature. *Interv Neuroradiol* 2015;21:366-71.
7. Waqas M, Vakhari K, Weimer PV, Hashmi E, Davies JM, Siddiqui AH. Safety and effectiveness of embolization for chronic subdural hematoma: Systematic review and case series. *World Neurosurg* 2019;126:228-36.
8. Shim YS, Park CO, Hyun DK, Park HC, Yoon SH. What are the causative factors for a slow, progressive enlargement of a chronic subdural hematoma? *Yonsei Med J* 2007;48:210-7.
9. Mandai S, Sakurai M, Matsumoto Y. Middle meningeal artery embolization for refractory chronic subdural hematoma. Case report. *J Neurosurg* 2000;93:686-8.
10. Fujioka M, Okuchi K, Miyamoto S, Sakaki T, Tsunoda S, Iwasaki S. Bilateral organized chronic subdural haematomas: High field magnetic resonance images and histological considerations. *Acta Neurochir (Wien)* 1994;131:265-9.
11. Ohkawa T, Ogura M, Tanaka S, Terada T, Itakura T. Craniotomy for organized subdural hematoma. *No Shinkei Geka* 2005;33:357-62.
12. Fukazawa K, Sakakura M, Niwa S, Yamamoto J, Kuraishi K, Mouri G. A case of organized chronic subdural hematoma showing an early recurrence after craniotomy. *No Shinkei Geka* 2005;33:389-94.
13. Isobe N, Sato H, Murakami T, Kurokawa Y, Seyama G, Oki S. Six cases of organized chronic subdural hematoma. *No Shinkei Geka* 2008;36:1115-20.