

# Comparison of Ketofol (Combination of Ketamine and Propofol) and Propofol Anesthesia in Aneurysmal Clipping Surgery: A Prospective Randomized Control Trial

## Abstract

**Background:** The maintenance of hemodynamic stability is of pivotal importance in aneurysm surgeries. While administering anesthesia in these patients, the fluctuations in blood pressure may directly affect transmural pressure, thereby precipitating rupture of aneurysm and various other associated complications. We aimed to compare the effects of ketofol with propofol alone when used as an induction and maintenance anesthetic agent during surgical clipping of intracranial aneurysms.

**Materials and Methods:** Forty adult, good-grade aneurysmal subarachnoid hemorrhage patients posted for aneurysm neck clipping were included in the study. The patients were randomized into two groups. One group received a combination of ketamine and propofol (1:5 ratio) and the other group received propofol for induction and maintenance of anesthesia. Intraoperative hemodynamic stability, intraventricular pressure, and quality of brain relaxation were studied in both the groups. **Results:** The patients were comparable with respect to demographic profile, Hunt and Hess grade, world federation of neurological surgeons (WFNS) grade, Fisher grade, duration of anesthesia, duration of surgery, optic nerve sheath diameter, and baseline hemoglobin. Intraoperative hemodynamics were better maintained in the ketofol group during induction, with only 15% of patients having >20% fall in mean arterial pressure (from baseline) intraoperatively, compared to 45% of patients receiving propofol alone ( $P = 0.038$ ). The mean intraventricular pressure values in both the groups were in the normal range and the quality of brain relaxation was similar, with no significant difference ( $P > 0.05$ ).

**Conclusion:** Ketofol combination (1:5) as compared to propofol alone provides better hemodynamic stability on induction as well as maintenance anesthesia without causing an increase in intracranial pressure. Effect of ketofol on cerebral oxygenation and quality of emergence need to be evaluated further by larger multicentric, randomized control trials.

**Keywords:** Aneurysmal clipping, brain relaxation, hemodynamic stability, intracranial pressure, ketofol

## Introduction

In aneurysmal subarachnoid haemorrhage patients undergoing aneurysmal clipping, ketofol when used for induction and maintenance of anesthesia provided better haemodynamic stability as compared to propofol alone. The primary goal during induction of anesthesia for aneurysmal clipping is to prevent any changes in transmural pressure (TMP), TMP being the difference between mean arterial pressure (MAP) and intracranial pressure (ICP). While any uncontrolled increase in MAP during laryngoscopy may precipitate aneurysm rupture, any significant decrease in MAP because of peripheral vasodilation by anesthetics (like

propofol) predisposes to cerebral ischemia. Therefore, a balance should be made between maintaining cerebral perfusion pressure (CPP) and minimizing TMP.<sup>[1]</sup> The objectives during maintenance of anesthesia for aneurysmal clipping include maintaining adequate CPP, cerebral oxygenation, hemodynamic stability, brain relaxation, and avoidance of technique or agents that affect these factors.<sup>[1]</sup>

Several agents, both inhalational and intravenous (IV), have been used for the induction and maintenance of anesthesia in neurosurgery patients. Propofol induces general anesthesia by facilitation of inhibitory neurotransmission mediated by

Ajit Bhardwaj,  
Nidhi Panda,  
Rajeev Chauhan,  
Summit Dev Bloria,  
Neerja Bharti,  
Hemant Bhagat,  
Vishwanath Bhaire,  
Ankur Luthra,  
Rajesh Chhabra<sup>1</sup>,  
Shalvi Mahajan

Departments of Anesthesia  
and Intensive Care and  
<sup>1</sup>Neurosurgery, PGIMER,  
Chandigarh, India

**Address for correspondence:**  
Dr. Rajeev Chauhan,  
Department of Anesthesia  
and Intensive Care, PGIMER,  
Chandigarh - 160 012, India.  
E-mail: dr.rajeevchauhan@  
gmail.com

### Access this article online

**Website:** www.asianjns.org

**DOI:** 10.4103/ajns.AJNS\_346\_19

### Quick Response Code:



**How to cite this article:** Bhardwaj A, Panda N, Chauhan R, Bloria SD, Bharti N, Bhagat H, *et al.* Comparison of ketofol (combination of ketamine and propofol) and propofol anesthesia in aneurysmal clipping surgery: A prospective randomized control trial. Asian J Neurosurg 2020;15:608-13.

**Submitted:** 28-Nov-2019    **Received:** 15-Jan-2020  
**Accepted:** 4-Jun-2020    **Published:** 28-Aug-2020

This is an open access journal, and articles are distributed under the terms of the Creative Commons Attribution-NonCommercial-ShareAlike 4.0 License, which allows others to remix, tweak, and build upon the work non-commercially, as long as appropriate credit is given and the new creations are licensed under the identical terms.

For reprints contact: WKHLRPMedknow\_reprints@wolterskluwer.com

gamma-aminobutyric acid.<sup>[2,3]</sup> Its main advantages are its rapid induction and recovery and reduction of cerebral blood flow (CBF) and ICP. Its main disadvantage lies in its dose-dependent fall in blood pressure (BP).<sup>[4-6]</sup>

Ketamine is an IV anesthetic agent which acts as a n-methyl d-aspartate (NMDA) receptor antagonist. Its mode of action is by inducing anesthesia through thalamocortical dissociation.<sup>[7]</sup> Several advantages have been attributed to ketamine starting from its analgesic effect, maintenance of muscle tone, protecting airway reflexes, spontaneous respiration, and maintenance of greater CPP. However, the side effects of ketamine include emergence hallucinations, elevation of BP, and heart rate (HR) due to its sympathomimetic effects.

It was suggested previously that ketamine increases ICP.<sup>[8,9]</sup> Of late, several studies have been carried out on this topic, and the role of ketamine with regard to ICP has been reevaluated. Some studies have shown that during ketamine use, ICP depends on several variables such as controlled ventilation and use of other drugs.<sup>[10,11]</sup> During sedation and controlled ventilation, ketamine does not increase CBF and ICP but maintains a greater CPP.<sup>[12]</sup> In patients with severe head injury, the use of ketamine has been found to be safe under controlled settings.<sup>[13]</sup> Ketamine when used for sedation as well as inducing agent for rapid sequence induction in traumatic brain injury patients did not increase ICP.<sup>[14]</sup>

It was anticipated that combining propofol and ketamine (ketofol) will result in a mixture which has additive effects so that the dose of individual drugs can be reduced and benefit of both the drugs such as analgesia, hypnosis, amnesia, and hemodynamic stability can be achieved. Ketofol is a stable mixture and has been used effectively in operation theater as well as in ambulatory settings.<sup>[15-17]</sup> Samar *et al.* studied the effects of ketofol for sedation in awake craniotomy procedures and found it to be safe and efficient.<sup>[18]</sup> We had hypothesized that ketofol when used for induction and maintenance of anesthesia during intracranial aneurysm clipping surgery will provide better intraoperative hemodynamic stability than propofol alone.

The aim of this study was to compare the effects of the combination of ketamine and propofol (ketofol) with propofol alone as an agent for induction and maintenance of anesthesia during intracranial aneurysm clipping surgery. The variables we compared were intraventricular pressure, hemodynamic stability, and quality of brain relaxation.

## Materials and Methods

This prospective, randomized, double-blinded controlled trial was conducted after the Institute Ethics Committee approval and written informed consent. The study was conducted between July 2017 and June 2018 in accordance with the principles of the Declaration of Helsinki. Forty

patients aged 18–75 years, posted for aneurysm neck clipping following aneurysmal subarachnoid hemorrhage, were recruited in the study. Only the patients who were conscious and WFNS, Hunt and Hess, and Fisher Grade 1 or 2 after diagnosis of aneurysmal bleed were included in this study. Patients who were unconscious or had raised ICP (optic nerve sheath diameter >5 mm) were excluded. Furthermore, patients with coronary artery disease, giant aneurysm, psychiatric disease, or any other neurological or neurodegenerative disorders were excluded from the study.

Randomization was done using a computer-generated random number table. Group P comprised patients who received propofol for induction and maintenance of anesthesia, and Group KP received a combination of ketamine and propofol (1:5 by weight in mg) for induction and maintenance of anesthesia. We used a low-dose ketamine–propofol mixture in the ratio of 1:5 anticipating that it would be just enough to prevent fall in MAP induced by vasodilation due to propofol and also not cause too much sympathomimetic effect so as to raise MAP/TMP. In a few pilot cases, we used different combinations of ketamine and propofol (1:3–1:6) to ascertain the optimal ratio for our study.

## Study drug preparation

In a 50-ml syringe, 48 ml study drug was loaded. Group P had 48 ml of propofol 1% (10 mg/ml). Group KP had 40 ml of propofol 1% (10 mg/ml) + 8 ml of ketamine (10 mg/ml). For preparation of 10 mg/ml of ketamine, we diluted a 2-ml ampoule of 50 mg/ml ketamine (Aneket, Neon Laboratories, India) with 8 ml of normal saline in a 10-ml syringe.

Preinduction monitoring included electrocardiography, pulse oximetry, noninvasive BP, entropy sensors, and urine output. The patients were administered fentanyl 2 µg/kg before induction, followed by 1 µg/kg/h as infusion. Patients were induced and maintained with propofol in the P group and with ketofol in the KP group. Lignocaine 1.5 mg/kg was administered before laryngoscopy to attenuate the hemodynamic stress response. Vecuronium was used for intubation in the doses of 0.1 mg/kg and subsequently 0.02 mg/kg to maintain <2 twitches on the “train-of-four” neuromuscular monitor. PaCO<sub>2</sub> was kept between 32 and 35 mmHg, and ventilation was maintained with 50% oxygen and air in all the patients. For beat-to-beat monitoring of BP and blood gas analysis, an arterial catheter was placed in the radial artery. Nasopharyngeal thermometer probe was placed to measure the body temperature and normothermia (36°C–37°C) maintained in all the patients with the help of forced-air warming blankets. Normal saline was used as intraoperative fluid. The surgery was performed by an experienced neurosurgeon (>5 years of experience) who also inserted intraventricular catheter for ICP measurement and evaluated the brain relaxation according to the scoring system.

Hemodynamic parameters (HR and MAP),  $\text{SPO}_2$ , and end-tidal  $\text{CO}_2$  ( $\text{EtCO}_2$ ) were recorded at different time periods from the beginning of anesthesia to the end of surgery. Whenever MAP fell to  $<20\%$  of the baseline value, IV fluid bolus of 200 ml was infused and study drug infusion was decreased by 10%–20%. If hypotension still continued, boluses of phenylephrine 50  $\mu\text{g}$  were administered at an interval of 5 min. If even after 3 phenylephrine boluses hypotension persisted, then dopamine infusion was started at 5  $\mu\text{g}/\text{kg}/\text{min}$ .

If MAP increased  $>20\%$  of the baseline value, study drug infusion was increased by 10%–20%. If hypertension continued, then boluses of esmolol 0.5–1 mg/kg IV over 30 s were given and repeated at a 5-min interval. Number of boluses of rescue drugs and total dose of rescue drugs used were noted.

Intraventricular ICP was measured by the operating surgeon after approximately 1 h of induction of anesthesia and infusion of study drug. After burr hole craniotomy and dural reflection, the ventriculostomy catheter with the stylet *in situ* was introduced into the lateral ventricles. The stylet was removed, and without any loss of cerebrospinal fluid, a high-pressure tubing was attached to the pressure transducer system and to the ventriculostomy catheter to record the opening pressure of ventricle on the monitor. The recording was noted at 1-min intervals for 3 min. The maximum of three values was considered as the intraventricular ICP of the patient.

A senior neurosurgeon with more than 5 years of experience and blinded to group allocation assessed brain relaxation score after opening of dura mater as described below-

- Grade 1: The brain surface jutting out or expanding beyond the craniotomy margin and brain pulsation not clearly defined
- Grade 2: Brain surface at the level of craniotomy margins and brain pulsations observed faintly
- Grade 3: Brain surface lying just below the surface of craniotomy region margin and brain pulsations well seen
- Grade 4: Brain surface below the surface of craniotomy margin and well retracted into the cranial cavity with good brain pulsations.

### Statistical analysis

The statistical analysis was carried out using the Statistical Package for the Social Sciences (SPSS Inc., Chicago, IL, USA, version 16.0 for Windows). Mean and medians were calculated for all quantitative variables. For measures of dispersion, standard deviation or standard error was calculated. Normality of data was checked by measures of Kolmogorov–Smirnov tests of normality. For normally distributed data, means of two different groups were compared using *t*-test. For skewed data and ordinal data, Mann–Whitney test was applied. Qualitative or categorical

variables were described as frequencies and proportions. Proportions were compared using Chi-square or Fisher's exact test, whichever was applicable. For time-related normally distributed data, repeated ANOVA was applied. All statistical tests were two-sided and were performed at a significance level of alpha error of 0.05.

### Results

A total of 43 patients were assessed for eligibility to participate in the study and 40 patients were selected for inclusion in the study. They were randomised into 2 groups of 20 patients each [Flowchart 1]. In both the groups, patient demographic characteristics and baseline variables were comparable [Table 1]. Baseline hemoglobin levels, intraoperative crystalloid administration, and intraoperative urine output were found to be comparable between the two groups [Table 1].

Intraoperative anesthetic drug consumption was compared in the two groups. We found that intraoperative propofol requirement was significantly less in the KP group ( $P = 0.035$ ) [Table 2]. Intraoperative fentanyl and muscle relaxant consumption was comparable in the two groups.

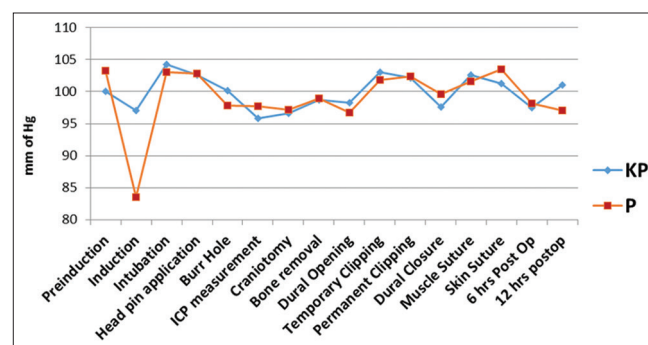


Figure 1: Mean arterial pressure

Table 1: Demographic parameters in the 2 groups

Parameters	KP (n=20)	P (n=20)	P
Age (years)	48.35±12.419	50.15±8.689	0.598
Sex (male/female)	14/6	11/9	0.327
Weight (kg)	64.55±8.556	59.65±8.45	0.076
Hunt and Hess (1/2)	17/3	17/3	1.000
WFNS (1/2)	16/4	16/4	1.000
Fisher (1/2)	1/19	1/19	0.311
ONSD (mm)	4.79±1.483	4.73±1.418	0.199
Surgery time (min)	158.4±24.648	152±16.255	0.338
Anesthesia time (min)	184.3±40.566	182.75±15.515	0.774
Baseline hemoglobin (g)	13.065±1.346	13.325±1.646	0.588
Intraoperative crystalloids (ml)	2282.5±246.128	2197.5±271.679	0.306
Intraoperative urine output (ml)	865±202.029	854±123.391	0.836

KP – Ketofol; P – Propofol; ONSD – Optic nerve sheath diameter

The intraoperative hemodynamic parameters are described in Table 3. The preinduction MAP was comparable in both the groups ( $P = 0.101$ ), but there was a significant fall in MAP during induction in Group P as compared to Group KP ( $P = 0.038$ ). During the rest of the surgery, the mean BP remained comparable between the two groups. The HR and EtCO<sub>2</sub> were comparable in both the groups at all times intraoperatively [Table 3 and Figure 1].

The mean ICP values (measured using intraventricular catheter) were also comparable between the two groups. The mean ICP in the ketofol group was 11.64 mmHg and in the propofol group was 11.47 mmHg ( $P = 0.802$ ). ICP values ranged from 8.7 to 16 mmHg in the KP group and from 8.7 to 15 mmHg in the P group.

Brain relaxation scores in both the study groups were comparable [Table 4]. Median was Grade 3 in both the groups ( $P = 0.977$ ) [Table 5].

The mean quantity of phenylephrine required to treat hypotension was 15 µg in Group KP and 42.5 µg in Group P which came out to be statistically significant [Table 6].

The mean quantity of esmolol required to treat hypertension was 16 mg in the KP group and 17 mg in the P group which was not statistically significant ( $P = 0.89$ ).

**Table 2: Anesthesia drugs**

Drugs	KP (n=20)	P (n=20)	P
Propofol (mg)	778	871.5	0.035*
Vecuronium (mg)	14.65	14.50	0.796

\*A  $P$  value of less than 0.05 denotes a significant difference. KP – Ketofol; P – Propofol

## Discussion

There are no documented studies to our knowledge which have used a mixture of ketamine and propofol for induction and maintenance of anesthesia in surgery for intracranial aneurysmal clipping. In our study, the mean intraventricular ICP in Group KP was 11.64 mmHg, and in Group P, it was 11.47 mmHg ( $P = 0.802$ ). The mean ICP values in both the groups were in the normal range. This suggests that ketamine, when mixed with propofol in the ratio of 1:5, did not increase ICP in patients undergoing intracranial aneurysm clipping surgery. Several studies from the 1970s had shown an association between ketamine and increased ICP in patients who had an intracranial pathology such as obstructive hydrocephalus, aqueductal stenosis, and intracranial lesions causing mass effects.<sup>[19,20]</sup> When healthy patients on mechanical ventilation were given ketamine for sedation, it was found that there was no statistically significant increase in ICP.<sup>[21]</sup> Mayberg *et al.* in their landmark study found a statistically significant reduction in ICP when ketamine was given as a 1 mg/kg bolus.<sup>[10]</sup> Albanese *et al.* studied the effect of ketamine on ICP during propofol-based sedation in TBI.<sup>[12]</sup> They found that ketamine reduced ICP irrespective of the dose used and concluded that in ventilated patients with TBI who are sedated with propofol, ketamine decreases ICP mildly.

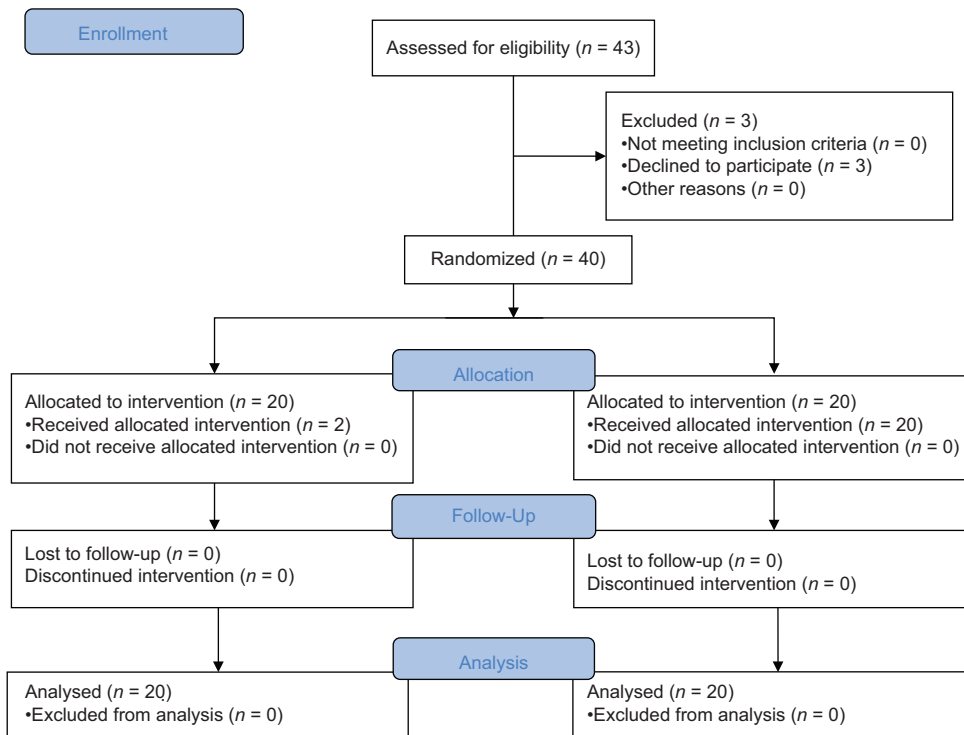
We also found in our study that the combination of ketamine and propofol, when used along with fentanyl infusion with controlled ventilation and maintaining EtCO<sub>2</sub> between 35 and 40 mmHg, did not increase ICP. The mean ICP in both the study groups was within the normal range of ICP, and the difference was not statistically significant.

**Table 3: Mean arterial pressure (mmHg), heart rate, and end-tidal CO<sub>2</sub>**

	MAP			Heart rate			EtCO <sub>2</sub>		
	Group KP (n=20)	Group P (n=20)	P	Group KP (n=20)	Group P (n=20)	P	Group KP (n=20)	Group P (n=20)	P
Preinduction	100.1±6.593	103.25±5.169	0.101	81.1±3.04	80.95±4.54	0.903			
Induction	97.0±8.651	83.5±4.658	0.038*	83.3±6.626	82.0±7.130	0.554	36.10±1.371	35.84±0.876	0.595
Intubation	104.25±8.771	103.0±7.448	0.630	90.0±7.820	88.7±8.21	0.611	35.85±1.424	36.20±1.056	0.383
Head pin application	102.55±6.82	102.85±8.20	0.883	89.05±6.428	89.75±5.928	0.722	36.15±1.226	36.05±0.759	0.758
Burr hole	100.2±7.991	97.85±7.227	0.311	86.4±7.70	86.65±5.48	0.906	36.05±1.146	36.15±0.988	0.769
ICP measurement	95.80±7.997	97.7±7.241	0.436	78.50±7.64	81.0±7.10	0.291	35.75±1.333	36.20±1.005	0.235
Craniotomy	96.6±7.486	97.15±6.319	0.803	80.4±6.931	79.15±7.154	0.578	35.90±1.483	35.90±0.718	1.000
Bone flap removal	98.7±7.049	98.9±6.032	0.924	78.3±9.131	75.85±7.088	0.349	36.25±1.118	35.75±0.851	0.120
Dural opening	98.3±7.63	96.7±7.01	0.452	78.95±11.696	76.40±10.154	0.466	35.95±1.638	35.90±0.912	0.906
Temporary clipping	103.05±10.802	101.85±7.86	0.676	77.2±8.42	74.75±7.538	0.339	35.75±1.650	35.70±0.733	0.902
Permanent clipping	102.2±7.716	102.4±8.444	0.938	77.25±8.058	75.25±8.239	0.442	35.85±1.565	35.75±0.786	0.800
Dural closure	97.6±7.387	99.65±7.012	0.376	76.90±8.358	74.20±7.367	0.285	36.15±1.424	36.25±1.118	0.806
Muscle suture	102.56±8.74	101.6±6.4	0.697	78.90±6.897	77.7±8.215	0.620	36.10±1.371	35.81±0.872	0.595
Skin suture	101.25±6.81	103.45±6.31	0.296	83.20±8.218	83.7±6.317	0.116	36.10±1.371	35.84±0.876	0.595
6 h postoperative	95.78±7.889	97.68±7.239	0.435	80.38±6.929	79.11±7.143	0.577	35.85±1.424	36.20±1.056	0.383
12 h postoperative	101.9±7.67	103.0±6.89	0.670	81.1±7.545	82.7±5.765	0.335	36.15±1.226	36.05±0.759	0.758

The values were expressed as mean±SD and were analyzed using independent  $t$ -test. \* $P < 0.05$  was considered significant. SD – Standard deviation; ICP – Intracranial pressure; KP – Ketofol; P – Propofol; EtCO<sub>2</sub> – End-tidal CO<sub>2</sub>





Flow Chart 1: CONSORT diagram

Table 4: Brain relaxation grade

Grade	Number of patients in each grade		P
	KP (n=20)	P (n=20)	
I	1	1	1
II	5	6	0.723
III	11	9	0.527
IV	3	4	0.922

KP – Ketofol; P – Propofol

Table 5: Median and interquartile range of brain relaxation grade

Group	Median grade	Interquartile range	P
KP	III	II-III	0.977
P	III	II-III	

Median and IQR were calculated using Mann–Whitney test. IQR – Interquartile range; KP – Ketofol; P – Propofol

Table 6: Mean quantity of rescue drugs used in intraoperative period to maintain mean arterial pressure

Drugs	KP (n=20)	P (n=20)	P
Phenylephrine (µg)	15	42.5	0.015*
Esmolol (mg)	16	17	0.89

\*A p value of less than 0.05 denotes a significant difference. MAP – Mean arterial pressure; KP – Ketofol; P – Propofol

Brain relaxation is an important aspect of anesthetic care during intracranial surgery. Optimal brain relaxation improves the surgeon’s operating conditions and is likely to minimize the severity of retraction injury, with the potential for providing the patient with a better outcome.

Hayes and Slocum specifically studied the problem of a tight brain for the first time.<sup>[22]</sup> The average median brain relaxation score in both the groups was measured as 3 on a four-grade scale, i.e., brain surface lies just below the surface of craniotomy margin and brain pulsations well seen. Hence, we found the same quality of brain relaxation in both the study groups ( $P > 0.05$ ). Several studies have shown that in comparison to inhalational anesthetics, IV anesthetics reduce ICP, but various anesthetic techniques have not shown any difference in brain relaxation.<sup>[23-26]</sup> We observed no difference in brain relaxation when ketofol was used instead of propofol.

Hemodynamic stability was also compared between both the study groups. There was >20% fall in MAP in 45% of patients receiving propofol alone as compared to only 15% of patients receiving a combination of ketamine and propofol during induction of anesthesia ( $P = 0.038$ ). Furthermore, ketofol provided better hemodynamics during maintenance of anesthesia. We ascribe this to sympathomimetic action of ketamine because of which there was not as much fall in MAP with ketofol. Earlier studies with ketofol have shown that MAP is better maintained with ketofol as compared to other IV anesthetic agents.<sup>[27]</sup> We used a low-dose ketamine–propofol mixture in the ratio of 1:5 anticipating that it would be just enough to prevent fall in MAP induced by vasodilation due to propofol and also not cause too much sympathomimetic effect so as to raise MAP/TMP. In a few pilot cases, we used a different combination of ketamine and propofol (1:3–1:6) to ascertain the optimal ratio for our study.

We found that ketofol under controlled ventilation did not increase ICP, provided better hemodynamic stability as compared to propofol alone, and was comparable with propofol in quality of brain relaxation during surgery. We opine that ketofol can have an important role as an induction and maintenance agent for neurosurgical patients undergoing aneurysmal clipping. Its possible advantages over other anaesthetic agents include stable haemodynamics and comparable intraoperative brain conditions. Ketofol as an induction and maintenance anesthetic can provide a suitable alternative to propofol. However, larger, multicentric studies are required to study the effects of ketofol in neuroanesthesia before we can be certain of its benefits.

Our study had a few limitations; first, we enrolled only good-grade aneurysms; hence, the results of the study drug cannot be extrapolated to poor-grade aneurysms. Second, we did not measure cerebral oxygenation which could have shown the effect of study drugs on cerebral metabolism and in assessing the presence of ischemia or hyperemia during surgery.

#### Financial support and sponsorships

Nil.

#### Conflicts of interest

There are no conflicts of interest.

#### References

- Priebe HJ. Aneurysmal subarachnoid haemorrhage and the anaesthetist. *Br J Anaesth* 2007;99:102-18.
- Trapani G, Altomare C, Liso G, Sanna E, Biggio G. Propofol in anesthesia. Mechanism of action, structure-activity relationships, and drug delivery. *Curr Med Chem* 2000;7:249-71.
- Kotani Y, Shimazawa M, Yoshimura S, Iwama T, Hara H. The experimental and clinical pharmacology of propofol, an anesthetic agent with neuroprotective properties. *CNS Neurosci Ther* 2008;14:95-106.
- Jones GM, Doepker BA, Erdman MJ, Kimmons LA, Elijovich L. Predictors of severe hypotension in neurocritical care patients sedated with propofol. *Neurocrit Care* 2014;20:270-6.
- Bryson HM, Fulton BR, Faulds D. Propofol. An update of its use in anaesthesia and conscious sedation. *Drugs* 1995;50:513-59.
- AstraZeneca. Diprivan (propofol) Injectable Emulsion for IV Administration Prescribing Information. Wilmington, DE: AstraZeneca; 2001.
- Zanos P, Moaddel R, Morris PJ, Riggs LM, Highland JN, Georgiou P, *et al.* Ketamine and ketamine metabolite pharmacology: Insights into therapeutic mechanisms. *Pharmacol Rev* 2018;70:621-60.
- Takeshita H, Okuda Y, Sari A. The effects of ketamine on cerebral circulation and metabolism in man. *Anesthesiology* 1972;36:69-75.
- Shapiro HM, Wyte SR, Harris AB. Ketamine anesthesia in patients with intracranial pathology. *Br J Anaesth* 1972;44:1200-4.
- Mayberg TS, Lam AM, Matta BF, Domino KB, Winn HR. Ketamine does not increase cerebral blood flow velocity or intracranial pressure during isoflurane/nitrous oxide anesthesia in patients undergoing craniotomy. *Anesth Analg* 1995;81:84-9.
- Strebel S, Kaufmann M, Maître L, Schaefer HG. Effects of ketamine on cerebral blood flow velocity in humans. Influence of pretreatment with midazolam or esmolol. *Anaesthesia* 1995;50:223-8.
- Albanèse J, Arnaud S, Rey M, Thomachot L, Alliez B, Martin C. Ketamine decreases intracranial pressure and electroencephalographic activity in traumatic brain injury patients during propofol sedation. *Anesthesiology* 1997;87:1328-34.
- Bourgoin A, Albanèse J, Wereszczynski N, Charbit M, Vialet R, Martin C. Safety of sedation with ketamine in severe head injury patients: Comparison with sufentanil. *Crit Care Med* 2003;31:711-7.
- Sehdev RS, Symmons DA, Kindl K. Ketamine for rapid sequence induction in patients with head injury in the emergency department. *Emerg Med Australas* 2006;18:37-44.
- Weatherall A, Venclovas R. Experience with a propofol-ketamine mixture for sedation during pediatric orthopedic surgery. *Paediatr Anaesth* 2010;20:1009-16.
- Erdogan Kayhan G, Yucel A, Colak YZ, Ozgul U, Yologlu S, Karlidag R, *et al.* Ketofol (mixture of ketamine and propofol) administration in electroconvulsive therapy. *Anaesth Intensive Care* 2012;40:305-10.
- Rapeport DA, Martyr JW, Wang LP. The use of "ketofol" (ketamine-propofol admixture) infusion in conjunction with regional anaesthesia. *Anaesth Intensive Care* 2009;37:121-3.
- Samar A, Henry A, Enas M, Ehab M. Preliminary evaluation of ketofol based sedation for awake craniotomy procedures. *Egypt J Anaesthesia* 2010;26:293-7.
- Gardner AE, Olson BE, Lichtiger M. Cerebrospinal-fluid pressure during dissociative anesthesia with ketamine. *Anesthesiology* 1971;35:226-8.
- Wyte SR, Shapiro HM, Turner P, Harris AB. Ketamine-induced intracranial hypertension. *Anesthesiology* 1972;36:174-6.
- Gibbs JM. The effect of intravenous ketamine on cerebrospinal fluid pressure. *Br J Anaesth* 1972;44:1298-302.
- Hayes GJ, Slocum HC. The achievement of optimal brain relaxation by hyperventilation techniques of anesthesia. *J Neurosurg* 1962;19:65-70.
- Petersen KD, Landsfeldt U, Cold GE, Petersen CB, Mau S, Hauerberg J, *et al.* Intracranial pressure and cerebral hemodynamic in patients with cerebral tumors: A randomized prospective study of patients subjected to craniotomy in propofol-fentanyl, isoflurane-fentanyl, or sevoflurane-fentanyl anesthesia. *Anesthesiology* 2003;98:329-36.
- Talke P, Caldwell JE, Richardson CA. Sevoflurane increases lumbar cerebrospinal fluid pressure in normocapnic patients undergoing trans-sphenoidal hypophysectomy. *Anesthesiology* 1999;91:127-30.
- Talke P, Caldwell J, Dodsont B, Richardson CA. Desflurane and isoflurane increase lumbar cerebrospinal fluid pressure in normocapnic patients undergoing trans-sphenoidal hypophysectomy. *Anesthesiology* 1996;85:999-1004.
- Chui J, Mariappan R, Mehta J, Manninen P, Venkatraghavan L. Comparison of propofol and volatile agents for maintenance of anesthesia during elective craniotomy procedures: Systematic review and meta-analysis. *Can J Anaesth* 2014;61:347-56.
- Andolfatto G, Willman E. A prospective case series of single-syringe ketamine-propofol (Ketofol) for emergency department procedural sedation and analgesia in adults. *Acad Emerg Med* 2011;18:237-45.