

Extrusion of Anterior Abdominal Wall by a Ventriculoperitoneal Shunt - An Uncommon Complication: Case Report and Literature Review

Abstract

Ventriculoperitoneal shunt (VP-shunt) is a commonly performed procedure for the management of hydrocephalus. Migration of the distal end of VP-shunt is one of the rarest complications. The authors report a case of an 11-year-old boy who presented with a spontaneous extrusion of the distal end of the VP-shunt through an intact abdominal wall. Literature was reviewed regarding the possible causes of such complication and the management approach in similar cases. The suggested phenomenon for this case could be attributed to the continuous hammer effect of the cerebrospinal fluid (CSF) pulsations on the abdominal wall. It is important to assess the future need for long-term CSF diversion, as in this case, the patient did not require reinsertion of a new shunt system because he was shunt independent.

Keywords: Abdominal wall, cerebrospinal fluid, extrusion, shunt independent, ventriculoperitoneal shunt

Introduction

Ventriculoperitoneal shunt (VP-shunt) is one of the most frequently performed procedures for the management of hydrocephalus. However, various complications can be related to proximal and distal ends of the shunt with complications at the distal end occurring more frequently. Distal abdominal complications may include disconnection, obstruction, peritonitis, pseudocyst formation, hydroceles, and catheter migration.^[1] The reported incidence of distal VP-shunt migration is around 10% of all VP-shunt complications.^[2] Spontaneous extrusion of the distal end of the VP-shunt through intact abdominal wall is very rare and only few cases have been reported in the literature.^[1,3-7] According to our institute's records, for more than 36 years' experience, there were not any recorded cases of distal VP-shunt migration through abdominal wall; except for 1 thoracic, 2 anal, 1 vaginal, and 1 pseudocyst.^[8-11] This study reports a case of extrusion of distal VP-shunt through intact abdominal wall and what is special about the case is that the patient remained asymptomatic and shunt independent. The aim of this report is to draw the attention toward the possibility

of such complication and the importance to assess the future need for long-term cerebrospinal fluid (CSF) diversion.

Case Report

An 11-year-old Saudi boy who presented to the hospital with spontaneous extrusion of the distal end of VP-shunt through the intact abdominal wall. The patient was in his usual state of health until 2 weeks prior to his presentation when he developed right abdominal wall patchy redness with localized swelling and drops of fluid coming out of it. The patient was born on the 6th month of gestation. He is a known case of congenital hydrocephalous, cerebral palsy, and seizure since birth. He was managed since then with a VP-shunt, with no history of revision. On examination, the patient was conscious, vitally stable, and had normal body built. The extruded peritoneal end of VP-shunt was on the right side of the abdomen away from the previous surgical incision with inflammation, erythema, tenderness, and discharge around it suggesting infection.

Laboratory findings were within normal levels and the CSF culture was negative. Abdominal computed tomography (CT)

**Amira Aloyani,
Fatimah Al Dandan,
Shaymaa Al-Umran,
Ahmed Ammar**

*Department of Neurosurgery,
King Fahad Hospital of the
University, Imam Abdulrahman
Bin Faisal University, Dammam,
Saudi Arabia*

Address for correspondence:

*Dr. Amira Aloyani,
College of Medicine, Imam
Abdulrahman Bin Faisal
University, Dammam,
Saudi Arabia.
E-mail: amiraaloyani@gmail.com*

Access this article online

Website: www.asianjns.org

DOI: 10.4103/ajns.AJNS_347_19

Quick Response Code:



This is an open access journal, and articles are distributed under the terms of the Creative Commons Attribution-NonCommercial-ShareAlike 4.0 License, which allows others to remix, tweak, and build upon the work non-commercially, as long as appropriate credit is given and the new creations are licensed under the identical terms.

For reprints contact: reprints@medknow.com

How to cite this article: Aloyani A, Al Dandan F, Al-Umran S, Ammar A. Extrusion of anterior abdominal wall by a ventriculoperitoneal shunt - An uncommon complication: Case report and literature review. Asian J Neurosurg 2020;15:425-7.

Submitted: 29-Nov-2019 **Revised:** 05-Feb-2020

Accepted: 08-Apr-2020 **Published:** 29-May-2020

and showed the peritoneal end tube of VP-shunt penetrating along the right side of the abdominal wall [Figure 1c and d]. Head CT was compared to the CT made 2 years ago, showed no significant changes in size of the lateral ventricles with re-demonstration of the left lateral ventricle dilation [Figure 1a].

Broad-spectrum antibiotics were started. Abdominal externalization was done for the patient and kept under observation for few days, no CSF output was there and he was asymptomatic. Hence, we disconnected the proximal end of the VP-shunt distal to the valve in the neck and pulled out the extruded peritoneal end through the abdominal wall. A postoperative head CT [Figure 1b] showed no dilation of the size of the ventricles and the patient was discharged after 1 week. The patient was followed up for more than 4 years with no complications.

Discussion

The exact cause of VP-shunt extrusion cannot yet be determined. However, various hypotheses have been proposed. Akyüz *et al.*^[12] hypothesized that it may occur due to adherence of the distal end of the catheter to a viscera or body wall, a local inflammatory response weakens that area, and the distal end of the catheter will gradually erode through it. Borkar *et al.*^[13] suggested that it could be related to focal wound dehiscence, ischemic necrosis of dermis, poor host immunity, allergic reactions to shunt components or factors related to surgical technique. Other factors that

have been postulated by some authors are; the patient's age, malnutrition, stiff catheter, overlength of the catheter, and use of trocar.^[5,6,12] Additional contributing factors by Chugh *et al.*,^[6] are intestinal peristalsis, intra-abdominal pressure, presence of congenital hernial sac, long-term use of steroids that lead to fragile skin and water hammer effect of the pulsation of the CSF. We suggest that the cause in this case could be attributed to the continuous hammer effect of the CSF pulsations that eroded the abdominal wall, caused local inflammation, and then extruded through the skin.

When spontaneous extrusion of the distal end of a VP-shunt through the abdominal wall is encountered, a course of prophylactic antibiotics should be started immediately and the shunt system must be removed completely. During removal of the extruded shunt system, it is important to avoid pulling the distal end proximally to prevent the spread of infection from the extrusion site. After complete removal of the existing shunt system, a sufficient recovery gap is then allowed so that the CSF culture is negative on two successive occasions. In the meantime, CSF can be drained by external ventricular drain if there are signs of increased intracranial pressure. Simultaneously, the patient is assessed for the requirement of CSF diversion with serial clinical and radiological examinations. If subsequent CSF diversion is required, endoscopic third ventriculostomy or replacement of shunt system on the opposite side can be performed. In addition, strict follow-up should be performed for serial CSF cultures and in order to ensure correct functioning of the new shunt system.^[1,6,14] In this case, the patient was managed similarly, but he did not require a subsequent replacement of the shunt. A possible reason for him to be shunt independent, is that he had the initial shunt before the maturation of the CSF circulation, but then the pathways have opened up and were functioning independently from the placed shunt.^[15]

Conclusion

VP-shunt extrusion through abdominal wall is a rare complication. The exact cause is still not known, but the suggested cause in this case could be attributed to the continuous hammer effect of the CSF pulsations. If such complication is encountered, the basic management should include prophylactic antibiotics, complete removal of VP-shunt, adequate recovery gap so that the CSF culture is negative in two successive occasions, followed by replacement of shunt system on opposite side. However, in this case, the patient did not require reinsertion of a new shunt system as he was shunt independent.

Declaration of patient consent

The authors certify that they have obtained all appropriate patient consent forms. In the form, the patient has given his consent for his images and other clinical information to be reported in the journal. The patient understands that his

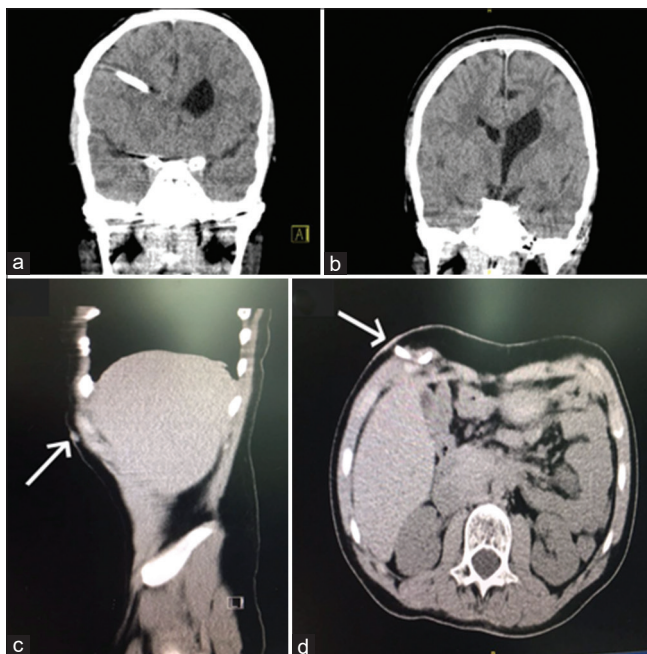


Figure 1: (a) Preoperative coronal head computed tomography showing the proximal end of ventriculoperitoneal-shunt placed in the right lateral ventricle. (b) Postoperative coronal head computed tomography after removing of the ventriculoperitoneal shunt. (c and d) Preoperative sagittal and transversal abdominal computed tomography showing the distal tip of ventriculoperitoneal shunt protruding through the right anterior abdominal wall

name and initial will not be published and due efforts will be made to conceal his identity, but anonymity cannot be guaranteed.

Financial support and sponsorship

Nil.

Conflicts of interest

There are no conflicts of interest.

References

1. Allouh MZ, Al Barbarawi MM, Hiasat MH, Abuzayed BA. Migration of the distal catheter of the ventriculoperitoneal shunt in hydrocephalus patients. *Neurosciences (Riyadh)* 2017;22:298-302.
2. Kanojia R, Sinha SK, Rawat J, Wakhlu A, Kureel S, Tandon R. Unusual ventriculoperitoneal shunt extrusion: Experience with 5 cases and review of the literature. *Pediatr Neurosurg* 2008;44:49-51.
3. Birbilis T, Theodoropoulou E, Matis G. Spontaneous externalization of peritoneal catheter through the abdominal wall in a patient with hydrocephalus: A case report. *Cases J* 2009;2:6898.
4. Panigrahi S, Mishra SS, Das S, Tripathy L, Pattajoshi AS. Spontaneous extrusion of peritoneal catheter of ventriculoperitoneal shunt through the intact abdominal wall: Report of two cases. *J Pediatr Neurosci* 2012;7:228-30.
5. Sridhar K, Sharma BS, Kak VK. Spontaneous extrusion of peritoneal catheter through intact abdominal wall. *Clin Neurol Neurosurg* 1988;90:373-5.
6. Chugh A, Gotecha S, Amle G, Patil A, Punia P, Kotecha M. Abnormal migration and extrusion of abdominal end of ventriculoperitoneal shunt: An experience of eight cases. *J Pediatr Neurosci* 2018;13:317-21.
7. Schulz UG, Labram EK. A healthy lifestyle leading to a rare ventriculo-peritoneal shunt complication. *Br J Neurosurg* 2006;20:173-4.
8. Ammar A, Ibrahim AW, Nasser M, Rashid M. CSF hydro-cele unusual complication of V-P shunt. *Neurosurg Rev* 1991;14:141-3.
9. Ammar A, Nasser M. Intraventricular migration of VP shunts. *Childs Nerv Syst* 1995;18:293-5.
10. Hadzikaric N, Nasser M, Mashani A, Ammar A. CSF hydrothorax – VP shunt complication without displacement of a peritoneal catheter. *Childs Nerv Syst* 2002;18:179-82.
11. Ammar A, Nasser M, Anaizi A, Farag M. Management of VP Shunt Complications, Proceeding of the 13th World Congress of Neurosurgical Surgeons. Marrakesh (Morocco); 2005. p. 507-16.
12. Akyüz M, Uçar T, Göksu E. A thoracic complication of ventriculoperitoneal shunt: Symptomatic hydrothorax from intrathoracic migration of a ventriculoperitoneal shunt catheter. *Br J Neurosurg* 2004;18:171-3.
13. Borkar SA, Satyarthee GD, Khan RN, Sharma BS, Mahapatra AK. Spontaneous extrusion of migrated ventriculoperitoneal shunt catheter through chest wall: A case report. *Turk Neurosurg* 2008;18:95-8.
14. Bansal H, Gupta G, Gupta M, Kaushal R. Unusual ventriculoperitoneal (VP) shunt tube extrusion through anus in a child with dandy walker malformation: A rare case report. *J Clin Diagn Res* 2015;9:PD25-6.
15. Iannelli A, Rea G, Di Rocco C. CSF shunt removal in children with hydrocephalus. *Acta Neurochir (Wien)* 2005;147:503-7.