

A Rare Case of Simultaneous Multifocal Craniospinal Hemangiopericytomas

Abstract

First reported case of simultaneous occurrence of hemangiopericytomas(HCP) at multiple sites of craniospinal axis in a thirty four year male is presented. Patient presented with neck pain for 1 year, and one episode of simple partial seizure involving his left lower limb. He was diagnosed as having HCP in right middle one third parasagittal region, and C4,5 vertebral bodies. Another lesion was present in L5 vertebra, which was radiologically similar to the cervical lesion, but not biopsy proven. High index of suspicion, and low threshold for screening, for coexistence of spinal HCP, in patients harboring cranial HCP's and complaints of back pain.

Keywords: *Craniospinal hemangiopericytomas, multiple hemangiopericytomas, simultaneous multifocal hemangiopericytomas*

Introduction

Intracranial hemangiopericytomas (HPCs) are rare intracranial tumors, accounting for <1% of all intracranial tumors.^[1] HPCs are soft tissue tumors composed of capillary blood vessels with one or more layers of rounded cells showing features of pericytic differentiation. The thick-walled, branching “stag-horn” vessels are easily identified.^[2] Although previously thought to be a subtype of meningiomas, there are now well documented features to differentiate HPC from meningiomas. Intracranial HPC is known to metastasize both to the spinal axis and to extraneural sites as well. Metastasis from extraneural sites to the spine is also well known.^[1-6] All the existing literature suggests metastasis after long-term follow-up. Whether, this represents metastasis or an underlying systemic predisposition to develop such tumors. We report a case of simultaneous occurrence of hypertrophic cranial pachymeningitis (HCP) in cranial, cervical, and lumbar locations.

Case Report

A 34-year-old male presented with neck pain for 1 year, and one episode of simple partial seizure involving his left lower limb. He was a known asthmatic. He did not have any neurological deficits. On investigations,

he was found to be having the right middle one-third parasagittal extra-axial lesion. The lesion was well-defined, isointense on T1, isointense with multiple hypointensities on T2, and well enhancing on gadolinium administration. Cervical magnetic resonance imaging (MRI) showed a lytic lesion involving body and the right side posterior elements of C4, 5 vertebra. MRI also showed a lytic lesion in lumbar (L5) vertebra [Figure 1a and d]. He underwent parasagittal craniotomy and gross total excision of the lesion, with biopsy of the cervical lesion. On histopathological examination, similar picture was present from both the lesions. Sections showed proliferation of spindle cells with blunt vesicular nuclei and variably sized blood vessels embedded within it. No increase in mitosis, necrosis, or pleomorphism was noted. On immunohistochemistry (IHC), glial fibrillary acidic protein, epithelial membrane antigen (EMA), and S 100 were not found to be expressed. CD34 was expressed by the endothelial lining of the blood vessels and the spindle cells [Figure 1e and f]. Ki fraction was 6%. Postoperative he developed the right foot drop, which gradually improved. After the craniotomy, he underwent positron emission tomography-computed tomography Gallium 68 DOTANOC scan, which showed multiple areas of uptake in C4, C5, and L5 vertebrae. Two months after the

**Harnarayan Singh,
Rana Patir,
Anurag Gupta,
Sandeep Vaishya**

*Department of Neurosurgery,
Fortis Memorial Research
Institute, Gurgaon, Haryana,
India*

Address for correspondence:

*Dr. Harnarayan Singh,
House No 211, Mangol Pur
Kalan, New Delhi - 110 085,
India.*

*E-mail: drsingh.harnarayan@
gmail.com*

Access this article online

Website: www.asianjns.org

DOI: 10.4103/ajns.AJNS_356_16

Quick Response Code:



How to cite this article: Singh H, Patir R, Gupta A, Vaishya S. A rare case of simultaneous multifocal craniospinal hemangiopericytomas. *Asian J Neurosurg* 2018;13:885-7.

This is an open access journal, and articles are distributed under the terms of the Creative Commons Attribution-NonCommercial-ShareAlike 4.0 License, which allows others to remix, tweak, and build upon the work non-commercially, as long as appropriate credit is given and the new creations are licensed under the identical terms.

For reprints contact: reprints@medknow.com

cranial surgery, he underwent C4–5 corpectomy, excision of complete tumor from C5 posterior elements, and 360° fusion. He was doing well in follow-up till 9 months' postsurgery when he succumbed to an episode of acute severe asthma.

Discussion

HPC is a rare intracranial tumor accounting for <1% of central nervous system (CNS) neoplasias and <3% of meningeal tumors. These rare mesenchymal tumors are predominantly found in the pelvis, retroperitoneum, and lower extremities, occasionally occurring in the larynx, spleen, or bones in the thorax.^[4]

Initially, its histological resemblance of meningioma caused HPC to be classified as a subtype of this tumor entity (“angioblastic meningioma”).^[4] Meningeal HPCs have different light microscopic, ultrastructural, and IHC features than meningiomas and are not considered variants of meningiomas. Their clinical behavior is more aggressive than that of benign meningiomas, and they have a strong tendency for local recurrence and extracranial metastasis.^[2] Classically, in IHC while HPC shows positivity for CD 34, a meningioma is EMA positive. Focal positivity of EMA in an HPC is also known.^[5]

Non-CNS HPC and solitary fibrous tumor (SFT) are considered by pathologists as two variants of a single tumor entity now subsumed under the entity SFT. Recent detection of frequent NAB2-STAT6 fusions in both, HPC and SFT, has provided additional support for this view. On the other hand, current neuropathological practice still distinguishes between HPC and SFT. This fusion can be rapidly detected by STAT6 IHC which shows a consistent nuclear reallocation.^[7]

Recent literature acknowledges that most lesions formerly known as hemangiopericytoma show no evidence of pericytic differentiation and instead, are fibroblastic in nature, and form a morphological continuum with SFT.^[8]

Meningeal HPCs are found in the vicinity of dural sinuses; the most common location is the parasagittal area.^[5] These tumors are extraaxial; however, one case of HPC presenting as an intraparenchymal mass has been reported.^[6]

These tumors are highly vascular. The cornerstone of treatment in patients with meningeal HPCs is complete resection of the tumor with the underlying dura and bone. Complete excision at the first operation significantly extended the average time before the first recurrence from 43 months to 111 months. The 5-year recurrence-free rate for those patients treated with complete excision was 72.7%, whereas that for those patients treated with incomplete excision was just 20.8%.^[2]

The addition of postoperative radiotherapy is the norm and has shown a significant reduction in the rate of local

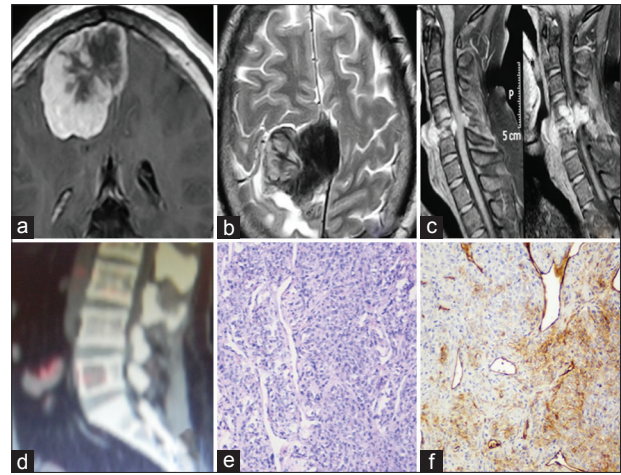


Figure 1: (a and b) Contrast-enhanced and T2 sequence images of the parasagittal lesion in the brain, (c) magnetic resonance image showing destruction of the C5 vertebra, (d) positron emission tomography-computed tomography image showing lytic lesion in L5, (e) high-powered microscopy showing variable sized blood vessels in spindle cells, and (f) CD 34 positivity in endothelial cells

recurrence when compared with surgery alone.^[5] The high vascularity of HPC can be a challenge for the surgeon.^[4]

Intracranial meningeal HPC is known for its high recurrence rate – up to 52.2% – and for its tendency to metastasize in as many as 23.4% of affected patients to extracranial bone (40.9%), liver (36.3%), and lung (36.3%) tissues.^[1]

A few cases of meningeal HPCs metastasizing to the spine have been reported. The mean duration between onset of intracranial HPC and metastasis to the spine is 11 years, and the cervical, thoracic, and lumbar spine are equally involved.^[1]

To the best of our knowledge, this is the second case where simultaneous cranial and spinal HPC have been reported. The first case reported had a meningeal HPC of the posterior fossa and a second lesion in the thoracic spinal epidural space.^[9]

This is the first case where one cranial and two spinal HPCs have been reported concurrently.

The existing literature makes us believe that spinal lesions are metastatic. The spread of tumor cells from brain to different sites of spine is hypothesized to be through the network of venous dural channels. The other likely route of metastasis is through cerebrospinal fluid spread, as is known for benign “multifocal” meningiomas.^[10] The first hypothesis seems more likely as these tumors are known to occur in close proximity to the venous sinuses which provide an easy access for metastasis, and that all the spinal HPC have been extradural lesions in both this and the earlier case report with simultaneous lesions.^[9]

In the present case, the spinal lesion was present concurrently with the cranial lesion. Both the lumbar and cervical lesions showed significant involvement of the

vertebral bodies. Symptomatic period was longer for the cervical lesion than the cranial lesion.

Conclusion

HPCs are rare extra-axial meningeal tumors with a high propensity for local or distant recurrence. High index of suspicion is required to pick up multiple site involvement.

Financial support and sponsorship

Nil.

Conflicts of interest

There are no conflicts of interest.

References

1. Fukuda Y, Watanabe K, Toyama Y, Mikami S, Matsumoto M. Metastasis of intracranial meningeal hemangiopericytoma to thoracic spine 17 years after surgical excision: A case report. *J Orthop Sci* 2015;20:425-9.
2. Cole CD, Schmidt MH. Hemangiopericytomas of the spine: Case report and review of the literature. *Rare Tumors* 2009;1:e43.
3. Chan WS, Zhang J, Khong PL. 18F-FDG-PET-CT imaging findings of recurrent intracranial haemangiopericytoma with distant metastases. *Br J Radiol* 2010;83:e172-4.
4. El Hindy N, Ringelstein A, Forsting M, Sure U, Mueller O. Spinal metastasis from malignant meningeal intracranial hemangiopericytoma: One-staged percutaneous Onyx™ embolization and resection – A technical innovation. *World J Surg Oncol* 2013;11:152.
5. Purandare NC, Dua SG, Rekhi B, Shah S, Sharma AR, Rangarajan V. Metastatic recurrence of an intracranial hemangiopericytoma 8 years after treatment: Report of a case with emphasis on the role of PET/CT in follow-up. *Cancer Imaging* 2010;10:117-20.
6. Shetty PM, Moiyadi AV, Sridhar E. Primary CNS hemangiopericytoma presenting as an intraparenchymal mass – Case report and review of literature. *Clin Neurol Neurosurg* 2010;112:261-4.
7. Schweizer L, Koelsche C, Sahm F, Piro RM, Capper D, Reuss DE, *et al.* Meningeal hemangiopericytoma and solitary fibrous tumors carry the NAB2-STAT6 fusion and can be diagnosed by nuclear expression of STAT6 protein. *Acta Neuropathol* 2013;125:651-8.
8. Fletcher CD. The evolving classification of soft tissue tumours – An update based on the new 2013 WHO classification. *Histopathology* 2014;64:2-11.
9. Radley MG, McDonald JV. Meningeal hemangiopericytoma of the posterior fossa and thoracic spinal epidural space: Case report. *Neurosurgery* 1992;30:446-52.
10. von Deimling A, Kraus JA, Stangl AP, Wellenreuther R, Lenartz D, Schramm J, *et al.* Evidence for subarachnoid spread in the development of multiple meningiomas. *Brain Pathol* 1995;5:11-4.