

Cervical Epidural Abscess due to *Brucella* Treated with Decompression and Instrumentation: A Case Report and Review of Literature

Abstract

Brucella is caused by a Gram-negative bacillus and is a common disease in endemic areas where people are in close contact with animals and dairy products, but brucellar cervical epidural abscess is rare. We describe a rare case of a C5–6 brucellar epidural abscess in a veterinary doctor who was treated with decompression and instrumentation. We also review the cases of cervical brucellar epidural abscess treated with instrumentation in the literature.

Keywords: *Brucella*, spinal brucellosis, spinal epidural abscess, spinal instrumentation

Introduction

Brucellosis usually presents as a fever of unknown origin, and it was initially discovered by David Bruce in 1887 from troopers with Malta fever. It is a Gram-negative bacillus that is oxygen consuming and nonmotile facultative intracellular, having a place in the genus *Brucella*.^[1] People can be infected by *Brucella* by direct contact with meat or tissue of infected animals, consumption of unpasteurized dairy products, or exposure in laboratory.^[2] Vertebral brucellosis is relatively common in patients who have musculoskeletal infection. Early diagnosis and appropriate treatment is needed for better prognosis. The lumbar spine is the most commonly involved region in spinal brucellosis, followed by thoracic spine.^[3-5] The cervical spine is rarely involved in spinal brucellosis.^[6] Spondylodiscitis is the most common form of infection in spinal brucellosis. Epidural abscess formation is rare and is considered a complication of spinal brucellosis.^[6]

Conventionally, spinal epidural abscess was treated with immobilization and antibiotics.^[7] There is now increasing evidence that the unstable spine in the presence of acute infection can be safely stabilized with instrumentation.^[8-10] Only a few cases of cervical spinal epidural abscess caused by *Brucella* and treated

with spinal instrumentation in the acute setting have been reported in the literature. Here, we present a rare case of cervical spinal brucellosis manifesting as C5 vertebral osteomyelitis and epidural abscess and treated with antibiotics and spinal instrumentation. We have also reviewed similar cases reported in the literature.

Case Report

Our patient is a 29-year-old male from Sudan and a veterinary doctor by occupation. He presented to the emergency department of the hospital, complaining of neck and shoulder pain and numbness in the upper limbs for 8 days. He also had cough with fever for 3 days before the presentation. His numbness gradually progressed and developed weakness of the bilateral hand. While under investigation in emergency, the patient started having urinary retention, and hence, a urinary catheter was inserted.

On examination, the patient was febrile and had weakness of the bilateral upper limb and lower limb. The power of his hand grip was 0/5, elbow flexion and extension were 3/5, shoulder was 4/5, and both lower limbs were 4/5. The patient had hyperreflexia and lax anal tone, and the sensory level was at C4. Magnetic resonance imaging (MRI) of the cervical spine was done that showed osteolytic lesions involving C5 vertebral

**Muhammad Mohsin Khan,
Arun Babu R,
Javeed Iqbal,
Surya Narayan Batas,
Ali Raza**

Department of Neurosurgery,
Hamad Medical Corporation,
Doha, Qatar

Address for correspondence:
Dr. Arun Babu R,
Department of Neurosurgery,
Hamad General Hospital,
Po Box- 3050, Doha, Qatar.
E-mail: drarunbabu02@gmail.
com

Access this article online

Website: www.asianjns.org

DOI: 10.4103/ajns.AJNS_358_19

Quick Response Code:



This is an open access journal, and articles are distributed under the terms of the Creative Commons Attribution-NonCommercial-ShareAlike 4.0 License, which allows others to remix, tweak, and build upon the work non-commercially, as long as appropriate credit is given and the new creations are licensed under the identical terms.

For reprints contact: reprints@medknow.com

How to cite this article: Khan MM, Babu RA, Iqbal J, Batas SN, Raza A. Cervical epidural abscess due to *Brucella* treated with decompression and instrumentation: A case report and review of literature. Asian J Neurosurg 2020;15:440-4.

Submitted: 11-Dec-2019 **Revised:** 05-Feb-2020

Accepted: 17-Mar-2020 **Published:** 29-May-2020

body and spondylodiscitis of C4 body and C4–5 disc. There was an epidural abscess extending from C4–C6 level compressing the adjacent spinal cord with associated intramedullary early T2 bright cord edema extending from C3 down to C6 [Figure 1].

As the surgery was done on emergency basis to quickly decompress the spinal cord, initially only anterior cervical fusion was done, posterior spinal fixation was planned later on during follow-up if the patient has progressive kyphosis. The patient underwent emergency C5 corpectomy and evacuation of epidural abscess with interbody titanium cage fusion (ADDplus™, Ulrich Medical, Ulm, Germany). Intraoperatively, there was a frank pus with granulation tissue seen compressing the cord. C5 vertebra was soft in consistency and relatively avascular. The procedure was uneventful with no complication. Postoperatively, the patient's neurological symptoms improved significantly and were completely recovered at 6 weeks.

Pus was sent for bacterial, tuberculosis (TB), and fungal cultures. All cultures were negative; TB polymerase chain reaction was negative. The histopathological examination showed granulation tissue, and the tissue sample was negative for acid-fast bacilli. *Brucella* serology was positive with immunoglobulin G (IgG) and IgM titer of 1:640. On the basis of serology, a diagnosis of spinal brucellosis was made, and he was started on rifampicin and doxycycline for 3 months and gentamycin for 1 week.

He completed 3 months of antibiotics, and his last follow-up was after 9 months of surgery. There were no neurological deficits. He underwent a dynamic C-spine X-ray which showed good alignment of implant, and there was no evidence of instability in the flexion and extension

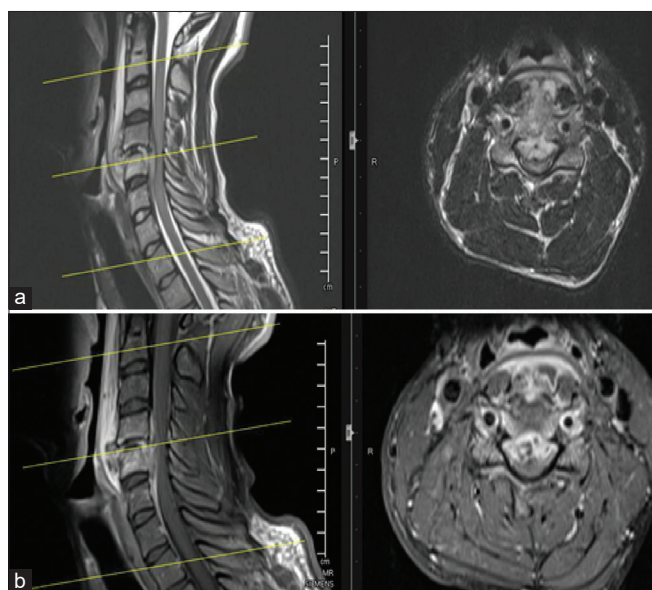


Figure 1: Preoperative magnetic resonance imaging (a) T2. (b) Postcontrast T1 sequences showing the epidural abscess at C4/C5 level with compression of the spinal cord

X-rays. There was kyphosis in the X-ray which is one of the drawbacks of anterior-only approach, but the patient was asymptomatic and there was no neck pain, the patient is planned for follow-up, and in case kyphosis worsens, posterior fixation will be considered. He also underwent follow-up MRI that shows complete resolution of the spinal collection and normal spinal cord [Figure 2].

Discussion

Brucellosis is a relatively common cause of vertebral osteomyelitis in geographic areas of the world in which *Brucella melitensis* is endemic (e.g., the Mediterranean Basin, the Middle East, and Latin America).^[11–14] However, epidural abscess is a very rare manifestation of spinal brucellosis, and the cervical spine is least involved in brucellar spinal epidural abscess.^[3–5] However, patients with cervical and dorsal brucellar spondylitis tend to have proportionally more paravertebral/epidural masses than lumbar spondylitis.^[15]

Ali Ekici *et al.* reported a case of brucellar cervical epidural abscess (CEA) who was treated with anterior cervical discectomy and fusion, and the authors reviewed all the cases of CEA reported in the literature and found only 16 reports of brucellar CEA in the literature.^[16] Instrumentation of the spine in acute infection was traditionally not done because of the fear that implants may flare up the infection. However, there is now increasing evidence that the unstable spine in the presence of acute infection can be safely stabilized with instrumentation.^[8–10] To the best of our knowledge, there are only six cases of cervical brucellar

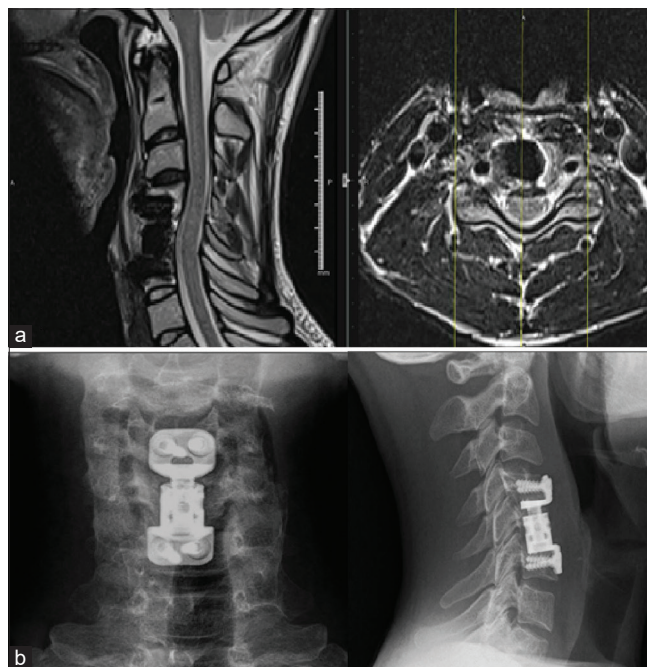


Figure 2: (a) Postoperative magnetic resonance imaging T2 showing complete resolution of the lesion, with no mass effect on the spinal cord. (b) Postoperative X-ray cervical spine anterior-posterior and lateral view showing good alignment of implants

Table 1: Various case reports done on cervical spine, including our case from literature review

Author/published year/country	Number of cases	Age/sex	Risk factors	Location	Diagnosis	Species	Implants used	Antibiotic regimen/duration	Outcome
Ekici et al./2012/ turkey ^[16]	1	63/male	Farmer	C3c4	Brucella melitensis at EMB agar	Brucella melitensis	PEEK cage	PO doxycycline 200 mg/ day and PO rifampicin 600 mg/day for 3 months	Recovery
Ugarriza et al./2005/ Spain ^[17]	1	55/male	Unpasteurized milk ingestion	C56	Antibody titer 160/1<	Brucella melitensis	Corpectomy + anterior plate Implant not mentioned	Doxycycline and rifampicin/8 weeks	Recovery
Ekici et al./2012/ turkey ^[16]	1	63/male	Farmer	C3c4	Brucella melitensis at EMB agar	Brucella melitensis	PEEK cage	PO doxycycline 200 mg/ day and PO rifampicin 600 mg/day for 3 months	Recovery
Bodur et al./2004/ Turkey ^[18]	1	NA	NA	C34	Antibody titer $\geq 1:320$	NA	Details not given	Streptomycin for 40 days, rifampicin and doxycycline for 6 months	Recovery
Ates et al./2001/ Turkey ^[19]	1	42/f	Cheese from raw cow milk	C35	Antibody titer $> 1:320$	NA	Iliac crest graft and anterior plate	Doxycycline and rifampicin for 12 weeks	Recovery
Hantzidis et al ./2009/Greece ^[20]	1	65/male	Farmer	C56	Antibody titer 1:160	NA	Corpectomy, interbody metal cage, and anterior plate	Doxycycline and streptomycin for 12 weeks	Partial recovery
Lee et al./2008/ Korea ^[21]	1	60/male	Farmer	C56	Antibody titer 1:1035	Positive culture. Species not specified	Corpectomy with anterior interbody fusion	Doxycycline	Recovery
Our case	1	29/male	Veterinary doctor	C46	Antibody titer 1:1035	No growth in culture	C5 corpectomy, interbody titanium cage, and titanium anterior plate	Rifampicin and doxycycline	Recover

NA – Not available; EMB – Eosin methylene blue; PO – ‘per os’/ by mouth; PEEK – Polyether ether ketone

epidural abscess treated with drainage and instrumentation in the literature [Table 1].

In a review by Turgut *et al.*, the authors reviewed all the articles of spinal brucellosis published from turkey. Of 452 cases, there were 58% of men and 42% of women. Mode of the infection was through ingestion of raw milk or dairy products in 76% of the cases and through contact of animals in 36% of the cases.^[22] Our patient is a veterinary doctor who denied any history of ingestion of raw milk and had probably acquired infection through contact with animals.

Brucellosis is diagnosed authoritatively by means of confinement of *Brucella* species from blood or tissue samples in laboratory, but isolation of microbes is not

generally possible.^[23] Isolation of *Brucella* from a tissue or biopsy material gives the definitive proof of *Brucella* disease, yet this is accomplished in only 25% of the cases. Most of the cases were diagnosed with increased antibody titers in the blood.^[24]

Surgical evacuation is not routinely needed in spinal brucellosis as most of the cases resolve rapidly with antibiotic treatment. However, the reported rate of surgical intervention varies widely from 0% to 41% in the literature.^[5,6,11,25] Even when surgical intervention was required, most of the reported cases in the literature had undergone drainage of the abscess without instrumentation. In a multicenter, retrospective comparative study of 293 cases of spinal brucellosis, most of the cases were cured by antimicrobial therapy, and the surgery was done only in 32 patients.^[6]

The ideal antibiotic regimen and duration of treatment for *Brucella* spinal abscess is still controversial in the literature. However, every patient with diagnosed *Brucella* infection must undergo antibiotic treatment. The WHO recommends a combination therapy of doxycycline plus streptomycin for at least 12 weeks as the first-line therapy.^[26,27] However, side effects, possible drug–drug interaction, and patient’s clinical and radiological response should be addressed when choosing the antibiotics and its duration. UluKilic *et al.*^[23] analyzed five combination regimens, and they found no difference in outcome between them. The response to treatment can be directed by *Brucella* serology and radiological findings. If treated nonsurgically, antibiotics are given until the abscess is resolved completely in the follow-up MRI scan.

Surgical intervention is indicated if there should arise any compromise in neurological function, spinal stability, and nonresponsiveness to medical treatment.^[24] Choice of approach varies depending on the extent of involvement of the vertebra, preoperative kyphosis, patient’s neurological status, etc. Salzmann *et al.* in their state-wise database study in New York evaluated epidemiology of spinal fusion approaches in 87,405 patients. Anterior approach overall had fewer complications, shorter length of stay, and lower mortalities compared to posterior or circumferential fusion.^[28] Anterior approach is indicated when there is predominant anterior compression. Posterior approach is indicated when there is predominant posterior compression. Circumferential fusion is generally reserved for the cases with extensive levels of involvement or if there is significant preoperative kyphosis. Although our patient had significant preoperative kyphosis, he was initially planned only for anterior approach and fusion in the acute setting. He was planned for posterior instrumentation at a latter period depending on the postoperative clinical status and correction of kyphosis. As such, he underwent C5 corpectomy and C4–6 fusion as there were rapid neurological deterioration and C5 vertebral collapse. He was then treated with rifampicin and doxycycline for 3 months. He responded well to antibiotics and recovered completely.

Follow-up fusion rates are not reported in the any of studies that we reviewed. Our patient had postoperative follow-up dynamic X-ray after 4 weeks which showed no evidence of instability or implant failure. The patient was asymptomatic though there was some postoperative kyphosis.

Conclusion

Spinal brucellosis must be considered while evaluating patients with back or neck pain and fever in endemic areas, and there should be a high index of suspicion in patients in contact with cattle as in our case. The lumbar region is the most common region involved, followed by thoracic and cervical regions. Spondylodiscitis is the most common manifestation. When patients present with

neurological deficits, the presence of epidural abscess must be considered and should be evaluated with MRI spine. Most of the infections get resolved with antibiotics, but surgery is indicated if there is a significant compression of neural elements. Spinal instrumentation can be safely done in the presence of acute infection, and it will not hinder the response to antibiotic treatment.

Financial support and sponsorship

Nil.

Conflicts of interest

There are no conflicts of interest.

References

1. Madkour MM, Sharif HS, Abed MY, Al-Fayez MA. Osteoarticular brucellosis: Results of bone scintigraphy in 140 patients. *AJR Am J Roentgenol* 1988;150:1101-5.
2. Traxler RM, Lehman MW, Bosserman EA, Guerra MA, Smith TL. A literature review of laboratory-acquired brucellosis. *J Clin Microbiol* 2013;51:3055-62.
3. González-Gay MA, García-Porrúa C, Ibañez D, García-País MJ. Osteoarticular complications of brucellosis in an Atlantic area of Spain. *J Rheumatol* 1999;26:141-5.
4. Khateeb MI, Araj GF, Majeed SA, Lulu AR. Brucella arthritis: A study of 96 cases in Kuwait. *Ann Rheum Dis* 1990;49:994-8.
5. Koubaa M, Maaloul I, Marrakchi C, Lahiani D, Hammami B, Mnif Z, *et al.* Spinal brucellosis in South of Tunisia: Review of 32 cases. *Spine J* 2014;14:1538-44.
6. Ulu-Kilic A, Karakas A, Erdem H, Turker T, Inal AS, Ak O, *et al.* Update on treatment options for spinal brucellosis. *Clin Microbiol Infect* 2014;20:O75-82.
7. Darouiche RO. Spinal epidural abscess. *N Engl J Med* 2006;355:2012-20.
8. Todd NV. Letter to the editor concerning Cauda Equina Syndrome treated by surgical decompression: The influence of timing on surgical outcome by A. Qureshi, P. Sell *Eur Spine J* 2007;16:2143-51.
9. Shiban E, Janssen I, da Cunha PR, Rainer J, Stoffel M, Lehmborg J, *et al.* Safety and efficacy of polyetheretherketone (PEEK) cages in combination with posterior pedicle screw fixation in pyogenic spinal infection. *Acta Neurochir (Wien)* 2016;158:1851-7.
10. Talia AJ, Wong ML, Lau HC, Kaye AH. Safety of instrumentation and fusion at the time of surgical debridement for spinal infection. *J Clin Neurosci* 2015;22:1111-6.
11. Colmenero JD, Jiménez-Mejías ME, Sánchez-Lora FJ, Reguera JM, Palomino-Nicás J, Martos F, *et al.* Pyogenic, tuberculous, and brucellar vertebral osteomyelitis: A descriptive and comparative study of 219 cases. *Ann Rheum Dis* 1997;56:709-15.
12. Tekkök IH, Berker M, Özcan OE, Özgen T, Akalin E. Brucellosis of the spine. *Neurosurgery* 1993;33:838-44.
13. Ariza J, Gudiol F, Valverde J, Pallarés R, Fernández-Viladrich P, Rufi G, *et al.* Brucellar spondylitis: A detailed analysis based on current findings. *Rev Infect Dis* 1985;7:656-64.
14. Lifeso RM, Harder E, McCorkell SJ. Spinal brucellosis. *J Bone Joint Surg Br* 1985;67:345-51.
15. Colmenero JD, Cisneros JM, Orjuela DL, Pachón J, Garcia-Portales R, Rodriguez-Sampedro F, *et al.* Clinical

- course and prognosis of *Brucella* spondylitis. *Infection* 1992;20:38-42.
16. Ekici MA, Ozbek Z, Gökoğlu A, Menkü A. Surgical management of cervical spinal epidural abscess caused by *Brucella melitensis*: Report of two cases and review of the literature. *J Korean Neurosurg Soc* 2012;51:383-7.
 17. Ugarriza LF, Porras LF, Lorenzana LM, Rodríguez-Sánchez JA, García-Yagüe LM, Cabezudo JM. *Brucellar* spinal epidural abscesses. Analysis of eleven cases. *Br J Neurosurg* 2005;19:235-40.
 18. Bodur H, Erbay A, Colpan A, Akinci E. *Brucellar* spondylitis. *Rheumatol Int* 2004;24:221-6.
 19. Ates O, Cayli SR, Koçak A, Kutlu R, Onal RE, Tekiner A. Spinal epidural abscess caused by brucellosis. Two case reports. *Neurol Med Chir (Tokyo)* 2005;45:66-70.
 20. Hantzidis P, Papadopoulos A, Kalabakos C, Boursinos L, Dimitriou CG. *Brucella* cervical spondylitis complicated by spinal cord compression: A case report. *Cases J* 2009;2:6698.
 21. Lee HJ, Hur JW, Lee JW, Lee SR. *Brucellar* spondylitis. *J Korean Neurosurg Soc* 2008;44:277-9.
 22. Turgut M, Turgut AT, Koşar U. Spinal brucellosis: Turkish experience based on 452 cases published during the last century. *Acta Neurochir (Wien)* 2006;148:1033-44.
 23. Kadanali A, Ozden K, Altoparlak U, Erturk A, Parlak M. Bacteremic and nonbacteremic brucellosis: Clinical and laboratory observations. *Infection* 2009;37:67-9.
 24. Seidel G, Pardo CA, Newman-Toker D, Olivi A, Eberhart CG. Neurobrucellosis presenting as leukoencephalopathy: The role of cytotoxic T lymphocytes. *Arch Pathol Lab Med* 2003;127:e374-7.
 25. Solera J, Lozano E, Martínez-Alfaro E, Espinosa A, Castillejos ML, Abad L. *Brucellar* spondylitis: Review of 35 cases and literature survey. *Clin Infect Dis* 1999;29:1440-9.
 26. Mandell GL, Bennett J, Dolin R, editors. Principles and Practice of Infectious Diseases. *Brucella* species. Vol. 2. Philadelphia: Churchill Livingstone; 2005.
 27. Yousefi-Nooraie R, Mortaz-Hejri S, Mehrani M, Sadeghipour P. Antibiotics for treating human brucellosis. *Cochrane Database Syst Rev* 2012;10:CD007179.
 28. Salzmänn SN, Derman PB, Lampe LP, Kueper J, Pan TJ, Yang J, *et al.* Cervical spinal fusion: 16-year trends in epidemiology, indications, and in-hospital outcomes by surgical approach. *World Neurosurg* 2018;113:e280-e295.