

Rapid Spontaneous Resolution of the Acute Subdural Hematoma: Case Series and Review of Literature

Abstract

Background: Traumatic acute subdural hematoma (ASDH) is an oft encountered entity in neurosurgery. While resolution of such thick SDHs usually takes time, certain cases of rapid spontaneous resolution have also been reported. This article attempts to review the pathophysiology, clinical and radiological features of such cases, as well as provide an insight into decision making for their management. **Methods:** Electronic literature search was done to look for similar cases of spontaneous rapid resolution of ASDH. Five of authors cases have been described. Their clinical and radiological features along with those of cases from literature search were tabulated and analyzed. **Results:** A total of 44 relevant cases were included for analyses. Of these, 39 cases were from 33 articles found in existing literature and 5 cases were from author's collection. The M:F ratio was 25:19 with a mean age was 41.84(SD-4.094) years. Twenty -six patients showed "Rapid" neurological improvement (≤ 24 hours) while "gradual" neurological improvement (>24 hours) occurred in 10 patients. The mean hematoma resolution time on CT scan was 13.78 hours (SD 16.46) ranging from 1- 72 hours. Twenty-nine patients showed redistribution of hematoma, most commonly to tentorium and falx cerebelli. CT scan findings were classified into 5 types as per the nature of hypodensity around hematoma. The geometric mean time to resolution of hematoma was least for type 2 (7.27 hours) and type 1(7.52 hours) patients. **Conclusion:** Selected patients of ASDH with rapid neurological improvement and specific CT findings may show spontaneous resolution of ASDH. Multicentric studies with larger study population may provide better insight into the nature and outcomes of such entities.

Keywords: Acute subdural hematoma, pathophysiology, rapid resolution, traumatic brain injury

**Lavlesh Rathore,
Debabrata Sahana,
Sanjeev Kumar,
Rajiv K. Sahu,
Amit K. Jain,
Manish Tawari,
Pravin R. Borde**

Department of Neurosurgery,
DKS-Postgraduate Institute and
Research Center, DKS Bhawan,
Raipur, Chhattisgarh, India

Introduction

A neurosurgeon routinely comes across acute subdural hematoma (SDH) caused by traumatic brain injury. The decision about conservative or surgical management is based on the neurological status of the patient, size of hematoma, and midline shift. Even with definitive surgical indications certain cases of "rapid" resolution of acute SDH have been reported, but, mostly in the form of case reports.^[1-4] The process of chronic healing of the traumatized brain has been described in many studies, but the physiology of such "rapid" healing of brain from such life-threatening injuries is still not completely understood, probably because of the rarity of such occurrences. In our study, we have discussed cases of rapid resolution of the acute SDH in five of our patients, along with literature review of the possible pathophysiological causes of such phenomena.

Case 1

A 23-year-old male with a history of road traffic accident (RTA) 6 h back was referred to our hospital with a Glasgow Coma Scale (GCS) of E3M6V5 at admission. On examination, both pupils were equal and reacting to light. The patient was initially admitted in another hospital, where the examining physician had found his GCS to be E2M5V4 with anisocoria. The computed tomography (CT scan) of head done at the previous hospital, 1 h after injury, showed 1.2 centimeters (cm) thick right sided acute subdural hematoma (ASDH) with 1 cm of midline shift to the left side [Figure 1a-c]. The repeat scan at our hospital (6 h after head injury) showed marked resolution of right side ASDH with reduction of midline shift to 0.3 cm [Figure 1d-f]. The patient was advised conservative treatment and close observation in our neuro-intensive

Address for correspondence:

Dr. Lavlesh Rathore,
Flat No. 404, B Block, Natura
Apartment, Daldal Seoni,
Mowa, Raipur - 492 001,
Chhattisgarh, India.
E-mail: lavleshathore06@
gmail.com

Access this article online

Website: www.asianjns.org

DOI: 10.4103/ajns.AJNS_380_20

Quick Response Code:



This is an open access journal, and articles are distributed under the terms of the Creative Commons Attribution-NonCommercial-ShareAlike 4.0 License, which allows others to remix, tweak, and build upon the work non-commercially, as long as appropriate credit is given and the new creations are licensed under the identical terms.

For reprints contact: WKHLRPMedknow_reprints@wolterskluwer.com

How to cite this article: Rathore L, Sahana D, Kumar S, Sahu RK, Jain AK, Tawari M, *et al.* Rapid spontaneous resolution of the acute subdural hematoma: Case series and review of literature. Asian J Neurosurg 2021;16:33-43.

Submitted: 05-Aug-2020 **Accepted:** 15-Oct-2020
Published: 23-Feb-2021

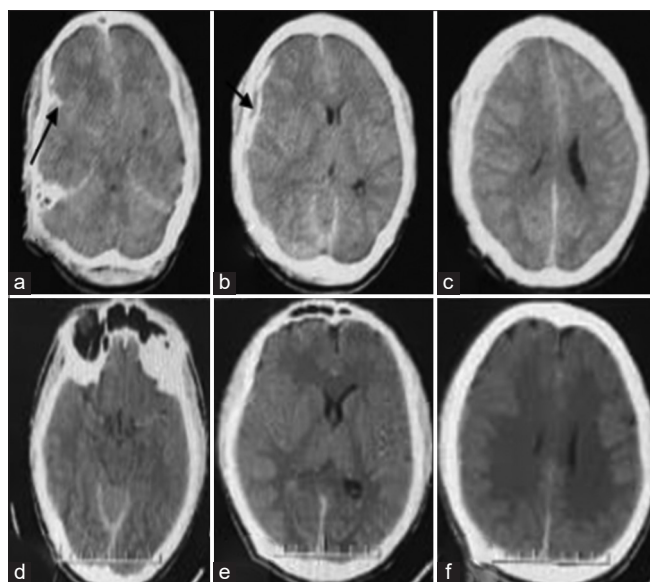


Figure 1: (a) (1 h) Basal cuts computed tomography scan showing SAH in distal right sylvian fissure (black arrow). (b) (1 h) Mid axial computed tomography scan showing thin layer of hypodensity (black arrow) seen between the inner table of bone and acute subdural hematoma with a midline shift. (c) (1 h) High parietal axial computed tomography scan showing thick acute subdural hematoma present at the high frontoparietal region with obliterated cortical sulci. (d) (6 h) basal axial cuts of computed tomography scan showed opened basal cistern with a resolution of the right sylvian SAH. (e and f) (6 h) Mid and high parietal axial computed tomography scan showing marked resolution of acute subdural hematoma seen, with reduction of midline shift

care unit. The patient showed clinical improvement with conservative treatment and was discharged on 10th day following trauma.

Case 2

A 55-year-old male, brought to our hospital with history of RTA 24 h back at one of the remote areas of our state. The patient's relative gave history of unconsciousness since trauma but noticed some improvement in the form of intermittent eye-opening and hand movements by the time they reached our hospital. On admission, the patient's GCS was E2M5V2 and both pupils were equal and reacting to light. The 1st CT scan of the head was done at the time of admission, i.e., 24 h after trauma and showed ASDH of 1 cm thickness in the right frontotemporoparietal region, bilateral frontal contusion, subarachnoid hemorrhage, and evolving infarct in right posterior cerebral artery territory with midline shift of 0.82 cm to the left [Figure 2a,d]. The patient was managed conservatively with antiepileptics and anti-edema measures. The patient's clinical condition improved gradually and CT scan on day 3 and day 6 of trauma showed marked resolution of ASDH with reduction in midline shift to 0.2 cm [Figure 2b,c,e and f]. There was redistribution of clot to tentorium cerebelli and falx cerebelli, as seen on coronal and sagittal cuts of CT scan on day 2, 3 and 6 [Figure 2g-l]. The patient was discharged on day 10 with GCS of E4M6V5.

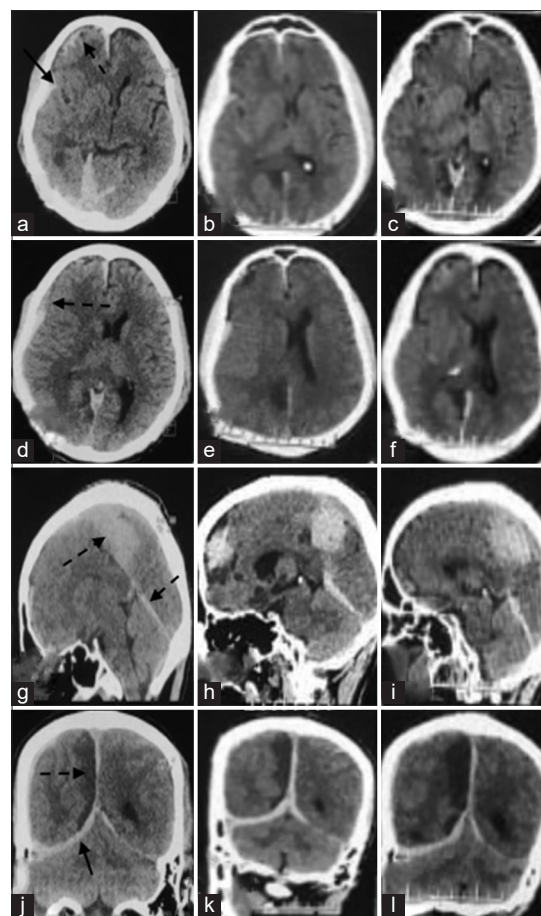


Figure 2: (a-c) Computed tomography scan of basal cuts showing SAH in the right sylvian fissure (arrow) and right frontal sulci (broken arrow) (a), gradually resolve in day 3 (b) and day 6 (c). (d-f) computed tomography scan of mid-axial section of the brain acute subdural hematoma with mixed density clot with hypodensity around it (broken arrow) (d), which disappeared in day 3 (e) and Day 6 (f). (g-i) Sagittal image showing redistribution of clot acute subdural hematoma along the tentorium and falx on (broken arrow) day 2 (g), day 3 (h) and day 6 computed tomography (i). (j-l) The coronal image showing day 2 (j), 3 (k) and 6 (l) showed almost similar size right PCA infarct (broken arrow)

Case 3

A 30-year-old female, brought to our hospital with history of RTA due to fall from two-wheeler 12 h back, had a GCS of E3M6V5 with equal and reacting pupils at the time of admission. The patient was initially treated at another hospital where her GCS recorded was E3M5V4 and CT scan done approximately 6 h after trauma showed 9.6 mm mixed density subdural hematoma (SDH) in left fronto-temporo-parietal region, midline shift of 6 mm, obliterated basal cistern with left basifrontal contusion [Figure 3a-c]. CT scan repeated at our hospital, 13 h after trauma showed complete resolution of the mixed density part of SDH with minimal residual hyperdense SDH, no midline shift with open quadrigeminal and ambient cisterns [Figure 3d-f]. As there was documented improvement in the clinical and radiological status of the patient, she was managed conservatively with anti-edema and antiepileptic drugs. Repeat CT scan was done on day 5 of admission

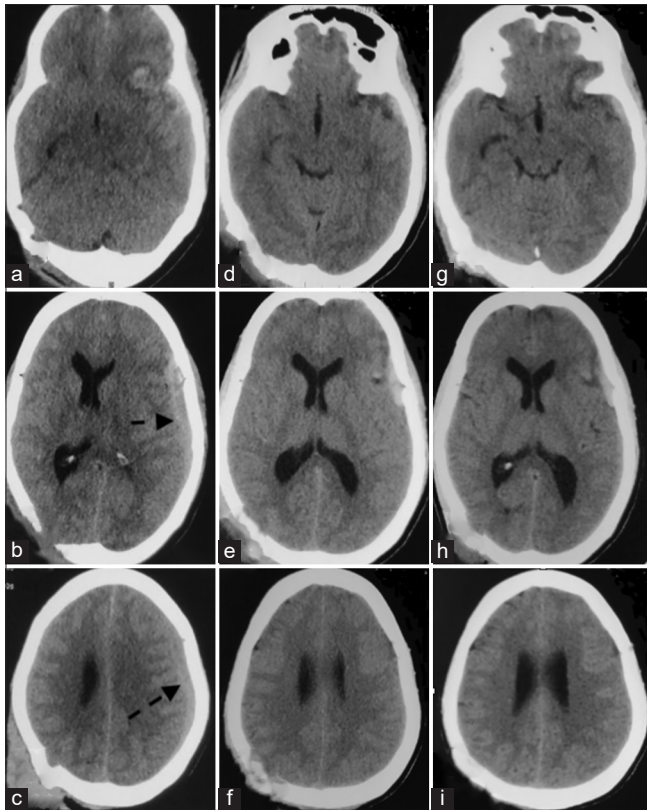


Figure 3: (6 h after trauma) (a) Basal axial image showing obliterated basal cistern with left basifrontal contusion. (b and c) (6 h after trauma)-9.6 mm mixed density SDH in left fronto-temporo-parietal region (marked with broken arrow) with midline shift of 6 mm (d-f) (13 h after trauma)-computed tomography scan showing complete resolution of mixed density part of clot with small residual hyperdense part of clot with open basal cistern and no midline shift. (g-i) (day 5 after trauma) Computed tomography scan showing resolving left basifrontal contusion and residual left frontal SDH

which showed small residual left frontal SDH and left basifrontal contusion with no mass effect and midline shift [Figure 3g-i]. The patient was discharge on day 6 with GCS E4M6V5 and no neurological deficit.

Case 4

A 70-year-old female was referred to our hospital with history of self-fall from stairs 6 h back. On admission GCS was E3M6V5 and both the pupils were equal and reacting to light. Patient was initially treated outside; where CT scan brain was done. The recorded GCS was E2M5V4 and CT scan brain, which was done 1 h after trauma, showed 10 mm thick ASDH in the right front-temporo-parietal region with midline shift of 7.3 mm to the left side. Mixed density clot was present in frontal portion of SDH [Figure 4a-c].

In view of neurological improvement of the patient, CT scan was repeated at our hospital, 7 h after trauma, which showed marked resolution of ASDH to 5 mm thickness and midline shift of 3 mm. The frontal portion of clot was thin and completely hypodense and mixed density areas of clot had migrated to parietal region [Figure 4d-f]. Some redistribution of clot was also seen on tentorium, in the

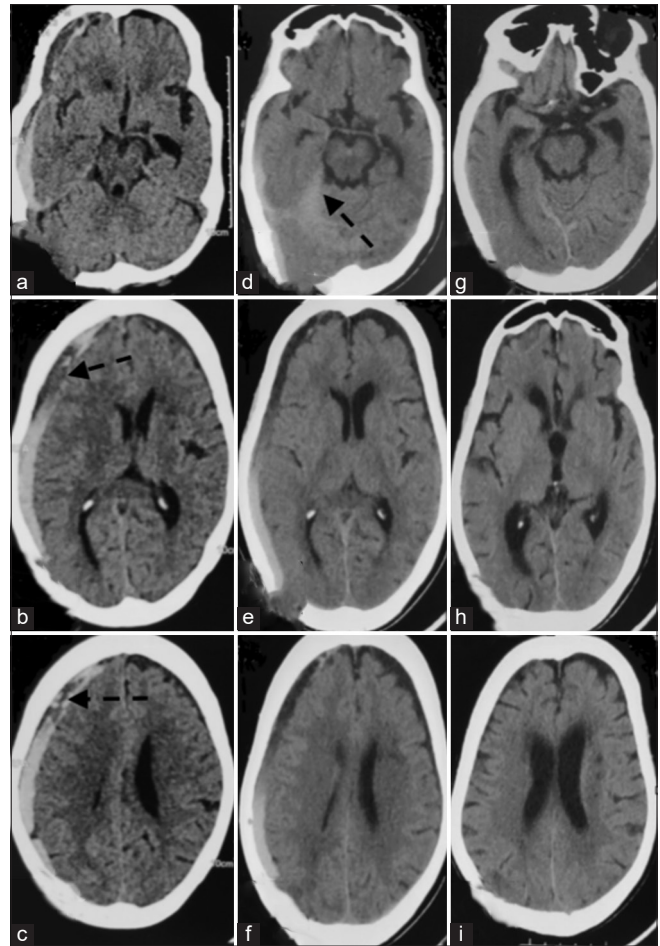


Figure 4: (a-c) (1 h after trauma) computed tomography scan showing 10 mm thick acute subdural hematoma with 7.3 mm midline shift and mixed density clot in frontal portion of subdural hematoma (marked with broken arrow). (d-f) (7 h after trauma) computed tomography scan showing marked resolution of acute subdural hematoma to 5 mm thickness and midline shift of 3 mm. Some redistribution of clot seen along the tentorium cerebelli (marked with broken arrow) (d). (g-i) (4th day of trauma) computed tomography scan showing complete resolution of clot with no midline shift

basal cuts of axial CT scan [Figure 4d]. The patient was managed conservatively on antiepileptic and antiedema drugs. Clinically, the patient improved to GCS of E4M6V5 within the next 24 h. The next CT scan was done on day 4 of trauma, which showed complete resolution of clot with no midline shift [Figure 4g-i]. The patient was discharged on the same day.

Case 5

A 28-year-old male patient was admitted to our hospital with a history of RTA 5 h back with GCS of E2M5V4 without anisocoria. The patient was initially managed at another hospital where GCS was found to be E1M3V2 with anisocoria. CT scan, done outside, 1 h after trauma, showed a 9 mm thick right-side front-temporo-parietal SDH with midline shift of 12 mm to left side. Linear fracture was present in frontal bone with subgaleal hematoma of 6 cm × 2 cm size [Figure 5a and b]. In view of some neurological improvement, CT scan was repeated at our

hospital, 5 h after trauma. It showed significant reduction of the right ASDH to 5 mm thickness, reduction of midline shift to 2 mm and enlargement of subgaleal hematoma size (9 cm × 2 cm size) [Figure 5c]. The patient was managed

conservatively and was discharge on day 10 with no neurological deficit.

A summary of clinical and radiological features of all five patients is shown in Table 1.

Methods

Retrospective data were collected from author's pictorial library of cases with rapid spontaneous resolution of ASDH and their case files were retrieved from Medical Records Department. Their clinical and radiological data were tabulated and analyzed. A detail literature search was done electronically in PubMed, MEDSCAPE, Cochrane, Google scholar and ResearchGate archives using the keywords - "acute subdural hematoma," "spontaneous," "resolution" OR "resolving." The search was further refined by adding keywords "rapid" OR "ultrafast." All retrieved publication titles, abstracts and full texts were reviewed independently by 2 of the investigators. Manual searching of reference list of every selected article was done to complete the search.

Inclusion criteria for article selection were: (1) ASDH due to trauma, (2) radiological improvement or resolution of ASDH within 72 h since trauma, (3) article with images of at least 1st CT scan showing ASDH and another subsequent scan showing resolution of ASDH (4) conservative treatment (5) articles published in English language.

Articles with nontraumatic causes of ASDH, articles without relevant images or clinical summary, and cases with interval scan beyond 72 h of first scan were excluded.

A descriptive analysis of clinical and radiological features was done. For standardization, documented neurological improvement within 24 h was called rapid improvement and that beyond 24 h was called gradual improvement. CT scans found in articles included in study as well as those from the author's pictorial library were analyzed independently by 2 neurosurgeons, with 10 years and 6 years' experience. Based on the relative density of hematoma and the position of hypodensity

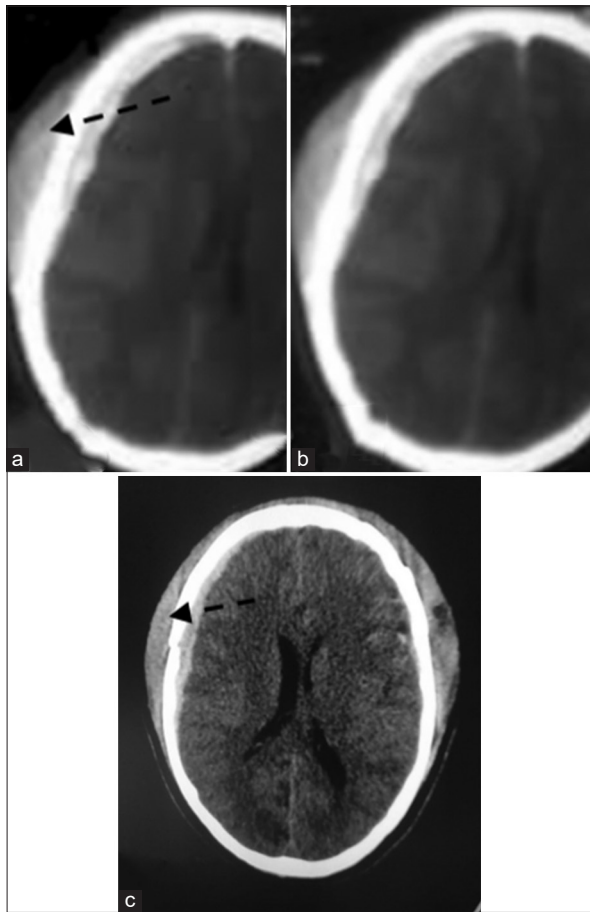


Figure 5: (a and b) (1 h after trauma) computed tomography scan showing thick right acute subdural hematoma, 12 mm of midline shift with subgaleal hematoma (marked with broken arrow). (c) (5 h after trauma) computed tomography scan showing significant reduction of acute subdural hematoma and midline shift with enlargement of subgaleal hematoma (marked with broken arrow)

Table 1: Summary of clinical and radiological findings of authors cases

Case number	Age (years)/sex	Initial GCS*	Interval GCS [§]	Interval time of clot reduction [†]	Thickness of acute SDH (1 st CT scan)	Brain oedema	CT scan finding	Redistribution site
1	23/male	E2M5V4	E3M6V5	6 h	1.2 cm	+	Hypo between inner table of bone and clot	Tentorium and posterior falx
2	55/male	NA (unconscious as per history)	E2M5V2	Day 3	1 cm	+	Hypo between inner table and clot+mixed density clot+hypo between clot and brain surface	Tentorium, posterior falx
3	30/female	E3M5V4	E3M6V5	13 h	9.6 mm	+	Mixed density clot	-
4	70/female	E2M5V4	E3M6V5	6 h	1 cm	-	Mixed density clot in frontal portion SDH	Tentorium
5	28/male	E1M3V2	E2M5V4	5 h	9 mm	+	Hypo between inner table of bone and clot	Extracranial

*Initial GCS – GCS mentioned in referral card or as per history; [§]Interval GCS – GCS recorded in our hospital on admission; [†]Interval time of clot reduction – Time since trauma. GCS – Glasgow coma scale; NA – Not available; SDH – Subdural hematoma; CT – Computed tomography

Table 2: Proposed classification of rapid resolution of acute subdural hematoma according to 1st computed tomography scan findings

Type	CT finding in 1 st scan	Number of patients	Clot resolution time in hours
1	Hypodensity between inner table of bone and clot	11	Mean - 8.72 SD - 5.47 Range - 3–24 Geometric mean* - 7.52
2	Mixed density clot	14	Mean - 10.57 SD - 9.085 Range - 2–34.6 Geometric mean - 7.27
3 (combined 1 and 2)	Hypodensity between inner table of bone and clot+Mixed density clot	9	Mean - 12.6 SD - 13.77 Range - 3–48 Geometric mean - 8.2
4	Hypodensity between inner table of bone and clot+Mixed density clot+hypodensity between clot and brain surface	5	Mean - 33 SD - 32.01 Range - 1–72 Geometric mean - 13.86
5	Mixed density clot+hypodensity between clot and brain surface	3	Mean - 24 SD - 17.28 Range - 8–48 Geometric mean - 18.31

*Geometric mean - mean which indicate central tendency. SD – Standard deviation; CT – Computed tomography

within it, they were divided into five types [Table 2 and Figure 6].

Results

Literature search showed 43 articles - 7 in PubMed, 13 in Google Scholar, 0 in Cochrane and 23 in ResearchGate databases. After excluding duplications, articles in other languages or articles which did not meet our criteria, 33 articles remained. Total 39 cases were found which sufficed our inclusion criteria from 33 articles. The total number of cases thus included in analysis were 44, i.e., 39 cases from 33 articles and 5 of author's cases [Table 3].

There were 25 males and 19 females. The mean age was 41.84 (standard deviation [SD]-4.094) years with a range of 1–92 years. The initial GCS score was mentioned in 37 patients only. In 7 cases data for initial GCS score was either not documented or mentioned using different scoring system. According to initial GCS score, severe head injury (GCS 3–8) was present in 17 patients, moderate head injury (GCS 9–13) in 13 patients and mild head injury (GCS 14–15) in seven patients. Rapid neurological improvement (≤ 24 h) was present in 26 patients, while gradual neurological improvement (>24 h) occurred in 10 patients. In six

patients, neurological status remained unchanged. There was one death and information regarding neurological status was not mentioned in one patient. The mean time of reduction or resolution of hematoma on CT scan was 13.78 h (SD 16.46) ranging from 1 to 72 h. Brain edema on CT scan was present in 32 patients. Redistribution of hematoma was present in 29 patients. Tentorium and falx cerebelli were the most common locations for redistribution of hematoma. There were three patients with extracranial redistribution of hematoma to subgaleal space and two patients with redistribution of hematoma to spinal subdural space.

Based on nature of hypodensity around hematoma, it was possible to classify the 1st CT findings of 42 cases into five different categories as mentioned in Table 2. Two cases with only extracranial redistribution of hematoma were excluded from above categorization. The geometric mean time to resolution of hematoma was least for type two patients (7.27), closely followed by type 1 (7.52). It was maximum for type five patients (18.31).

Discussion

ASDH commonly occurs due to tear in the subdural portion of bridging veins. The cause of tear in the subdural portion

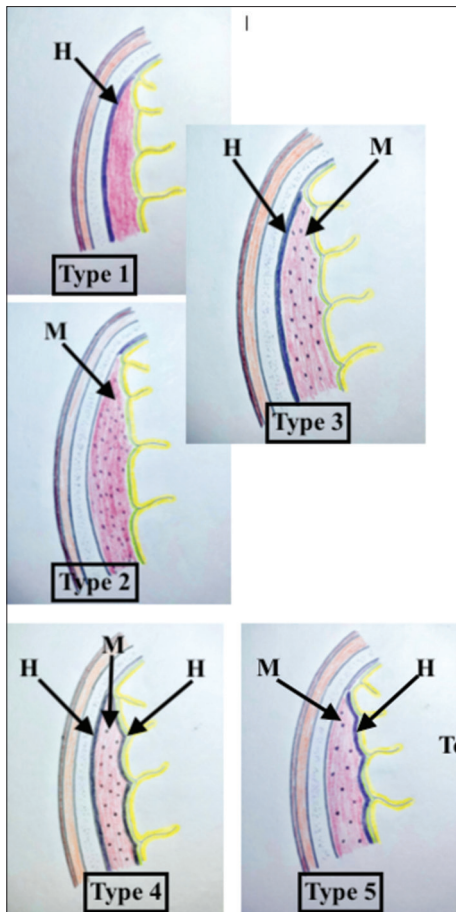


Figure 6: Schematic diagram showing proposed classification of 1st computed tomography scan of patient with rapid spontaneous resolution of acute subdural hematoma (H-Hypodensity, M-Mixed intensity hematoma)

of the bridging vein as compared to subarachnoid segment is due to extremely varied wall thickness (10–600 μm), loosely woven collagen fibers and lack of reinforcement of arachnoid trabecular cells; and only few and scattered “Dural border cells” in the subdural segment.^[38] There is a possible positive feedback mechanism which leads to an initial increase in the size of hematoma. Bleeding in potential subdural space causes a rise in intracranial pressure (ICP) which results in elevation of cerebral venous pressure (CVP). The raised CVP acts as an outflow resistor for the terminal portion of the bridging vein and thus leads to further bleeding in the hematoma cavity.^[39] The bleeding stops when either clot forms in the periphery of the hematoma cavity or SDH cavity pressure equalizes with CVP. Spontaneous resolution of ASDH usually occurs gradually. “Rapid” resolution of ASDH is still not very well understood. Two popular hypothesis of redistribution of clot and cerebrospinal fluid (CSF) dilution and clearance has been proposed in the past. The following section describes each of these hypothesis in details.

Redistribution of hematoma

Polman *et al.* proposed that rapid resolution of ASDH occurred from the redistribution of blood clot rather than its complete

disappearance.^[1] The redistribution hypothesis was supported by other researchers as well. Kuroiwa *et al.* observed that the size of the ASDH decreased as the size of interhemispheric SDH increased. They suggested that cerebral swelling and increased ICP resulted in compression of the hematoma leading to its redistribution.^[40] Kundra and Kundra reported rapid extracranial redistribution of ASDH to the subgaleal space through diastatic coronal fracture in a 3-year-old child.^[9] Kato *et al.* confirmed redistribution of ASDH in middle cranial fossa in two of their cases with magnetic resonance imaging and concluded that resolution results from redistribution rather than complete disappearance of the hematoma.^[8] Few cases of redistribution of ASDH in spinal subdural space has also been mentioned in the literature.^[14,41]

We believe that the role of pulsatility of brain as well as its compliance is par importance in rapid spontaneous resolution of ASDH. In a high compliance system even with large increase in volume, only a small change in the pressure occurs, conversely, a low compliance system shows significant increase in the pressure even with minimal increase in volume. Marmarou *et al.* described the exponential pressure-volume relationship in their experimental study. They suggest that an increase in ICP will lead to a decrease in brain compliance.^[42] The decrease in brain compliance associated with an increase in the ICP leads to increase pressure pulsatility.^[43] The increase in pressure pulsatility in the brain leads to redistribution of the hematoma. For the redistribution phenomenon to occur the brain should remain pulsatile [Figure 7].

Cerebrospinal fluid dilution of hematoma

Nagao *et al.* postulated that rapid resolution of the ASDH could be due to arachnoid tear, which results in CSF dilution of the hematoma, followed by retrograde flow into the subarachnoid space.^[5] Suzuki *et al.* found the presence of a thin layer of hypodensity between the inner table and SDH on CT scan, in his case report of rapid resolution of SDH. They postulated that for the rapid resolution of ASDH, the brain compensatory mechanisms needed to maintain normal CSF outflow and blood outflow via the venous system as well as brain elasticity.^[44]

Rennels *et al.* in his animal study, demonstrated rapid distribution of even heavy molecules like tracer proteins through paravascular pathways in the brain.^[45] Therefore, it was suggested that the hematoma dissolved in CSF, rapidly gets cleared out and distributed via paravascular pathway. Orešković and Klarica have suggested bidirectional flow of CSF which produces a to-and-fro displacement of CSF in systolic and diastolic phases.^[46] Hence, dissolved hematoma in CSF can move back to subarachnoid space and follow the rapid paravascular pathway for clearance by venous system.

Associated Factors

Some cases of rapid resolution of ASDH, associated with brain atrophy due to age,^[25] acquired immune-deficiency syndrome^[47]

Table 3: Patients data from literature review of spontaneous rapid resolution of acute subdural hematoma

Author	Age/sex	Neurological status [†]	Rapid improvement [^]	Interval time [*]	Thickness of SDH ^s	Brain oedema	CT finding [#]	Redistribution site	Addition factor
Nagao <i>et al.</i> ^[5]	3 years/ female	GCS9	+	7 h	NA	-	Hypo between inner table and clot		
Matsuyama <i>et al.</i> ^[4]	18 years	GCS9	+	3 h	15 mm	-	Hypo between inner table and clot		
Tsui <i>et al.</i> ^[6]	56 years/ male	GCS15	+	6 h	>10 mm	+	Hypo between inner table and clot	Tentorium and postfalx	
Yadav YR ^[11]	45 years/ male	E1M4V1	+	7 h	Thick	+	Hypo between inner table and clot	Tentorium and postfalx	
Kato <i>et al.</i> ^[8]	79 years/ female	JCS1	Stable	12 h	Thick	-	Hypo between inner table and clot	Middle cranial fossa	
Kato <i>et al.</i> ^[8]	41 years/ female	JCS10	+	12 h	Thick	+	Hypo between inner table and clot	Middle cranial fossa	
Kundra and Kundra ^[9]	3 years	Drowsy	+	6 h	Thick	+	-	Extracranial space	
Coşar <i>et al.</i> ^[10]	8 months	GCS15	Stable	9 h	10 mm	+	Hypo between inner table and clot+mixed density of clot+hypo between clot and brain surface		
Lee CH ^[13]	61 years/ male	E1M2V1	+	14 h	25.9 mm	+	Hypo between inner table and clot+frontal mixed density clot	Tentorium	
Watanabe <i>et al.</i> ^[12]	88 years/ female	E1M2V1	Gradual [#] - In 3 days	3 days	Very thick	+	hypo between inner table and clot+Mixed density clot+hypo between clot and brain	Tentorium, falx and middle cranial fossa	
Park JY ^[22]	7 years/ female	GCS5	+	16 h	Thick	+	Mixed density in whole clot except thin inner hyperdense layer	Tentorium, falx and SAS	
Balik <i>et al.</i> ^[14]	66 years/ male	GCS6	Deterioration - death	16 h	Thick	-	Hypo between clot and brain surface+mixed density on clot	Tentorium, falx, cerebral convexity, SAS and spinal subdural space	
Shin <i>et al.</i> ^[2]	40 years/ female	GCS6	+	1 h	10 mm	-	Hypo between inner table and clot+mixed density of parietal clot+hypo between clot and brain surface	SAS	
Ghadarjani ^[15]	17 years/ male	GCS13	Gradual - Next day	6 h	10 mm	+	-	Extracranial space	
Ghadarjani ^[15]	17/ female	GCS12	Gradual- Progressive alert	6 h	10 mm	+	Hypo between inner table and clot	Tentorium	
Gan <i>et al.</i> ^[16]	1 year/ male	E2M4V2	Gradual - 2 days	24 h	9 mm	+	Mixed density clot	Posterior falx	
Gelsomino <i>et al.</i> ^[17]	25 years/ male	GCS15	Stable	4.5 h	Thick	+	Hypo between inner table and clot+mixed density clot		

Contd...

Table 3: Contd...

Author	Age/sex	Neurological status [†]	Rapid improvement [^]	Interval time [*]	Thickness of SDH ^s	Brain oedema	CT finding [#]	Redistribution site	Addition factor
Koppen <i>et al.</i> ^[18]	4 years/ female	GCS 15	Gradual - awake next day	4 h	9 mm	—	Hypo between inner table and clot+mixed density clot	SAS-basal cistern, 4 th ventricle	
Bae <i>et al.</i> ^[19]	67 years/ male	GCS5	Gradual - recovery in days	24 h	25 mm	+	Hypo between inner table and clot	Tentorium, posterior falx	Brain atrophy, coagulopathy
Lee and Song ^[20]	74 years/ male	E1M4V2	+	8 h	20 mm	+	Hypo between inner table and clot		Coagulopathy
Perwez <i>et al.</i> ^[21]	15 months/ female	GCS15	Stable	12 h	Thick	—	Mixed density clot	Tentorium	C/L type 2 middle cranial fossa arachnoid cyst
Mirzai H ^[23]	19 years/ male	GCS9	+	2 h	Thick	+	Mixed density clot	Tentorium, SAS	
Liu B ^[26]	48 years/ female	GCS7	+	22 h	Thick	+	Hypo between inner table and clot+mixed density clot	Tentorium, spinal subdural space	
Chaudhary <i>et al.</i> ^[24]	73 years/ male	Alert than deteriorated in 5 h	Gradual - in next 2 days	48 h	Thick	-	Hypo between clot and brain surface+mixed density clot	Tentorium, falx	Coagulopathy
Sato <i>et al.</i> ^[25]	92 years/ female	GCS9	+	8 h	Thick	-	Hypo between clot and brain surface+mixed density clot		Brain atrophy
Sato <i>et al.</i> ^[25]	88 years/ male	GCS10	+	3 h	Thick	-	Between inner table and clot+mixed density clot	Tentorium, falx	Brain atrophy
Choi <i>et al.</i> ^[30]	67 years/ male	NA	+	3 h	10 mm	-	Mixed density of clot		
Edwards <i>et al.</i> ^[27]	49 years/ female	GCS3	+	10 h	Very thick	+	Mixed density of clot	Tentorium, falx	Brain atrophy
Maqsood ^[28]	52 years/ male	GCS13	Stable	48 h	7 mm	+	Hypo between inner table and clot+mixed density clot		
Kapsalaki <i>et al.</i> ^[29]	29 years/ male	GCS8	Gradual	13 h	1.8 cm	+	Mixed density of clot	Tentorium, opposite sylvian fissure, cerebral convexity	coagulopathy
Berker M ^[31]	57 years/ male	GCS7	+	2.5 h	Thick	+	Mixed density of clot	Tentorium	
Byrappa V ^[34]	40 years/ female	E1M3V1	+	7 h	9 mm	+	Hypo between inner table and clot+mixed density clot		
Byrappa V ^[34]	55 years/ female	E1M5V2	+	6 h	8 mm	+	Hypo between inner table and clot+mixed density clot		
Ozay <i>et al.</i> ^[32]	55 years/ female	NA	NA	6 h	Thick	+	Mixed density of clot		Dandy walker malformation
Öğrenci <i>et al.</i> ^[33]	3 years/ male	GCS15	Stable	4 h	11.2 mm	+	Mixed density of clot		

Contd...

Table 3: Contd...

Author	Age/sex	Neurological status [†]	Rapid improvement [^]	Interval time [*]	Thickness of SDH ^{\$}	Brain oedema	CT finding [#]	Redistribution site	Addition factor
Dang RS ^[36]	47 years/ male	E1M2V1	+	11 h	22 mm	+	hypo between inner table and clot+mixed density clot+hypo between clot and brain	Tentorium, falx	
Hostettler et al. ^[35]	88 years/ male	GCS14	Gradual	34.6 h	18 mm	+	Mixed density of clot		
Wen L ^[37]	22 years/ male	GCS11	+	5 h	Thick	+	Hypo between inner table and clot+mixed density clot		
Inamasu J ^[7]	16 years/ male	E1M6V2	+	2 h	Thick	+	Mixed density of clot	Tentorium	

[†]Neurological status - 1st recorded neurological status after trauma; [^]Rapid neurological improvement - improvement in neurological status in <24 h; [#]Gradual - improvement in neurological status after 24 h; ^{*}Interval time - time for radiological findings of clot reduction or resolution since trauma; ^{\$}Thickness of SDH - thickness of subdural hematoma on patient 1st CT scan head; [#]CT scan finding - findings of 1st CT scan head after trauma. GCS – Glasgow coma scale; JCS – Japan coma scale; SAS – Subarachnoid space; SDH – Subdural hematoma; CT – Computed tomography; NA – Not available

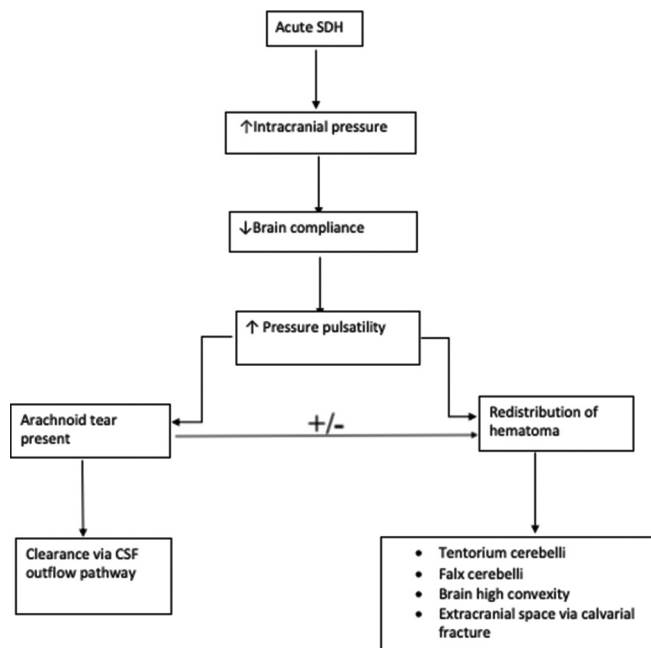


Figure 7: Flow chart showing the proposed mechanism of rapid spontaneous resolution of acute subdural hematoma

and chronic alcoholism^[6,27] has been mentioned in literature. The presence of abundant space in subdural and subarachnoid compartments may help wash out the hematoma in these cases.

Some cases of rapid resolution of clot have been found associated with coagulopathy.^[20,24] The possible explanation could be, coagulopathy prevents formation of well-organized clot, making it susceptible to redistribution by CSF dilution.^[24] The possible association of middle cranial fossa arachnoid cyst and posterior fossa cyst in dandy walker malformation

has been mentioned in the literature. Arachnoid tear in cyst wall with mixing of CSF and hematoma has been postulated for the resolution of ASDH in such cases.^[21,32]

Predicting Spontaneous Rapid Resolution of Acute Subdural Hematoma

Identifying which patients would undergo rapid spontaneous resolution of ASDH is the challenging part, as many of them seem to be candidates for craniotomy on initial evaluation. There are no guidelines to help make such decisions. Literature search was done to identify clinical and radiological parameters which may help predict chances of rapid resolution of ASDH [Table 2]. Analysis of our result suggest that, most of the cases which resolved spontaneously initially presented with moderate ($n=13$) to severe head injury ($n=17$). Rapid neurological improvement within 24 h of injury has been documented in 27 out of total 44 cases.^[2,4-9,11,13,20,22,23,25-27,30,31,34,36,37] While waiting for surgery, a rapid neurological improvement, in patients with ASDH, may hint at the possibility of spontaneous resolution or reduction of hematoma. We suggest a repeat radiological workup in such cases (CT scan head) before proceeding for surgery.

In some cases, neurological condition remained stable^[8,10,17,21,28,33] or improved gradually^[12,15,16,18,19,24,29,35] The death of one such patient reported by Balik et al. had been correlated with hemodynamic instability and sudden cardiac arrest due to sympathetic hyperactivity. On postmortem examination of the above case, redistribution of hematoma in spinal subdural space and ischemic changes in the pons was detected.^[14]

The CT scan finding of “hypodensity on clot,” suggesting mixing of CSF, was found to be an important predictor for

rapid resolution of ASDH. The thin layer of hypodensity on CT scan between inner table of bone and the ASDH may not be the only predictor of rapid resolution. Since resolution of ASDH is a dynamic process, CT scan done at different stages of dissolution of hematoma may show different patterns of hypodensity of the clot, and these may further help in identification of patients with the possibility of rapid resolution of ASDH. Analysis of Table 3 shows that maximum patients had Type 2, Type 1, and Type 3 patterns of hematoma on CT scan. These were the groups having the least time for the resolution of hematoma [Table 2].

Conclusion

Rapid spontaneous resolution of the ASDH though rare is not totally impossible and should be considered while dealing with ASDH cases. We believe that the resolution of ASDH depends upon decreased brain compliance, which is associated with increased pressure pulsatility that leads to redistribution of the hematoma. The rapidly improving neurological condition of patient with initial CT scan showing CSF mixing changes of hematoma may point toward the possibility of spontaneous resolution. It is not possible to comment whether all patients with changes of CSF-hematoma mixing on CT scan would resolved rapidly. We suggest a larger sample size and multicenter study to further analyze the correlation between the changes in clot with CSF mixing and their final outcome.

Declaration of patient consent

The authors certify that they have obtained all appropriate patient consent forms. In the form, the legal guardian has given his consent for images and other clinical information to be reported in the journal. The guardian understands that names and initials will not be published and due efforts will be made to conceal identity, but anonymity cannot be guaranteed.

Financial support and sponsorship

Nil.

Conflicts of interest

There are no conflicts of interest.

References

- Polman CH, Gijssbers CJ, Heimans JJ, Ponssen H, Valk J. Rapid spontaneous resolution of an acute subdural hematoma. *Neurosurgery* 1986;19:446-8.
- Shin DW, Choi CY, Lee CH. Spontaneously rapid resolution of acute subdural hemorrhage with severe midline shift. *J Korean Neurosurg Soc* 2013;54:431-3.
- Makiyama Y. Acute subdural hematomas spontaneously disappearing within 3 days following closed head injury; report of two cases. *Nihon Univ J Med* 1985;27:123-7.
- Matsuyama T, Shimomura T, Okumura Y, Sakaki T. Rapid resolution of symptomatic acute subdural hematoma: Case report. *Surg Neurol* 1997;48:193-6.
- Nagao T, Aoki N, Mizutani H, Kitamura K. Acute subdural hematoma with rapid resolution in infancy: Case report. *Neurosurgery* 1986;19:465-7.
- Tsui EY, Fai Ma K, Cheung YK, Chan JH, Yuen MK. Rapid spontaneous resolution and redistribution of acute subdural hematoma in a patient with chronic alcoholism: A case report. *Eur J Radiol* 2000;36:53-7.
- Inamasu J, Nakamura Y, Saito R, Kuroshima Y, Mayanagi K, Ohba S, et al. Rapid resolution of traumatic acute subdural hematoma by redistribution. *Am J Emerg Med* 2002;20:376-7.
- Kato N, Tsunoda T, Matsumura A, Yanaka K, Nose T. Rapid spontaneous resolution of acute subdural hematoma occurs by redistribution--two case reports. *Neurol Med Chir (Tokyo)* 2001;41:140-3.
- Kundra SN, Kundra R. Extracranial redistribution causing rapid spontaneous resolution of acute subdural hematoma. *Neurol India* 2005;53:124.
- Coşar M, Eser O, Aslan A, Ela Y. Rapid resolution of acute subdural hematoma and effects on the size of existent subdural hygroma: A case report. *Turk Neurosurg* 2007;17:224-7.
- Yadav YR, Agarwal M, Namdev H, Parihar V. Rapid resolution of acute subdural hematoma: A case report and review of literature. *Indian J Neurotrauma* 2011;8:45-7.
- Watanabe A, Omata T, Kinouchi H. Rapid reduction of acute subdural hematoma and redistribution of hematoma: Case report. *Neurol Med Chir (Tokyo)* 2010;50:924-7.
- Lee CH, Kang DH, Hwang SH, Park IS, Jung JM, Han JW. Spontaneous rapid reduction of a large acute subdural hematoma. *J Korean Med Sci* 2009;24:1224-6.
- Balik V, Kolembus P, Svajdler M, Sulla I, Vaverka M, Hrabalek L. A case report of rapid spontaneous redistribution of acute supratentorial subdural hematoma to the entire spinal subdural space presenting as a pourfour du petit syndrome and review of the literature. *Clin Neurol Neurosurg* 2013;115:849-52.
- Ghadarjani S. Rapid spontaneous resolution of acute cranial subdural hematomas – Two case reports. *J Neurol Stroke* 2014;1:21-3.
- Gan Q, Zhao H, Zhang H, You C. Rapid spontaneously resolving acute subdural hematoma. *J Craniofac Surg* 2017;28:e287-9.
- Gelsomino M, Awad AJ, Gerndt C, Nguyen HS, Doan N, Mueller W. Mechanism for the rapid spontaneous resolution of an acute subdural hematoma and transformation into a subdural hygroma. *World Neurosurg* 2018;115:282-4.
- Koppen H, Arkink E, Nordbeck A, Sie L, van der Gaag N. Swift spontaneous regression of a pediatric traumatic acute subdural hematoma. *Case Rep Neurol* 2019;11:351-6.
- Bae HJ, Lee SB, Yoo DS, Huh PW, Lee TG, Cho KS. Rapid spontaneous resolution of acute subdural hematoma in a patient with liver cirrhosis. *Korean J Neurotrauma* 2014;10:134-6.
- Lee IK, Song SW. Spontaneous resolution of acute subdural hematoma with a good clinical outcome: A case report. *Nerve* 2019;5:83-6.
- Perwez A, Azab W, Singh S. Rapid spontaneous resolution of acute subdural hematoma associated with a contralateral arachnoid cyst: A case report and review of the literature. *Int J Students Res* 2013;3:26.
- Park JY, Moon KS, Lee JK, Jeung KW. Rapid resolution of acute subdural hematoma in child with severe head injury: A case report. *J Med Case Rep* 2013;7:67.
- Mirzai H, Yaldiz C, Eminoglu M, Orguc S. Ultra fast resolution of acute post-traumatic subdural haematoma. *Neurol Neurosurg Psychiatry* 2005;76:1738.
- Chaudhary N, Krivosheya D, Small E, Hsia C, Ng W, Leung A. Rapid resolution of acute subdural hematoma in a coagulopathic

- patient. *Can J Neurol Sci* 2013;40:599-600.
25. Sato M, Nakano M, Sasanuma J, Asari J, Watanabe K. Rapid resolution of traumatic acute subdural haematoma in the elderly. *Br J Neurosurg* 2005;19:58-61.
26. Liu B, Zhuang Z, Luo J. Fluctuation of intra-parenchymal cerebral pressure may drive the rapid spontaneous resolution of acute subdural hematoma. *Med Hypotheses* 2013;81:159-62.
27. Edwards RJ, Britz GW, Critchley GR. Spontaneous resolution of an acute subdural haematoma. *Br J Neurosurg* 2002;16:609-10.
28. Maqsood A. Rapidly resolving acute subdural hematoma. A case report. *Indian J Neurotrauma* 2008;05:115-6.
29. Kapsalaki EZ, Machinis TG, Robinson JS, Newman B, Grigorian AA, Fountas KN. Spontaneous resolution of acute cranial subdural hematomas. *Clin Neurol Neurosurg* 2007;109:287-91.
30. Choi SH, Park CW, Kim JM, Kim EY, Yoo CJ, Kim YB, *et al.* Rapid spontaneous resolution of traumatic acute subdural hematoma sung. *J Kor Neurotraumatol Soc* 2011;7:47-9.
31. Berker M, Gulsen S, Ozcan OE. Ultra rapid spontaneous resolution of acute posttraumatic subdural hematomas in patient with temporal linear fracture. *Acta Neurochir (Wien)* 2003;145:715-7.
32. Ozay R, Fesli R, Balkan S, Turkoglu E, Sekerci Z. Rapid resolution of an acute subdural hematoma in Dandy Walker syndrome. *Neurol India* 2015;63:286.
33. Öğrenci A, Ekşi MŞ, Koban O, Karakuş M. Spontaneous rapid resolution of acute subdural hematoma in children. *Childs Nerv Syst* 2015;31:2239-43.
34. Byrappa V, Bansal S, Kamath S, Kadarapura GK. Spontaneous resolution of traumatic acute subdural hematoma with good clinical outcome: A report of two cases. *Indian J Neurotrauma* 2014;11:146-9.
35. Hostettler IC, Murahari S, Raza MH, Kontojannis V, Tsang K, Kareem H, *et al.* Case report on the spontaneous resolution of a traumatic intracranial acute subdural haematoma: Evaluation of the guidelines. *Acta Neurochir (Wien)* 2018;160:1311-4.
36. Dang RS, Panwar DS, Sharma R, Singh SC. Spontaneous resolution of acute subdural hematoma. *J Evol Med Dent Sci* 2011;2:8841-4.
37. Wen L, Liu WG, Ma L, Zhan RY, Li G, Yang XF. Spontaneous rapid resolution of acute subdural hematoma after head trauma: Is it truly rare? Case report and relevant review of the literature. *Ir J Med Sci* 2009;178:367-71.
38. Yamashita T, Friede RL. Why do bridging veins rupture into the virtual subdural space? *J Neurol Neurosurg Psychiatry* 1984;47:121-7.
39. Miller JD, Nader R. Acute subdural hematoma from bridging vein rupture: A potential mechanism for growth: Clinical article. *J Neurosurg* 2014;120:1378-84.
40. Kuroiwa T, Tanabe H, Takatsuka H, Arai M, Sakai N, Nagasawa S, *et al.* Rapid spontaneous resolution of acute extradural and subdural hematomas. *Case Rep J Neurosurg* 1993;78:126-8.
41. Wong ST, Yuen MK, Fok KF, Yuen SC, Yam KY, Fong D. Redistribution of hematoma to spinal subdural space as a mechanism for the rapid spontaneous resolution of posttraumatic intracranial acute subdural hematoma: Case report. *Surg Neurol* 2009;71:99-102.
42. Marmarou A, Shulman K, Rosende RM. A nonlinear analysis of the cerebrospinal fluid system and intracranial pressure dynamics. *J Neurosurg* 1978;48:332-44.
43. Wagshtul ME, Eide PK, Madsen JR. The pulsating brain: A review of experimental and clinical studies of intracranial pulsatility. *Fluids Barriers CNS* 2011;8:5.
44. Suzuki Y, Kawamata T, Matsumoto H, Kunii N, Matsumoto K. A resolving sign of acute subdural hematoma: From report of two cases. *No Shinkei Geka* 1998;26:1025-29.
45. Rennels ML, Gregory TF, Blaumanis OR, Fujimoto K, Grady PA. Evidence for a 'paravascular' fluid circulation in the mammalian central nervous system, provided by the rapid distribution of tracer protein throughout the brain from the subarachnoid space. *Brain Res* 1985;326:47-63.
46. Orešković D, Klarica M. A new look at cerebrospinal fluid movement. *Fluids Barriers CNS* 2014;11:16.
47. Cohen JE, Eger K, Montero A, Israel Z. Rapid spontaneous resolution of acute subdural hematoma and HIV related cerebral atrophy: Case report. *Surg Neurol* 1998;50:241-4.