

Pituitary Hormonal Status after Endoscopic Endonasal Transphenoidal Removal of Nonfunctioning Pituitary Adenoma: 5 years' Experience in a Single Center

Abstract

Background: This study focuses on hormonal disorder and medical complications postoperative endoscopic endonasal transphenoidal approach of nonfunctioning adenoma at Prasat Neurological Institute, Bangkok, between January 2013 and December 2017. **Methods and Material:** Baseline characteristics, clinical complications, and hormonal status data were collected from the patients' medical records and analyzed using the descriptive statistics. **Results:** There were four surgeons who operated 126 cases, 17 of them were reoperation. The average age of the patients was 49 years old. The average length of stay was 13 days, and average operating time was 134 min. Visual field defect was the most common presenting symptom. Almost all the tumors were classified as pituitary macroadenoma which invaded one or two sellar walls. Total or near total tumor removal was the most extend of resection. There were 61 cases developed early diabetes insipidus (DI), but only 12 cases continue to long-term DI. Seven cases were meningitis. Three cases were death. Out of 83 patients who had preoperative intact hypothalamic-pituitary-adrenal (HPA) axis and hypothalamic pituitary thyroidal (HPT) axis, 2 and 3 of them developed postoperative impair HPA and HPT axis in that order. In addition, among 45 patients who had preoperative impair HPA and HPT axis, 6 of them achieved postoperative endocrinological normalization. **Conclusion:** In preoperative intact pituitary hormone patients, the total or near total tumor removal of non functioning pituitary adenoma may have hypopituitarism during early postoperative period but gradually returned to normal during 4-6 month postoperative period.

Keywords: Endoscopic endonasal transphenoidal tumor removal surgery, nonfunctioning pituitary adenoma, pituitary hormonal status, Prasat Neurological Institute

Introduction

In recent years, several new surgical techniques that can help patients recover faster with fewer complications^[1-3] have been developed on account of technological advancement in medical devices and equipment. Endoscopic transphenoidal surgery is one of those less invasive surgical techniques that allow patients with sellar tumors, especially the pituitary tumor, to recover and return to their daily life faster when comparing to conventional open craniotomy surgery.^[4-6] Nevertheless, the endoscopic transphenoidal surgery to remove pituitary tumor may result in the higher chance of complications from pituitary hormone disorders because of pituitary gland and stalk manipulation during the operation.

Prasat Neurological Institute (PNI) is one of the leading institutions in the treatment and research of neurological and neurosurgical diseases in Thailand. Each year, PNI has more than one thousand neurosurgery cases operated, and there are about 25–30 cases of endoscopic endonasal transphenoidal pituitary tumor removal cases among them. This study focuses on the incidence and factors affecting postoperative medical complications and pituitary hormone disorder after endoscopic endonasal transphenoidal removal of nonfunctioning pituitary tumors. The results from this study will help staff to beware postoperative medical complications in future. They will also be served as a benchmark dataset for the similar operations in other hospitals.

This is an open access journal, and articles are distributed under the terms of the Creative Commons Attribution-NonCommercial-ShareAlike 4.0 License, which allows others to remix, tweak, and build upon the work non-commercially, as long as appropriate credit is given and the new creations are licensed under the identical terms.

For reprints contact: WKHLRPMedknow_reprints@wolterskluwer.com

How to cite this article: Keandoungchun P, Tirakotai W, Phinthusophon A, Wattanasen Y, Masayaanon P, Takathaweephon S. Pituitary hormonal status after endoscopic endonasal transphenoidal removal of nonfunctioning pituitary adenoma: 5 years' experience in a single center. *Asian J Neurosurg* 2021;16:62-6.

Submitted: 06-Aug-2020 **Revised:** 22-Sep-2020
Accepted: 15-Oct-2020 **Published:** 20-Mar-2021

Punjai
Keandoungchun,
Wuttipong
Tirakotai¹,
Ampai
Phinthusophon,
Yodkhan
Wattanasen²,
Patcharapim
Masayaanon³,
Sudasawan
Takathaweephon⁴

Departments of
Internal Medicine,
¹Neurosurgery, ²Radiology,
³Neuro-Ophthalmology and
⁴Department of Nursing, Prasat
Neurological Institute, Bangkok,
Thailand

Address for correspondence:
Dr. Punjai Keandoungchun,
Department of Internal
Medicine, Prasat Neurological
Institute, 312 Rajavithi Rd.,
Rachathewi District, Bangkok
10400, Thailand.
E-mail: keandoungchunp@
outlook.com

Access this article online

Website: www.asianjns.org

DOI: 10.4103/ajns.AJNS_386_20

Quick Response Code:



Subjects and Methods

This study is retrospective, observational study conducted by collecting clinical data from 126 operations in 109 patients older than 15 years. They underwent endoscopic endonasal transphenoidal approach (EETA) for the tumor removal at PNI between January 2013 and December 2017, and the pathological reports indicate that all of them had nonfunctioning pituitary adenoma. The baseline characteristics data collected from the medical records of the patients included patient's sex, age, length of stay, operating time, responsible surgeon, presenting symptoms, extend of resection, clinical complications, and hormonal status. All postoperative patients were admitted into the neurosurgery unit and clinically monitored and followed up by neurosurgeons, internal medicine staffs, and endocrinologists.

The present study was approved by the Institutional Review Board of PNI, Thailand (Ref. no. 60040). Patients' biochemical and hormonal levels were determined using the Chemiluminescent Microparticle Immunoassay (CMIA) technique. All laboratory analyses were performed by Abbott Laboratories Ltd., USA, using the Architect i1000SR immunoassay analyser.

In this study, we applied the following definitions. Hyponatremia is a state where sodium concentration in patient's serum is < 135 mmol/L.^[7] Hypocortisolism a state where basal morning cortisol hormone of the patient is < 3.0 ug/dL.^[8] Hypothyroid is a state where one or any combination of the following can be observed: (i) free triiodothyronine (FT3) in patient's serum is < 2.39 pg/ml, (ii) free thyroxine (FT4) in patient's serum is < 0.54 ng/ml, and (iii) thyroid-stimulating hormone of patient is < 0.34 uIU/ml.

Results

Baseline characteristics of the cases operated between January 2013 and December 2017 are shown in Table 1. The total number of operations was 126. Sixty-two cases (49.21%) were male. There were 17 cases (13.49%) reoperated due to recurrent of the tumors. The average age of the patients was 49 years old. Two major age groups were 31–40 years old (30 cases; 23.81%) and 51–60 years old (30 cases; 23.81%). The average length of stay in hospital was 13 days, and average operating time was 134 min (2 h and 14 min).

There were four surgeons, namely surgeon A, B, C, and D, who operated 4, 62, 47, and 13 cases, respectively. Surgeon A had the highest working year, surgeon B had the 2nd highest, surgeon C had the 3rd highest, and surgeon D had the lowest one.

Visual field defect was the most common presenting symptom found in the patients (95 cases; 75.40%). Visual acuity decrease was the second one (82 cases; 65.08%). The

Table 1: Baseline characteristics, early postoperative complication, and outcome

Baseline characteristics and postoperative complication	n (%)
Operation	126 (100)
Re-operation NFPA	17 (13.49)
Male	62 (49.21)
Average age (years)	49
Age group	
15–20	0 (0.00)
21–30	11 (8.73)
31–40	30 (23.81)
41–50	25 (19.84)
51–60	30 (23.81)
61–70	21 (16.67)
>71	9 (7.14)
Average length of stay (days)	13
Average operative time (hh: mm)	2:14
Surgeon	
A	4 (3.17)
B	62 (49.21)
C	47 (37.30)
D	13 (10.32)
Presenting symptoms	
Incidental finding	12 (9.52)
Visual acuity decrease	82 (65.08)
Visual field deficit	95 (75.40)
Headache	60 (47.62)
Hypopituitarism	45 (35.71)
Pituitary apoplexy	35 (27.78)
Galactorrhea	4 (3.17)
Tumor size	
Macroadenoma	120 (95.24)
Sellar wall invasion	
Tumor confine in sellar	7 (5.56)
1 wall invasion	51 (40.48)
2 walls invasion	41 (32.54)
3 walls invasion	14 (11.11)
4 walls invasion	3 (2.38)
Extend of resection	
Total or near total removal	101 (80.16)
Subtotal removal	19 (15.08)
Partial removal	6 (4.76)
Postoperative medical complication,	
Early postoperative meningitis	7 (5.56)
Early postoperative DI	61 (48.41)
4–6 months postoperative DI	12 (9.52)
Discharge status	
Death	3 (2.38)

DI was defined clinically by urine output > 250 cc/hour for two consecutive hours or more concurrent with urine-specific gravity < 1.005 and requiring at least one dose of desmopressin. DI – Diabetes insipidus; NFPA – Non-functioning pituitary adenomas

other presenting symptoms commonly found among the cases were headache (60 cases; 47.62%), hypopituitarism

(45 cases; 35.71%), pituitary apoplexy (35 cases; 27.78%), incidental finding (12 cases; 9.52%), and galactorrhoea (4 cases; 3.17%)

Almost all the tumors were classified as pituitary macroadenoma (120 cases; 95.24%). Most of them invaded only one sellar wall (51 cases; 40.48%) or two sellar walls (41 cases; 32.54%). Total or near total tumor removal was the most extend of resection in our cases (101 cases; 80.16%), followed by subtotal tumor removal (19 cases; 15.08%) and partial tumor removal (6 cases; 4.76%).

Postoperative medical complications data are also shown in Table 1. The early diabetes insipidus (DI) whose requiring at least one dose of desmopressin developed in 61 cases (48.41%). However, only 12 cases (9.52%) continued to show long-term DI during 4–6 months' postoperative period. Seven cases (5.56%) were meningitis. There were three dead cases (2.38%). The causes of the death were intracranial arterial injury (2 cases) and drug resistant ventriculitis with septic shock (1 case).

The pre- and post-operative sodium and hormonal statuses are shown in Figure 1. Nineteen cases (15.08%) of hyponatremia were observed during the preoperative period. Number of hyponatremia cases increased to 35 cases (27.78%) during early postoperative period, before significantly decreased to five cases (3.97%) during 1–3 month-postoperative period, and to two cases (1.59%) during 4–9 month-postoperative period. Number of hypocortisolism cases monotonically decreased from 20 cases (15.87%) during preoperative period, to 11 cases (8.73%) during early postoperative period, 10 cases (7.94%) during 1–3 months postoperative period, and 7 cases (5.56%) during 4–9 month-postoperative period. Similar to the hypocortisolism, the number of central hypothyroid cases monotonically decreased from 30 cases (23.81%) during the preoperative period, to 29 cases (23.02%), 15 cases (11.90%), and 11 cases (8.73%) during early, 1–3 months, and 4–9 month-postoperative period, respectively.

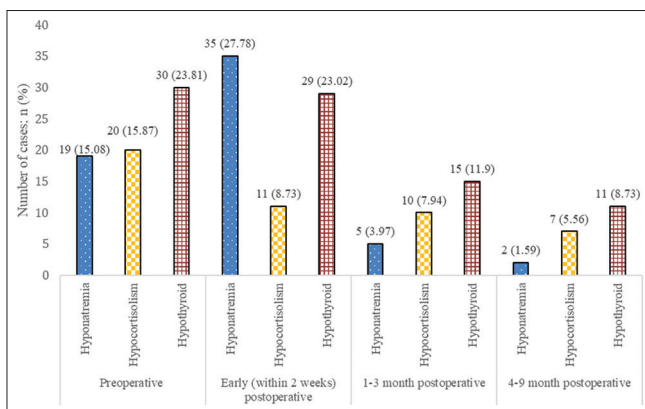


Figure 1: Pre- and postoperative sodium and hormonal status. Hyponatremia; serum sodium <135 mmol/l, hypocortisolism; basal morning cortisol <3.0 ug/dL, hypothyroid; FT3 <2.39 pg/ml and/or FT4 <0.54 ng/ml and/or thyroid-stimulating hormone <0.34 uIU/ml

Hormonal status change data during 4–9 month-postoperative period are also shown in Table 2. Out of 83 patients who had preoperative intact hypothalamic-pituitary-adrenal (HPA) axis and hypothalamic pituitary thyroidal (HPT) axis, two patients (2.14%) developed postoperative impair HPA axis, and three patients (3.61%) developed postoperative impair HPT axis. In addition, among 45 patients who had preoperative impair HPA and HPT axis, six of them (13.33%) achieved postoperative endocrinological normalization.

Discussion

Although EETA tumor removal is a less invasive surgery,^[9-12] it is important to beware of postoperative complications, especially the problem of electrolyte and hormonal disturbances from the pituitary gland and stalk manipulation during the operation.^[13,14] Our hospital, PNI, is a tertiary care unit that receive complicated neurosurgical cases from all over Thailand. In total, we operated 126 cases of EETA tumor removal of nonfunction pituitary adenoma (equivalent to 2–3 operations per month) by four surgeons within the study period of 5 years.

To the best of our knowledge, this study is one of a few single center studies that analyze data from more than 100 nonfunctioning pituitary adenomas patients who underwent endoscopic endonasal transsphenoidal approach pituitary tumor removal surgery over a period of 5 years. Comparing to other international studies^[15-19] [Table 3], our average age of patients, average operation time, the extend of resection, and postoperative anterior pituitary dysfunction and persistent DI were similar to them.

In addition, the study results show that we had seven cases (5.56%) of postoperative meningitis or central nervous system infection but culturing results from cerebrospinal fluid of these patients found pathogen in only one case. We also had three cases (2.38%) of death that higher than the death reported in the other studies.^[20-23] Further investigation of these three cases found that they all had meningitis complication. Moreover, in one of these cases, culturing result found *Citrobacter koseri* bacteria which were sensitive to cephalosporin antibiotics.

In patients with preoperative intact pituitary hormone level, we found that after having total or near total tumor

Table 2: Hormonal axis change during 4–9 months postoperative period

Hormonal status	n (%)
Preoperative intact HPA and HPT axis	83
Postoperative impair HPA axis	2 (2.41)
Postoperative impair HPT axis	3 (3.61)
Preoperative impair HPA and HPT axis	45
Postoperative normalized HPA and HPT axis	6 (13.33)

HPA – Hypothalamic-pituitary-adrenal; HPT – Hypothalamic-pituitary-thyroidal

Table 3: Review endoscopic endonasal transsphenoidal approach with tumor removal and nonfunctioning pituitary adenoma

Study design	Single Center					Multi-Center
	Retrospective Current study	Retrospective Wongsirisuwan M	Retrospective Zhan R	Prospective Prajapati HP	Retrospective Adam N	Prospective Little AS (TRANSSPHER)
Pituitary adenoma cases (<i>n</i>)	NFPA 126	All PA 38	All PA 56	All PA 17	All 276 (NFPA 164)	NFPA 169
Study year	January 2013– December 2017	January 2003– September 2013	July 2009– June 2014	NA	2006–2011	February 2015– June 2017
Study time (months)	60	129	58	NA	NA	29
Average age (years-old)	49	43.2	16.6	41.06	51.6	57.6
Average operation time (min)	134	118	NA	111	NA	NA
Total or near total tumor removal, <i>n</i> (%)	101 (80.16)	28 (73.7)	49 (87.5)	11 (64.7)	137/164 (83.5)	134 (79.3)
Postoperative anterior pituitary dysfunction, <i>n</i> (%)	HPA 2/83 (2.41) HPT 3/83 (3.61)	0 (0)	4 (7.1)	0 (0)	8 (2.8)	HPA 4/135 (3.0) HPT 6/97 (6.2)
Overall DI, <i>n</i> (%)	Early PO 61 (48.41) 4–6 Mo PO 12 (9.52)	5 (13.2)	6 (10.6)	2 (11.8)	32/276 (11)	4/169 (2.4)
Hyponatremia or SIADH, <i>n</i> (%)	Early PO 35 (27.78) 1–3 Months PO 5 (3.97) 4–9 Months PO 2 (1.59)	NA	NA	NA	37/276 (13.4)	NA
CNS infection or meningitis, <i>n</i> (%)	7 (5.56)	0 (0)	1 (1.7)	NA	NA	NA
Death, <i>n</i> (%)	3 (2.38)	1 (2.2)	0 (0)	NA	1/276 (0.4)	NA

NFPA – Nonfunctioning pituitary adenoma; PA – Pituitary adenoma; NA – Not assess; Postop – Post-operative; HPA – Hypothalamus -pituitary -adrenal axis; HPT – Hypothalamus -pituitary -thyroid axis; DI – Diabetes insipidus; Early PO – Within 2 weeks postoperative; PO – Postoperative; SIADH – Syndrome of inappropriate antidiuretic hormone; CNS – Central nervous system

removal, many of them may have hypopituitarism during early postoperative period. However, in most of those cases, the hypopituitarism gradually disappeared and they had pituitary hormone function returned to normal level during 4–6 months postoperative period. These results support the use of total or near total tumor removal approach in this group of patients because there is a high chance that their pituitary hormone level will be recovered after the operation.^[24]

In contrast, for patients who had preoperative impair HPA and HPT axis, only small percentages (13.3% or 6 cases) of these patients had their pituitary hormone level recover after operation. This might be because almost all our cases are macroadenoma. It could suppress normal pituitary gland function for a long time while undergoing referral process from other hospitals. Therefore, a chance to recover pituitary hormone function should not be used to justify the extension of tumor removal in these patients.

Conclusion

Endoscopic endonasal transsphenoidal surgery is one of the minimal invasive surgery techniques for removing pituitary tumors. After the surgery, multidisciplinary team consists of

neurosurgeon, endocrinologist, internist, and neurosurgical nurse should closely monitor the patient and beware of medical complications and hormonal disturbances such as DI,^[25] hypocortisolism, central hypothyroidism, hyponatremia, and CNS infection. The results from this study should be able to help surgical and medical treatment team to better prepare for these complications and further enhance patient survival rate in future.

Furthermore, in preoperative intact pituitary hormone patients, the total or near total tumor removal may have hypopituitarism during the early postoperative period but gradually returned to normal during 4–6 months' postoperative period. In contrast, for patients who had preoperative hypopituitarism, only small percentages of these patients had their pituitary hormone level recover after the operation.

Financial support and sponsorship

Nil.

Conflicts of interest

There are no conflicts of interest.

References

- Dorward NL. Endocrine outcomes in endoscopic pituitary surgery: A literature review. *Acta Neurochir (Wien)* 2010;152:1275-9.
- Razak AA, Horridge M, Connolly DJ, Warren DJ, Mirza S, Muraleedharan V, *et al.* Comparison of endoscopic and microscopic trans-sphenoidal pituitary surgery: Early results in a single centre. *Br J Neurosurg* 2013;27:40-3.
- Wagenmakers MA, Boogaarts HD, Roerink SH, Timmers HJ, Stikkelbroeck NM, Smit JW, *et al.* Endoscopic transsphenoidal pituitary surgery: A good and safe primary treatment option for Cushing's disease, even in case of macroadenomas or invasive adenomas. *Eur J Endocrinol* 2013;169:329-37.
- Ozgural O, Kahilogullari G, Dogan I, Al-Beyati ES, Bozkurt M, Tetik B, *et al.* Single-center surgical experience of the treatment of craniopharyngiomas with emphasis on the operative approach: endoscopic endonasal and open microscopic transcranial approaches. *J Craniofac Surg* 2018;29:e572-e578.
- D'Haens J, Van Rompaey K, Stadnik T, Haentjens P, Poppe K, Velkeniers B. Fully endoscopic transsphenoidal surgery for functioning pituitary adenomas: A retrospective comparison with traditional transsphenoidal microsurgery in the same institution. *Surg Neurol* 2009;72:336-40.
- Fang J, Xie S, Li N, Jiang Z. Postoperative complications of endoscopic versus microscopic transsphenoidal pituitary surgery: A meta-analysis. *J Coll Physicians Surg Pak* 2018;28:554-9.
- Goce S, Raymond V, Bruno A, Djillali A, Steve B, Daniel B, *et al.* Clinical practice guideline on diagnosis and treatment of hyponatraemia. *Nephrol Dial Transplant* 2014;29 Suppl 2:ii1-39.
- Nieman LK. Dynamic evaluation of adrenal hypofunction. *J Endocrinol Invest* 2003;26:74-82.
- Frank G, Pasquini E, Farneti G, Mazzatenta D, Sciarretta V, Grasso V, *et al.* The endoscopic versus the traditional approach in pituitary surgery. *Neuroendocrinology* 2006;83:240-8.
- Dehdashti AR, Ganna A, Karabatsou K, Gentili F. Pure endoscopic endonasal approach for pituitary adenomas: Early surgical results in 200 patients and comparison with previous microsurgical series. *Neurosurgery* 2008;62:1006-15.
- Schaberg MR, Anand VK, Schwartz TH, Cobb W. Microscopic versus endoscopic transnasal pituitary surgery. *Curr Opin Otolaryngol Head Neck Surg* 2010;18:8-14.
- Saito K, Kuwayama A, Yamamoto N, Sugita K. The transsphenoidal removal of nonfunctioning pituitary adenomas with suprasellar extensions: The open sella method and intentionally staged operation. *Neurosurgery* 1995;36:668-75.
- Marić A, Kruljac I, Čerina V, Pećina HI, Šulentić P, Vrkljan M. Endocrinological outcomes of pure endoscopic transsphenoidal surgery: A Croatian Referral Pituitary Center experience. *Croat Med J* 2012;53:224-33.
- Jahangiri A, Wagner J, Han SW, Zygourakis CC, Han SJ, Tran MT, *et al.* Morbidity of repeat transsphenoidal surgery assessed in more than 1000 operations. *J Neurosurg* 2014;121:67-74.
- Zhan R, Xu G, Wiebe TM, Li X. Surgical outcomes of the endoscopic transsphenoidal route to pituitary tumours in paediatric patients & 10 years of age: 5 years of experience at a single institute. *Arch Dis Child* 2015;100:774-8.
- Prajapati HP, Jain SK, Sinha VD. Endoscopic versus microscopic pituitary adenoma surgery: An institutional experience. *Asian J Neurosurg* 2018;13:217-21.
- Little AS, Gardner PA, Fernandez-Miranda JC, Chicoine MR, Barkhoudarian G, Prevedello DM, *et al.* Pituitary gland recovery following fully endoscopic transsphenoidal surgery for nonfunctioning pituitary adenoma: Results of a prospective multicenter study. *J Neurosurg* 2019;15:1-7.
- Mamelak AN, Carmichael J, Bonert VH, Cooper O, Melmed S. Single-surgeon fully endoscopic endonasal transsphenoidal surgery: Outcomes in three-hundred consecutive cases. *Pituitary* 2013;16:393-401.
- Wongsirisuwan M, Karnchanapandh K. Comparative outcomes of keyhole supraorbital approach (KSA) and endonasal endoscopic transsphenoidal approach (EETA) in pituitary surgery. *J Med Assoc Thai* 2014;97:386-92.
- Tabaee A, Anand VK, Barrón Y, Hiltzik DH, Brown SM, Kacker A, *et al.* Endoscopic pituitary surgery: A systematic review and meta-analysis. *J Neurosurg* 2009;111:545-54.
- Cavallo LM, Solari D, Tasiou A, Esposito F, de Angelis M, D'Enza AI, *et al.* Endoscopic endonasal transsphenoidal removal of recurrent and regrowing pituitary adenomas: Experience on a 59-patient series. *World Neurosurg* 2013;80:342-50.
- Goudakos JK, Markou KD, Georgalas C. Endoscopic versus microscopic trans-sphenoidal pituitary surgery: A systematic review and meta-analysis. *Clin Otolaryngol* 2011;36:212-20.
- Halvorsen H, Ramm-Petersen J, Josefsen R, Rønning P, Reinlie S, Meling T, *et al.* Surgical complications after transsphenoidal microscopic and endoscopic surgery for pituitary adenoma: A consecutive series of 506 procedures. *Acta Neurochir (Wien)* 2014;156:441-9.
- Bynke O, Hillman J. Role of transsphenoidal operation in the management of pituitary adenomas with suprasellar extension. *Acta Neurochir* 1989;100:50-5.
- Schreckinger M, Szerlip N, Mittal S. Diabetes insipidus following resection of pituitary tumors. *Clin Neurol Neurosurg* 2013;115:121-6.