

Outcome of Decompressive Craniectomy for Traumatic Brain Injury: An Institutional-Based Analysis from Nepal

Abstract

Objective: Decompressive craniectomy (DC) is one of the commonly used treatment modalities for refractory intracranial hypertension after traumatic brain injury. The objective of this study is to assess the functional outcome following DC in closed traumatic brain injury based on Glasgow Outcome Scale (GOS). **Materials and Methods:** This is a retrospective study conducted at Nepal Medicit Hospital, Nepal, from September 2017 to October 2019. Data of the patients who had undergone DC for closed traumatic brain injury were reviewed from medical record files. Patients who had DC for nontraumatic causes were excluded from the study. Functional outcome was assessed using GOS at 3 months of follow-up. **Results:** Of the 52 decompressive craniectomies, 46 were included in the study. The majority was male (71.7%). The mean age and the mean Glasgow Coma Scale (GCS) score at presentation were 41.87 (standard deviation [SD] \pm 15.29) and 7.59 (SD \pm 2.97), respectively. The most common mode of injury was road traffic accident (76.1%). 60.9% had GCS score \leq 8 while 39.1% had $>$ 8 GCS on admission. 34.8% had both the pupils reactive while 58.7% were anisocoric. Majority had Marshall IV and above grade of injury (67.4%). Sixteen (34.8%) had in-hospital mortality. Favorable outcome was seen in 39.1%. GCS score $>$ 8 at presentation (72.2%, $P < 0.001$), bilaterally intact pupillary reflexes (75%, $P < 0.001$), Marshall grade injury \leq 3 on computed tomography scan (90%, $P < 0.001$), and age $<$ 50 years (50%, $P = 0.039$) were significantly associated with favorable outcome. Procedure-related complications were seen in 36.9%. **Conclusion:** Favorable outcome was seen in 39.1%. Age $<$ 50 years, higher GCS score at presentation ($>$ 8), intact pupillary reflexes, and lower Marshall grade injuries were associated with favorable outcome. We recommend a larger prospective study to assess the long-term functional outcome after DC using extended GOS.

Keywords: Decompressive craniectomy, Glasgow Outcome Scale, outcome, traumatic brain injury

Introduction

Uncontrolled intracranial pressure (ICP) has long been recognized as one of the major causes of morbidity and mortality following severe traumatic brain injury (TBI). Monitoring and reduction of ICP have remained the cornerstone of the management of TBI patients. Approximately 60% of patients with severe brain injury either die or survive with severe disability whereas raised ICP does not respond to medical management, mannitol, and hyperventilation in 10%–15% of patients.^[1] Surgical decompressive craniectomy (DC) is performed as a resort to reduce ICP in such cases to minimize secondary brain damage.^[2,3]

The concept of DC has been advocated since 1894 for control and relief of ICP.^[4]

DC refers to the removal of a large bone flap and opening of underlying dura to control brain swelling and raised ICP.^[5] DC is supposed to improve oxygen delivery to brain cells by improving blood flow.^[6] However, it is still not clear if DC improves functional outcome in patients with severe TBI and refractory-raised ICP. The current evidence from multicenter clinical trials (the DECRA and RESCUEicp) suggests that DC is not superior to medical management for patients with diffuse TBI which, though found to have decreased mortality, was associated with increase in disability compared to medical management.^[7,8]

TBI remains the major public health problem globally with low- and middle-income countries bearing the biggest burden. As limited data are available on

**Damber
Bikram Shah,
Prakash Paudel,
Sumit Joshi,
Prasanna Karki,
Gopal Raman
Sharma**

*Department of Neurosciences,
Nepal Medicit Hospital,
Lalitpur, Nepal*

Address for correspondence:

*Dr. Prakash Paudel,
Department of Neurosciences,
Nepal Medicit Hospital, PO
Box 44600, Sainbu, Lalitpur,
Nepal.*

E-mail: docppaudel@gmail.com

Access this article online

Website: www.asianjns.org

DOI: 10.4103/ajns.AJNS_392_20

Quick Response Code:



This is an open access journal, and articles are distributed under the terms of the Creative Commons Attribution-NonCommercial-ShareAlike 4.0 License, which allows others to remix, tweak, and build upon the work non-commercially, as long as appropriate credit is given and the new creations are licensed under the identical terms.

For reprints contact: WKHLRPMedknow_reprints@wolterskluwer.com

How to cite this article: Shah DB, Paudel P, Joshi S, Karki P, Sharma GR. Outcome of decompressive craniectomy for traumatic brain injury: An institutional-based analysis from Nepal. *Asian J Neurosurg* 2021;16:288-93.

Submitted: 10-Aug-2020

Revised: 25-Nov-2020

Accepted: 16-Mar-2021

Published: 28-May-2021

the outcome after DC in traumatic brain injuries as well as the socioeconomic impact of unfavorable outcome is very profound in this part of the world, we aim to conduct a study to assess the functional outcome of DC in closed traumatic brain injury based on Glasgow Outcome Scale (GOS).

Materials and Methods

Study design and patient population

We designed a retrospective study. After taking permission from hospital to collect data, ethical approval was taken from the Institutional Review Committee of Nepal Health Research Council. A consecutive cohort of patients who had undergone DC for closed traumatic brain injury between September 2017 and October 2019 at Nepal Mediciti Hospital, Lalitpur, Nepal, was identified from medical record files. Patients who had DC for causes other than trauma and whose follow-up period was <3 months were excluded from the study. Data collected from medical record files included age, sex, mode of injury, Glasgow Coma Scale (GCS) score and pupillary light reflexes at presentation, Marshall computed tomography (CT) classification of brain injury, and postoperative GOS score and procedure-related complications.

Indication for decompressive craniectomy

Primary decompressive craniectomy at the time of admission

1. Comatose patients with an acute subdural hematoma and associated brain swelling – either the brain was bulging beyond the inner table of the skull or increasing brain swelling was anticipated in the postoperative period [Figure 1] or
2. Patients with severe mass effect and clinical signs of herniation or
3. Closed TBI with diffuse brain swelling without any significant hematomas or contusions – these patients underwent primary DC as ICP monitoring is not available in our daily practice.

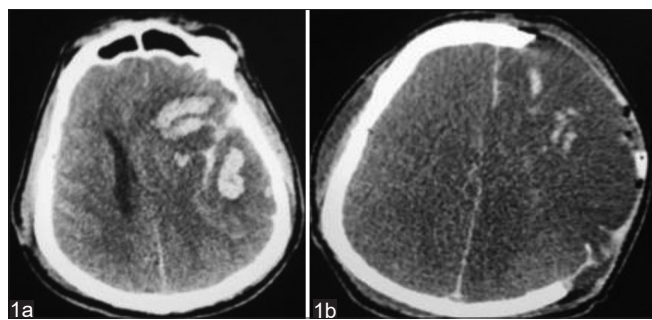


Figure 1: (a) Computed tomography scan of the brain of a 24-year-old male showing large contusion with significant mass effect, (b) Immediate postoperative computed tomography scan showing external brain herniation

Secondary decompressive craniectomy

1. Patients with parenchymal hemorrhage or contusions or diffuse axonal injury who were initially managed medically in neurointensive care unit but later deteriorated neurologically with radiological evidence of increasing mass effect or
2. Patients who had a craniotomy earlier for evacuation of an intracranial hematoma, however, the control of ICP became difficult later due to expansion of contusion.

Contraindications

1. Patients with GCS 3 postresuscitation, with dilated and fixed pupils
2. Devastating trauma that will not allow patient survive more than 24 h.

Surgical technique

Surgical decompression was done by removing a large frontotemporoparietal bone flap of at least 12 cm in diameter in case of hemicraniectomy [Figure 2a] while bifrontal DC refers to the removal of a bone flap extending from the floor of the anterior cranial fossa to the coronal suture and to the middle cranial fossa floor bilaterally [Figure 3b]. Following bone removal, dura was opened by performing multiple small incisions over the entire surface of the exposed dura, dural leaves were reflected, and then, laxated duroplasty was performed using autologously harvested pericranium [Figure 2b]. Unilateral hemicraniectomy procedures were performed in patients with traumatic lesions prominently localized in one cerebral hemisphere [Figure 1a] while bifrontal decompression was done in cases with diffuse brain edema without midline shift [Figure 3a].

Study measures/statistics

Neurological outcome was assessed at 3 months after discharge during follow-up examination. For those who could not attend the follow-up clinic, outcome was assessed by interviewing rehabilitation staff or family members. Categorical variables such as sex, pupillary response to light, and functional outcome (GOS) were analyzed using frequencies and percentages whereas variables such as age and preoperative GCS score were summarized using means \pm standard deviation. Outcome was categorized one to five based on GOS.^[9] For statistical purposes, GOS was dichotomized as a favorable (GOS 4 and 5) or unfavorable outcome (GOS score equal or less than 3) and age was dichotomized as ≤ 50 years or more. CT grade was divided into two categories (Marshall Grade I to III vs. Marshall Grade IV to VI). Pupillary light reflex was dichotomized as those with both the pupils reactive to light versus others (anisocoric and/or pupils nonreacting to light). Association of independent variables with the primary outcome variable (favorable outcome) was analyzed using Chi-squared test. Statistical significance was determined

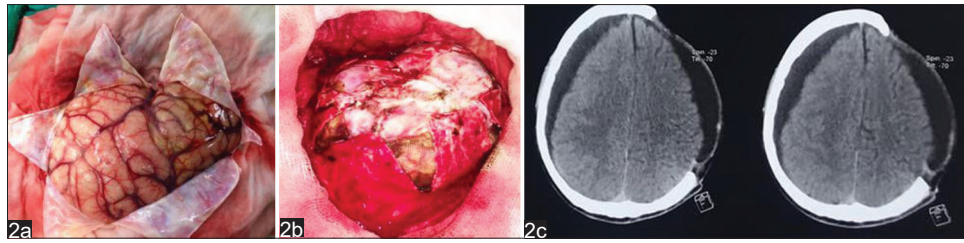


Figure 2: (a) Intraoperative image showing brain bulging beyond the inner table of skull after durotomy, (b) Laxed duroplasty with autologous pericranium, (c) Postoperative computed tomography scan of the brain showing bilateral subdural collection

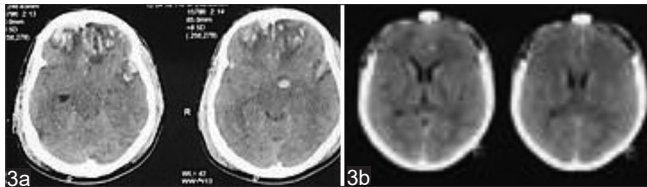


Figure 3: (a) Computed tomography scan brain showing bifrontal contusion with obliteration of basal cistern without midline shift, (b) Postoperative computed tomography scan after bifrontal decompressive craniectomy

at $P < 0.05$. Analysis was performed in SPSS 17 (IBM, Chicago, IL, USA).

Results

Demographics and clinical variables

A total of 492 patients with traumatic brain injury were managed in our hospital during the study period. Of them, 76.62% were managed with medical management while 23.78% required surgical intervention. The details of types of TBIs and treatment received are mentioned in Figure 4.

Decompressive craniectomies were performed in 52 patients. After excluding 6 patients, 46 were included in the analysis. The mean age was 41.87 (standard deviation [SD] \pm 15.29). Thirty-three (71.7%) were male and 13 (28.3%) were female. The mean GCS score at presentation was 7.59 (SD \pm 2.97). 60.9% had GCS score \leq 8 while 39.1% had GCS $>$ 8 score on admission. 34.8% had both the pupils reactive to light while 58.7% were anisocoric. The most common mode of injury was road traffic accident (76.1%) followed by fall injury in 19.6%. Around two-thirds of the patients (67.4%) had IV or more Marshall grade injury. Sixteen (34.8%) had in-hospital mortality. Functional outcome at 3-month follow-up showed good recovery in 23.9%, moderate disability in 15.2%, severe disability in 17.4%, and persistent vegetative state in 8.7%. No further mortality was found in follow-up. Procedure-related complications were seen in 36.9%.

Functional outcome according to clinical and demographic characteristics

Overall favorable outcome was seen in 39.1%. Age $<$ 50 years, GCS score $>$ 8 at presentation, bilaterally intact pupillary reflexes, and Marshall grade injury \leq 3 on CT scan were significantly associated with favorable

outcome. Of the total in-hospital deaths ($n = 16$), 81.2% had GCS \leq 8 and 18.8% had GCS $>$ 8 ($P = 0.039$). [Table 1]

Discussion

In our cohort of 46 patients who underwent DC for raised and refractory ICP, favorable outcome (GOS 4 and 5) was seen in 39.1%. Age $<$ 50 years, higher GCS score at presentation ($>$ 8), preserved bilateral pupillary reflexes, and Marshall grade injury \leq 3 on CT scan were significantly associated with favorable outcome. In-hospital mortality was higher among patients above 50 years of age, but this was not statistically significant ($P = 0.351$).

The overall favorable outcome seen in our study (39.1%) was consistent with previous studies. Aarabi *et al.* reported 40% favorable outcome (GOS 4 or 5) among TBI patients who were followed up for at least 3 months after DC.^[10] Similarly, a retrospective study by Laghari *et al.* from Pakistan found that 51.4% had favorable outcome after DC at 3-month follow-up.^[11] Two major multicenter randomized trials, based on extended GOS (GOSE), reported favorable outcome in 30% (DECRA trial) and 42.8% (RESCUEicp) of severe TBI patients at 6 months after DC. However, both of these trials concluded that DC was associated with more unfavorable outcome compared to standard medical care.^[7,8]

GCS score of 8 and above (72.20% vs. 17.90%) and age $<$ 50 years (50% vs. 18.80%) were found to be associated with better outcome in our series. Choudhary and Bhargava from India reported that younger patients had more favorable outcome (64% vs. 19%) than patients of age $>$ 50 years, and also, mortality was higher among the elderly (above 50 years).^[12] Similar to the above findings, other previous studies have also reported age as one of the predictors of better outcome, age being more than 50 years associated with unfavorable outcome and higher complications.^[13-16] We observed that patients with GCS score of 8 and above had significantly higher favorable outcome (72.2%, $P < 0.001$) as well as higher survival rate (83.3%, $P = 0.039$). Comparable to our finding, Aarabi *et al.* in their retrospective study reported good outcome in 67% of patients who had GCS score of 9 and above ($P < 0.05$).^[10] Similar findings of better outcome with higher GCS at presentation were reported in previous literatures.^[14,17]

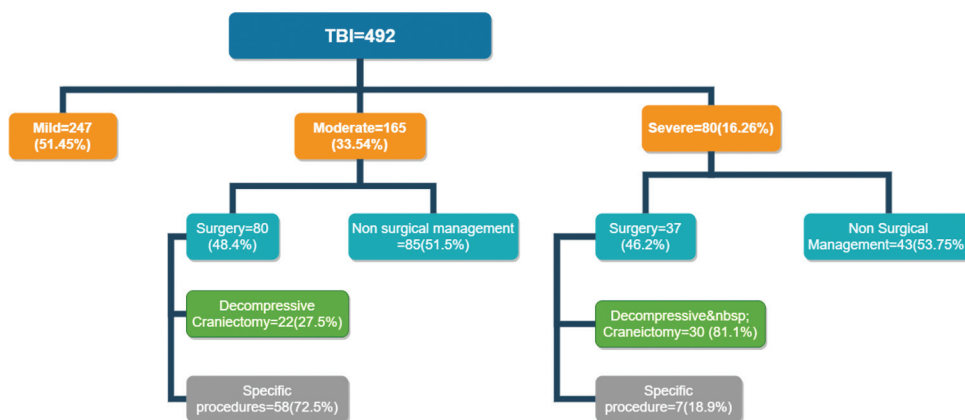


Figure 4: Distribution of traumatic brain injury cases according to severity and treatment

Table 1. Association of variables with functional outcome(GOS*), n=46

Variables	Outcome(GOS)		P
	Favourable (n=18)	Unfavourable (n=28)	
Age			
<50 years	50%	50%	0.039
>=50 years	18.80%	81.30%	
Sex			
Male	42.40%	57.60%	0.466
Female	30.80%	69.20%	
GCS** Score			
<=8	17.90%	82.10%	<0.001
>8	72.20%	27.80%	
Pupillary light reflex			
B/L Reactive	75%	25%	<0.001
Anisocoria/Non reactive	20%	80%	
CT Marshal grade			
Grade I, II, III	90%	10%	<0.001
Grade IV, V, VI	25%	75%	

* Glasgow Outcome Scale, ** Glasgow Coma Scale

As with GCS score, the quality of outcome after DC was also found to be associated with the degree of midline shift in the initial cranial computed tomography and pupil reactivity. Absent pupil reflexes and preoperative midline shift >1 cm were significant predictors of poor outcome.^[16,17] In our cohort, we dichotomized the CT grade as Marshall Class ≤III (midline shift <5 mm) or more. Favorable outcome was significantly higher among patients with Marshall Class ≤III (90% vs. 25%, $P < 0.001$) and those with reacting pupils (75% vs. 20%, $P < 0.001$).

Although DC seems to be straightforward and simpler technically, it is associated with significant short- and long-term complications. In our series, complications were seen in 36.9%. Six had expansion of contusion after DC, three developed subdural collection [Figure 2c], external brain herniation [Figure 1b] was seen in five patients, and three patients developed hydrocephalus for which VP shunt

was required. Yang *et al.* reviewed 68 patients in which the incidence rates of complications were 26.5% for subdural effusion, 29.4% for posttraumatic hydrocephalus, 5.9% for intracranial infection, 8.8% for posttraumatic epilepsy, and 52.9% for syndrome of the trephined.^[18] Similarly, in another report, Yang *et al.* found external herniation in 27.8%, subdural collection in 21.3%, and postoperative Hydrocephalus (HCP) in 9.3% of 108 patients.^[19]

Current evidence, dilemma, and alternatives

Outcome of TBI has significantly improved in recent years with the advancement in prehospital care, imaging technology, and intensive and supportive care. However, the mortality and long-term consequences of severe TBI are still high. Although significant efforts are being made to generate a high level of evidence base for DC, the results are still varied. DECRA trial examined the role of bifrontal DC and found that neuroprotective bifrontal DC for moderate intracranial hypertension was not helpful;^[7] RESCUEicp trial examined the role of last-tier secondary DC for severe and refractory intracranial hypertension, which significantly reduced the mortality rate but also increased the disability rate.^[8] RESCUEASDH trial is an ongoing trial examining the role of primary DC for acute subdural hematoma.^[20] Koliais *et al.* reviewed the current status of DC in TBI and have outlined the following unresolved issues: indications for DC in various TBI subtypes, alternative techniques (e.g., hinge craniotomy), optimal time and material for cranial reconstruction, and the role of shared decision-making in TBI care.^[21] Although DC is an accepted technique for control of refractory intracranial hypertension, it is associated with higher complication rate and also requires second surgery (cranioplasty). This has led to exploration of newer and safer techniques. Recently, basal cisternostomy has been introduced for the management of ICP in severe TBI.^[22] Cisternostomy opens the basal cisterns to atmospheric pressure and causes a “backshift” of CSF through the Virchow–Robin spaces (glymphatic pathway), thereby reducing the intrabrain pressure. The glymphatic pathway allows CSF influx along almost all penetrating

arteries and efflux along some large and deep veins.^[23,24] Considering the current level of evidence, cisternostomy is yet to be properly validated and seems to have some major technical and logistic limitations such as difficult to access the cistern due to gross brain swelling, availability of microscope intraoperatively (which may not be available in all centers and at emergency situation), and the technical expertise required to perform cisternostomy.

Our study has few limitations. It is a descriptive, retrospective study with a relatively small number of patients, with heterogeneous demography (wide range of age group 11–71 years) and clinical characteristics. As we do not have ICP monitoring facility, the indication for DC was based on clinical and radiological findings. Provision of invasive monitoring may decrease the frequency of DC. Follow-up period was limited to 3 months, so we were not able to use GOSE which is one of the best tools to assess long-term functional outcome after decompressive craniectomy.

Conclusion

In our cohort of patients who had DC for traumatic brain injury, 39.1% had favorable outcome at 3 months. Age <50 years, higher GCS score at presentation (>8), intact pupillary reflexes, and lower Marshall grade injuries were significantly associated with favorable outcome. Improving patient selection and having a provision of ICP monitoring may optimize the outcome of decompressive craniectomy. We recommend a larger prospective study to assess the long-term functional outcome after DC using GOSE in Nepalese context.

Declaration of patient consent

The authors certify that they have obtained all appropriate patient consent forms. In the form the patient(s) has/have given his/her/their consent for his/her/their images and other clinical information to be reported in the journal. The patients understand that their names and initials will not be published and due efforts will be made to conceal their identity, but anonymity cannot be guaranteed.

Financial support and sponsorship

Nil.

Conflicts of interest

There are no conflicts of interest.

References

- Marshall LF. Head injury: Recent past, present, and future. *Neurosurgery* 2000;47:546-61.
- Brown DA, Wijdicks EF. Decompressive craniectomy in acute brain injury. *Handb Clin Neurol* 2017;140:299-318.
- Adams H, Kolia AG, Hutchinson PJ. The role of surgical intervention in traumatic brain injury. *Neurosurg Clin N Am* 2016;27:519-28.
- Spiller WG, Frazier CH. Palliative operations in the treatment of tumour in the brain, based on the observation of fourteen cases. *JAMA* 1906;47:679-83.
- Coplin WM, Cullen NK, Policherla PN, Vinas FC, Wilseck JM, Zafonte RD, *et al.* Safety and feasibility of craniectomy with duraplasty as the initial surgical intervention for severe traumatic brain injury. *J Trauma* 2001;50:1050-9.
- Jaeger M, Soehle M, Meixensberger J. Effects of decompressive craniectomy on brain tissue oxygen in patients with intracranial hypertension. *J Neurol Neurosurg Psychiatry* 2003;74:513-5.
- Cooper DJ, Rosenfeld JV, Murray L, Arabi YM, Davies AR, D'Urso P, *et al.* Decompressive craniectomy in diffuse traumatic brain injury. *N Engl J Med* 2011;364:1493-502.
- Hutchinson PJ, Kolia AG, Timofeev IS, Corteen EA, Czosnyka M, Timothy J, *et al.* Trial of decompressive craniectomy for traumatic intracranial hypertension. *N Engl J Med* 2016;375:1119-30.
- Jennett B, Bond M. Assessment of outcome after severe brain damage. *Lancet* 1975;1:480-4.
- Aarabi B, Hesdorffer DC, Ahn ES, Aresco C, Scalea TM, Eisenberg HM. Outcome following decompressive craniectomy for malignant swelling due to severe head injury. *J Neurosurg* 2006;104:469-79.
- Laghari AA, Bari ME, Waqas M, Ahmed SI, Nathani KR, Moazzam W. Outcome of decompressive craniectomy in traumatic closed head injury. *Asian J Neurosurg* 2018;13:1053-6.
- Choudhary NK, Bhargava R. Decompressive craniectomy in diffuse traumatic brain injury: An industrial hospital study. *Asian J Neurosurg* 2018;13:314-8.
- Guerra WK, Gaab MR, Dietz H, Mueller JU, Piek J, Fritsch MJ. Surgical decompression for traumatic brain swelling: Indications and results. *J Neurosurg* 1999;90:187-96.
- Tian R, Liu W, Dong J, Zhang J, Xu L, Zhang B, *et al.* Prognostic predictors of early outcomes and discharge status of patients undergoing decompressive craniectomy after severe traumatic brain injury. *World Neurosurg* 2019;126:e101-8.
- Schneider GH, Bardt T, Lanksch WR, Unterberg A. Decompressive craniectomy following traumatic brain injury: ICP, CPP and neurological outcome. *Acta Neurochir Suppl* 2002;81:77-9.
- Meier U, Lemcke J, Reyer T, Gräwe A. Decompressive craniectomy for severe head injury in patients with major extracranial injuries. *Acta Neurochir Suppl* 2006;96:373-6.
- van Veen E, Aerdts S, van den Brink W. Decompressive (hemi) craniectomy for refractory intracranial hypertension after traumatic brain injury. *Crit Care* 2006;10 Suppl 1:458.
- Yang XJ, Hong GL, Su SB, Yang SY. Complications induced by decompressive craniectomies after traumatic brain injury. *Chin J Traumatol* 2003;6:99-103.
- Yang XF, Wen L, Shen F, Li G, Lou R, Liu WG, *et al.* Surgical complications secondary to decompressive craniectomy in patients with a head injury: A series of 108 consecutive cases. *Acta Neurochir (Wien)* 2008;150:1241-7.
- Kolia AG, Adams H, Timofeev I, Czosnyka M, Corteen EA, Pickard JD, *et al.* Decompressive craniectomy following traumatic brain injury: Developing the evidence base. *Br J Neurosurg* 2016;30:246-50.
- Kolia AG, Viaroli E, Rubiano AM, Adams H, Khan T, Gupta D, *et al.* The current status of decompressive craniectomy in traumatic brain injury. *Curr Trauma Rep* 2018;4:326-32.
- Cherian I, Yi G, Munakomi S. Cisternostomy: Replacing the age old decompressive hemicraniectomy? *Asian J Neurosurg*

- 2013;8:132-8.
23. Iliff JJ, Wang M, Liao Y, Plogg BA, Peng W, Gundersen GA, *et al.* A paravascular pathway facilitates CSF flow through the brain parenchyma and the clearance of interstitial solutes, including amyloid β . *Sci Transl Med* 2012;4:147ra111.
 24. Cherian I, Bernardo A, Grasso G. Cisternostomy for traumatic brain injury: Pathophysiologic mechanisms and surgical technical notes. *World Neurosurg* 2016;89:51-7.