

Case Report

Tumor Recurrence in a Glioblastoma Patient after Discontinuation of Prolonged Temozolomide Treatment

Abstract

There is no consensus regarding the duration of temozolomide (TMZ) treatment for glioblastoma multiforme (GBM). We report a 53-year-old woman who had a left frontal GBM. The tumor showed good response to TMZ treatment, which was discontinued after 5.5 years with recurrence of tumor at the posterior fossa 6 months later, although there was no definite tumor recurrence in the left frontal region. The tumor failed to respond to the reinstatement of TMZ therapy. Continuous TMZ treatment may be necessary in GBM patients on prolonged TMZ treatment despite improved neurological condition and imaging studies revealing marked tumor regression.

Keywords: Glioblastoma, temozolomide, tumor recurrence

Introduction

Glioblastoma multiforme (GBM) is the most common and most aggressive primary brain tumor in adults. The current treatment of GBM includes maximal surgical resection, followed by postoperative chemoradiation (combined temozolomide [TMZ] treatment and radiotherapy) and monthly TMZ therapy.^[1-3] Because of its infiltrative nature, GBM eventually recurs and the prognosis of patients with GBM is still poor.^[4-8] However, the use of TMZ has prolonged survival in some patients.^[4-8]

There is no consensus regarding the appropriate duration of TMZ treatment, and it is a common practice to prolong TMZ treatment until there is evidence of tumor progression or development of toxicity.^[5,7] In addition, whether TMZ can be discontinued when the tumor shows good response to prolonged treatment is still unclear.^[4,5,8] In this report, we present a case of a patient with GBM who showed good response to TMZ treatment. After 5.5 years of TMZ treatment, TMZ was discontinued because of withdrawal of insurance coverage. The tumor recurred 6 months later and did not respond to reinstatement of TMZ therapy. The patient died 6 years and 9 months after diagnosis.

Method

In this article, we introduced a case who suffered from GBM for more than 5 years.

This is an open access article distributed under the terms of the Creative Commons Attribution-NonCommercial-ShareAlike 3.0 License, which allows others to remix, tweak, and build upon the work non-commercially, as long as the author is credited and the new creations are licensed under the identical terms.

For reprints contact: reprints@medknow.com

The patient's image examination and the clinical course were reviewed.

Case Report

A 53-year-old woman presented with progressive headache, diplopia, nausea, vomiting, poor appetite, and memory impairment for 1 month. On admission, her level of consciousness was intact; however, her short-term memory and arithmetic ability were mildly impaired. She also had unsteady gait, but there were no sensory or motor deficits. T1-weighted magnetic resonance imaging (MRI) revealed a 5-cm hypointense tumor within the left frontal region involving the corpus callosum and left periventricular area extending to the left lateral ventricle [Figure 1a]. The tumor was hyperintense on T2-weighted imaging [Figure 1b]. Gadolinium-enhanced T1-weighted MRI showed irregular enhancement at the tumor margin [Figure 1c and d]. The tumor exhibited mass effect with significant perifocal edema [Figure 1]. The patient underwent craniotomy with subtotal excision of the tumor. At operation, the tumor appeared yellowish-gray, soft, and moderately vascularized. There was no clear margin between the tumor and normal brain. The pathology revealed GBM. The patient tolerated the procedure well with a smooth postoperative course. The postoperative MRI showed some residual tumor [Figure 2a and b].

How to cite this article: Tseng WL, Hsu HH, Chen Y, Tseng SH. Tumor recurrence in a glioblastoma patient after discontinuation of prolonged temozolomide treatment. *Asian J Neurosurg* 2017;12:727-30.

**Wei-Lung Tseng,
Hsu-Hsien Hsu,
Yun Chen^{1,2},
Sheng-Hong Tseng**

*Department of Surgery, National Taiwan University Hospital, Yun-Lin Branch, Douliu, Yunlin,
¹Department of Surgery, Far Eastern Memorial Hospital, Pan-Chiao, New Taipei,
²Department of Chemical Engineering and Materials Science, Yuan Ze University, Chung-Li, Taoyuan, Taiwan, ROC*

Address for correspondence:

*Dr. Sheng-Hong Tseng,
Department of Surgery,
National Taiwan University
College of Medicine, National
Taiwan University Hospital,
7 Chung-Shan South Road,
Taipei 100, Taiwan, ROC.
E-mail: shenghongtseng@gmail.
com*

Access this article online

Website: www.asianjns.org

DOI: 10.4103/ajns.AJNS_39_15

Quick Response Code:



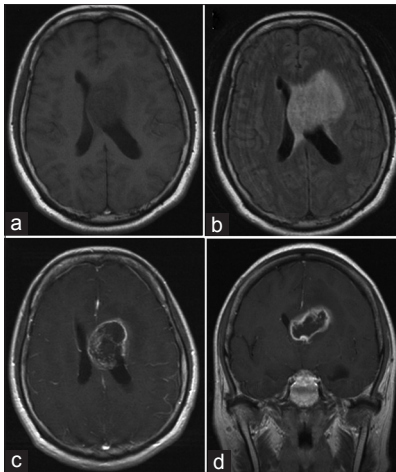


Figure 1: The preoperative MRI of the brain. Preoperative MRI of the brain. (a) Unenhanced T1-weighted MRI, axial section. (b) T2-weighted MRI, axial section. (c) Gadolinium-enhanced T1-weighted MRI, axial section. (d) Gadolinium-enhanced T1-weighted MRI, coronal section. MRI – Magnetic resonance imaging

Radiotherapy (60 Gy) was well tolerated. At that time, TMZ was not administered because the insurance only covered TMZ treatment for recurrent GBM, not newly diagnosed GBM. The patient's condition was stable after radiotherapy; however, she began to experience drowsiness 2.5 months after diagnosis. No other neurological dysfunction was noted. MRI showed tumor regrowth and dilated ventricles [Figure 2c and d]. A ventriculoperitoneal shunt was placed and her level of consciousness improved. With the approval of insurance coverage, TMZ treatment (200 mg/m² per day orally for 5 days to be repeated each month) was started 3 months after diagnosis. She tolerated the TMZ treatment well with no significant side effects. In addition, serial MRI studies revealed a gradual decrease in tumor size [Figure 2]. Her daily life was normal with Karnofsky performance score of 90. Unfortunately, the insurance coverage for the TMZ treatment was withdrawn 5 years and 9 months after diagnosis because the Bureau of Health Insurance considered there was no definite tumor on MRI. In total, she had received TMZ treatment for 5 years and 6 months. Six months after withdrawal of TMZ (6 years and 3 months after diagnosis), she began to experience progressive nausea, vomiting, general malaise, dizziness, gait instability, and choking. Follow-up MRI showed a 3-cm tumor within the posterior fossa although there was no definite tumor recurrence within the left frontal area, as compared with the previous MRIs [Figure 3]. Mannitol and corticosteroids were given and her general condition improved. The family refused surgery. Although there was no tissue proof of GBM recurrence, TMZ treatment was restarted (6 years 4 months after diagnosis) after reapproval of the insurance coverage. However, her condition gradually deteriorated and repeated MRI 3 months later showed dilated ventricles with hyperintense signal within the left frontal horn but no change in the

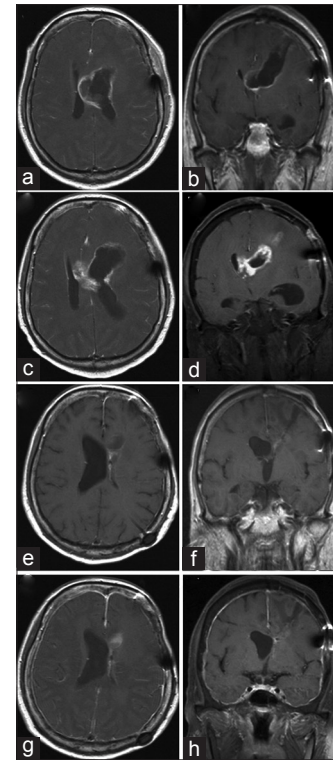


Figure 2: MRI of the brain from 1 week after surgery to 3 years and 4 months after diagnosis. Gadolinium-enhanced T1-weighted MRI. (a and b) 1 week after surgery ([a] axial section, [b] coronal section). (c and d) 2.5 months after diagnosis ([c] axial section, [d] coronal section). (e and f) Two years and 2 months after diagnosis ([e] axial section, [f] coronal section). (g and h) Three years and 4 months after diagnosis ([g] axial section, [h] coronal section). MRI – Magnetic resonance imaging

size of the posterior fossa tumor. She died 6 months after reinstatement of treatment with TMZ (6 years and 9 months after diagnosis).

Discussion

Although long-term treatment with TMZ is well tolerated in patients with GBM, the duration of treatment in patients with GBM is not currently standardized.^[5,7,9] Administration of TMZ is usually continued until there is evidence of tumor progression or development of significant side effects.^[5,7,9] However, prolonged TMZ treatment is uncommon as most patients become resistant to TMZ and the tumors eventually recur.^[6,10,11]

According to the literature, few patients with GBM have been treated with TMZ for longer than 5 years. In addition, there is no consensus regarding whether TMZ can be withdrawn when a GBM patient experiences marked tumor regression (or complete remission) based on imaging studies. One report concerning TMZ treatment in GBM patients described that TMZ had been given for up to 57 cycles and was well tolerated, but the details regarding the history of the long-term survivors and changes in tumor size were not described.^[9] Another article concerned a 30-year-old patient with GBM who showed dramatic

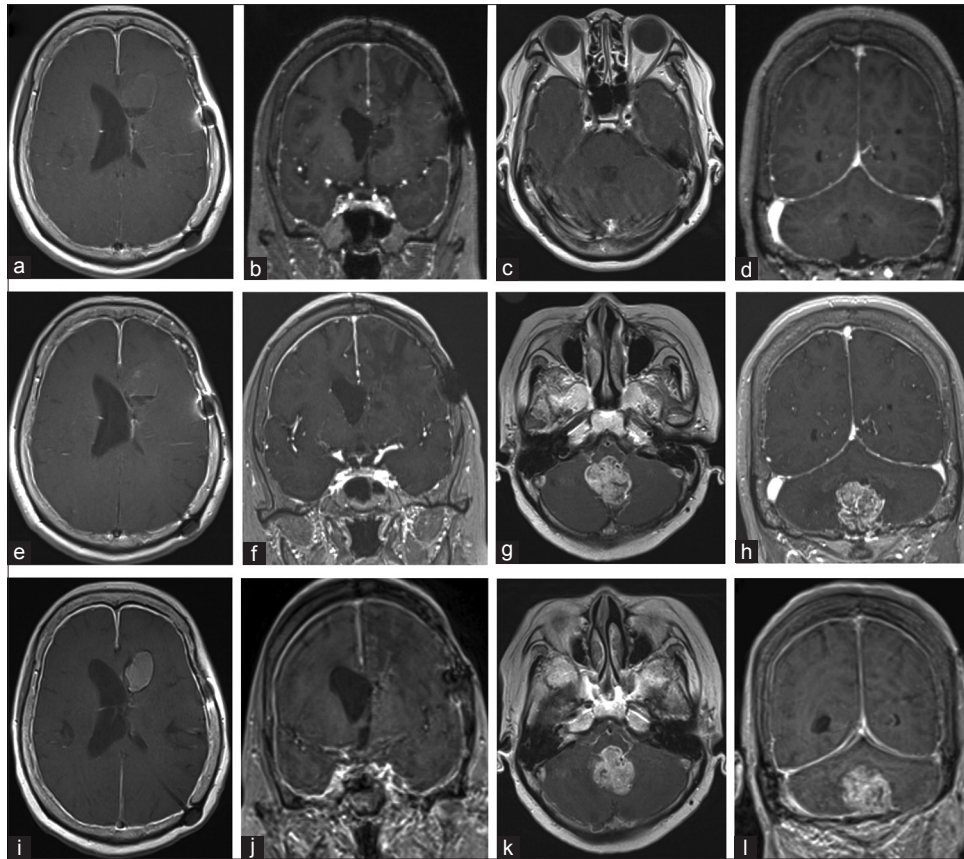


Figure 3: MRI of the brain from 5 years and 8 months to 6 years and 8 months after diagnosis. Gadolinium-enhanced T1-weighted MRI. (a-d) Five years and 8 months after diagnosis ([a and c] axial section, [b and d] coronal section). (e-h) Six years and 4 months after diagnosis ([e and g] axial section, [f and h] coronal section). (i-l) Six years and 8 months after diagnosis ([i and k] axial section, [j and l] coronal section). MRI – Magnetic resonance imaging

clinical and radiological improvement after TMZ treatment and had survived for over 6 years with complete remission, clinically and radiologically.^[7] TMZ treatment was also used for almost 8 years in a 31-year-old GBM patient, without significant hematological toxicity or opportunistic infections.^[11] Our patient had been treated with TMZ for 5.5 years without significant side effects, and the tumor was well controlled. These data suggest that prolonged TMZ treatment for up to 8 years is feasible when there are no significant side effects.

The duration of TMZ therapy has been found to correlate with progression-free survival (PFS) in recurrent high-grade glioma.^[12] The PFS for patients who received 12 to 18 cycles of TMZ and discontinued treatment in the absence of tumor progression was shorter than the PFS in patients who received TMZ for 19 cycles or more.^[12] This suggests that continued therapy with TMZ until tumor progression may improve clinical outcomes.^[12] In addition, the GBM patient already described who survived for 8 years had his TMZ treatment discontinued 18 months after initiation of treatment due to lack of uptake on fluorodeoxyglucose-positron emission tomography (FDG-PET).^[10] Four months after cessation of drug, MRI follow-up revealed tumor progression and repeated FDG-PET showed new uptake; thus, TMZ was

recommended.^[10] Two years later, when his tumor regressed again on MRI and a repeat FDG-PET showed no uptake, another attempt to wean the patient off TMZ by prolonging the cycle interval was made, but MRI 7 months later showed tumor progression and the treatment program was returned to ordinary schedule.^[10] That patient was stable 8 years since commencing TMZ, which suggests that TMZ was still effective for the recurrent GBM. Recurrent GBM occurred when TMZ was temporarily withdrawn or the dose was reduced.^[10] In contrast, our patient's MRI showed tumor within the posterior fossa 6 months after cessation of TMZ treatment, but no definite tumor recurrence at the original site within the left frontal area. The posterior fossa tumor was considered to be consistent with recurrent GBM. However, the tumor did not respond well to TMZ although the tumor size appeared stable during the reinstatement of TMZ.

Our experience combined with literature findings^[10] suggests that the GBM might recur after prolonged TMZ treatment in spite of tumor regression. Such tumor recurrence can occur within 6 months of discontinuation of TMZ and reinstatement of treatment may not be effective. Because GBM patients are at risk of late relapses,^[13] tight maintenance on TMZ without discontinuation may be necessary to overcome tumor

recurrence, even in patients with good neurological status who have survived more than 5 years. Certainly, further studies are needed to clarify this issue. Concerning the lack of response to reinstatement of treatment with TMZ in our patient, other dosing schedules that would increase the duration of exposure and/or cumulative dose of TMZ, or additional therapy such as vascular endothelial growth factor inhibiting agent, may improve the antitumor effects.^[6,14] However, the balance between the therapeutic effect of these regimens and potential drug toxicity must be carefully weighted.^[6,14]

Financial support and sponsorship

Nil.

Conflicts of interest

There are no conflicts of interest.

References

- Brandes AA, Tosoni A, Franceschi E, Sotti G, Frezza G, Amistà P, *et al.* Recurrence pattern after temozolomide concomitant with and adjuvant to radiotherapy in newly diagnosed patients with glioblastoma: Correlation with MGMT promoter methylation status. *J Clin Oncol* 2009;27:1275-9.
- Clarke JL, Ennis MM, Yung WK, Chang SM, Wen PY, Cloughesy TF, *et al.* Is surgery at progression a prognostic marker for improved 6-month progression-free survival or overall survival for patients with recurrent glioblastoma? *Neuro Oncol* 2011;13:1118-24.
- Yabroff KR, Harlan L, Zeruto C, Abrams J, Mann B. Patterns of care and survival for patients with glioblastoma multiforme diagnosed during 2006. *Neuro Oncol* 2012;14:351-9.
- Hart MG, Grant R, Garside R, Rogers G, Somerville M, Stein K. Temozolomide for high grade glioma. *Cochrane Database Syst Rev* 2008;8:CD007415.
- Hau P, Koch D, Hundsberger T, Marg E, Bauer B, Rudolph R, *et al.* Safety and feasibility of long-term temozolomide treatment in patients with high-grade glioma. *Neurology* 2007;68:688-90.
- Hottinger AF, Yoon H, DeAngelis LM, Abrey LE. Neurological outcome of long-term glioblastoma survivors. *J Neurooncol* 2009;95:301-5.
- Poelen J, Prick MJ, Jeuken JW, Wesseling P, Bernsen HJ. Six year survival after prolonged temozolomide treatment in a 30-year-old patient with glioblastoma. *Acta Neurol Belg* 2009;109:238-42.
- Ziobro M, Rolski J, Grela-Wojewoda A, Zygulska A, Niemiec M. Effects of palliative treatment with temozolomide in patients with high-grade gliomas. *Neurol Neurochir Pol* 2008;42:210-5.
- Seiz M, Krafft U, Freyschlag CF, Weiss C, Schmieder K, Lohr F, *et al.* Long-term adjuvant administration of temozolomide in patients with glioblastoma multiforme: Experience of a single institution. *J Cancer Res Clin Oncol* 2010;136:1691-5.
- Khasraw M, Bell D, Wheeler H. Long-term use of temozolomide: Could you use temozolomide safely for life in gliomas? *J Clin Neurosci* 2009;16:854-5.
- Krex D, Klink B, Hartmann C, von Deimling A, Pietsch T, Simon M, *et al.* Long-term survival with glioblastoma multiforme. *Brain* 2007;130(Pt 10):2596-606.
- Colman H, Hess KR, Turner MC, Puduvalli VK, Gilbert MR. Impact of duration of temozolomide therapy on progression-free survival in recurrent malignant glioma. *Neuro Oncol* 2002;4:368.
- Bähr O, Herrlinger U, Weller M, Steinbach JP. Very late relapses in glioblastoma long-term survivors. *J Neurol* 2009;256:1756-8.
- Wick W, Platten M, Weller M. New (alternative) temozolomide regimens for the treatment of glioma. *Neuro Oncol* 2009;11:69-79.