

Surgeon Experience of the Surgical Safety with KINEVO 900 in Vascular Neurosurgery: The Initial Experience

Sir,

Several advances have been taken place in the upgraded version of the neurosurgical microscope ZEISS KINEVO 900 (Carl Zeiss, Germany). These advances include improved intraoperative fluorescence visualization, integrated endoscopic inspection tool, improved clarity of ocular imaging, new robotic visualization platform, and three-dimensional (3D) image display on a 4K monitor which enables operating under exoscopic mode. Several novel robotic movements and control functions of the microscope will further increase the maneuverability of the visualization platform. These new features will improve the ergonomics and a greater level of intraoperative comfort, with a potential to increase the viewing quality of the neurosurgical procedures. New operational modes also allow significant impact for teaching and anatomy identification.^[1]

The authors analyzed their experience with Zeiss KINEVO 900 microscope in vascular neurosurgical procedures performed in 2019. The first main advantage of KINEVO is its surgeon-controlled robotics system. Its point lock system allows a surgeon to keep both hands at the surgical field while changing its viewing angles. It has been estimated that the surgeon spend around 40% of their times making adjustments to the microscope. The surgeon is able to electrically move all six axes of stand using a footswitch which provides three kinds of XY movements – swivel, horizontal, and point lock [Figures 1-3].

KINEVO with its position memory identified the regions of interest. With a simple push of a button, it brings us at exactly the same magnification, working distance, and focus, which was set before. It enabled active vibration

damping by providing stability and minimizing collateral system vibrations. It combines the surgeon-controlled robotics with its new navigation interface to perform automated positioning to predefined anatomical landmarks based on preoperative data planning. It approaches deep-seated pathologies in cranial surgeries.

The integrated indocyanine green (ICG) into the optics with a high-definition quality allows the dye run to be viewed directly through the microscope with the visualization of the small vessels. Cessation of blood flow in the aneurysm sac following clipping was easily visualized. Cessation of blood flow in the smaller arterial branches following aneurysm clip application can be visualized using ICG. Hence, clip adjustment can be done, and reflow in the smaller branches can be visualized using video ICG.

The new FLOW 800 has more options and graphs to analyze ICG data enabling deep diagnosis. FLOW 800 can be used to assess the magnitude of blood flow in each vessel and in the aneurysm sac. Graphical representation with color coding of the blood flow is easy to understand. Decreased or cessation of blood flow in the aneurysm sac following aneurysm clipping can be confirmed with FLOW 800. The FLOW 800 study can guide not just the competence of the arterial branches but also helps intraoperative identification of potential incomplete obliteration of the sac, thereby necessitating the need of reinforcement clips.

The new QEVO is a unique endoscopic microinspection tool. It goes beyond the straight line view of a surgical microscope. It visualizes the missing critical information behind tissue or corners. ZEISS QEVO enhances surgical visualization by complementing the microsurgical view and enabling to

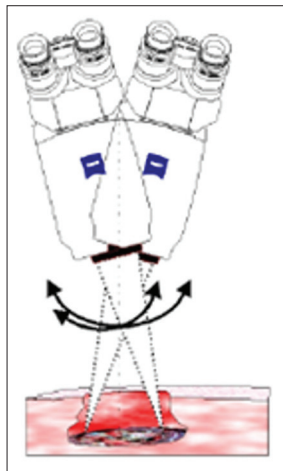


Figure 1: With swivel movement of KINEVO 900, surgeon can focus immediately to another point at same focal length

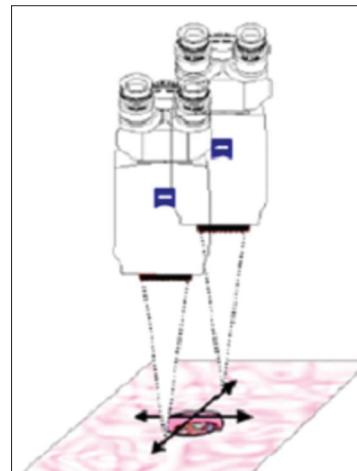


Figure 2: Horizontal movement helps in adjusting the area of interest when it goes out of field during zoom in or zoom out

look around corners. In hybrid visualization system, both exoscopic and microscopic platforms can be integrated to the neuronavigation with the possibility of mobilizing the exoscopic mode manually or robotically which allows the surgeon to select either approach based on surgical cases.

The main advantages of KINEVO 900 over Pentero 900 observed by the authors are given in Table 1.

Table 1: Advantages of KINEVO 900 over Pentero 900

	KINEVO 900	Pentero 900
Surgeon-controlled robotic visualization system	Yes	No
QEVO microinspection tool	Yes	No
Hybrid visualization system	Yes	No

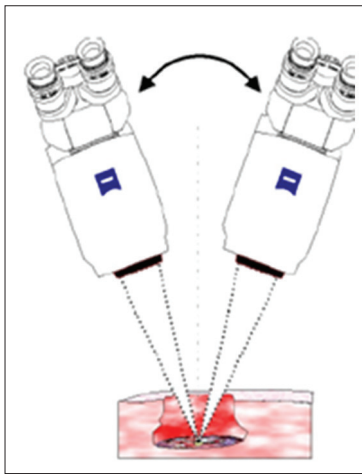


Figure 3: With point lock movement function, surgeon can change the angle of microscope with single button without changing the focused point of interest

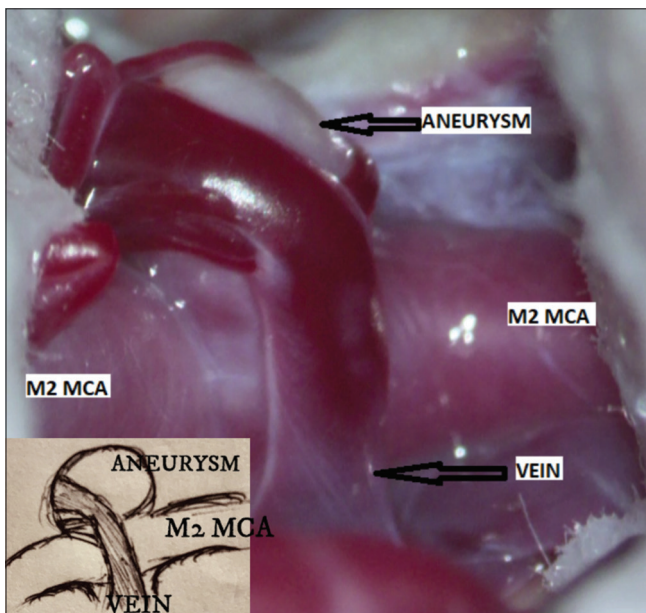


Figure 5: Intraoperative image showing middle cerebral artery bifurcation aneurysm

These are the author’s initial experience with KINEVO 900 in vascular neurosurgery. The other detailed assessments of advantages of the KINEVO 900 are not assessed by the authors.

The authors present a case of right middle cerebral artery bifurcation aneurysm [Figures 4 and 5] operated by right pterional craniotomy and clipping [Figure 6]. The FLOW 800 study was performed after ICG dye administration, pre- and post-clipping [Figures 7-9]. The FLOW 800 study guided the flow of blood in the aneurysm sac and in the surrounding arteries by graphical representation [Figure 10]. In this case, the graph of the region of interest placed on the aneurysm sac clearly denotes that the flow in the sac has been obliterated after aneurysm clipping [Figure 11].

Belykh *et al.* assessed a new robotic visualization platform with novel user-control features of ZEISS KINEVO 900 and compared its performance to the previous model of operative microscope. In a neurosurgery research laboratory, the authors performed anatomical dissections

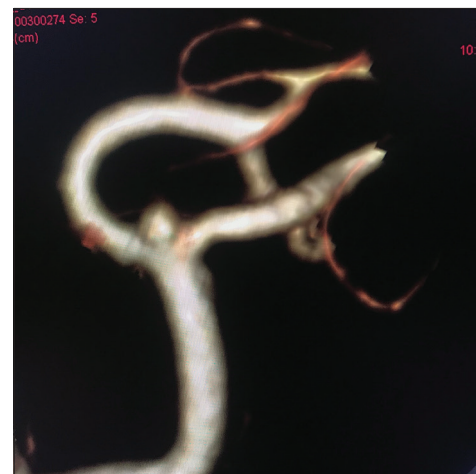


Figure 4: Computed tomography angiogram showing middle cerebral artery bifurcation aneurysm

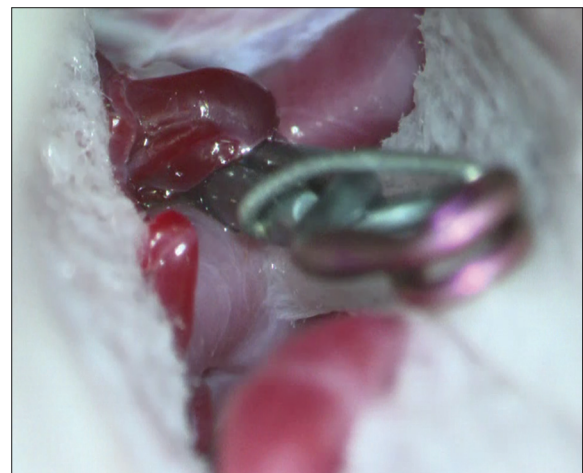


Figure 6: Clipped middle cerebral artery aneurysm noted. Vein crossing over the aneurysm also noted

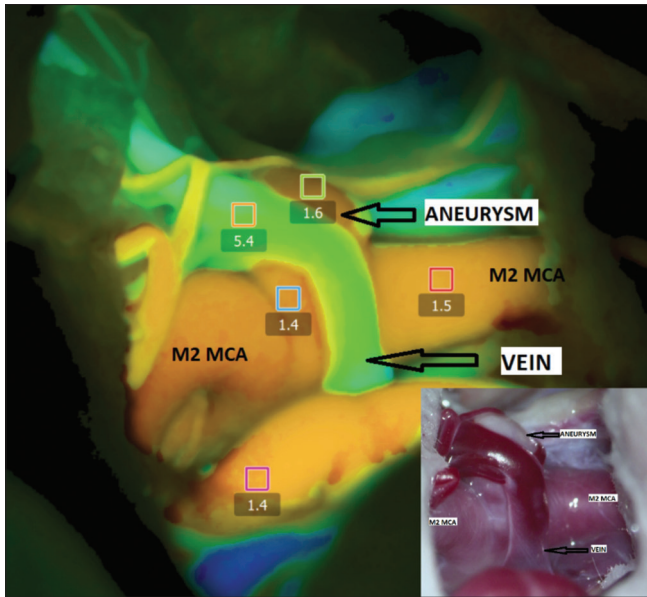


Figure 7: FLOW 800 showing increased flow of blood in the middle cerebral artery aneurysm sac (green box)

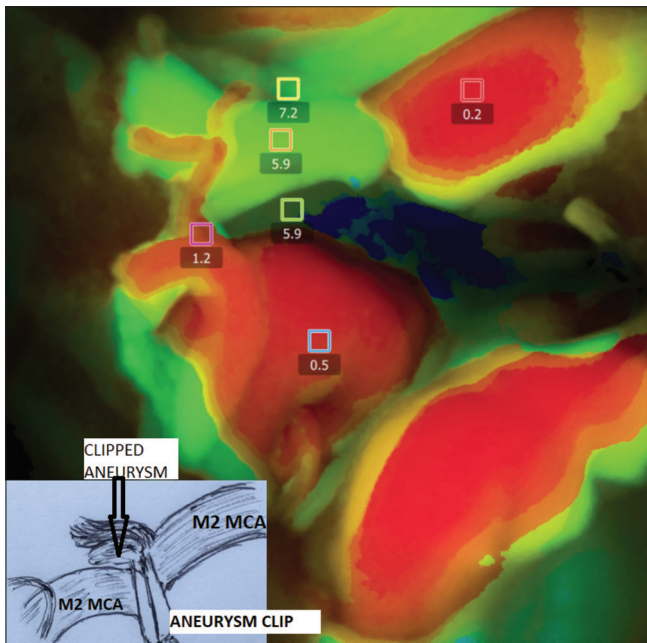


Figure 9: FLOW 800 showing obliteration of aneurysm sac (green box)

and assessed robotic, exoscopic, endoscopic, and fluorescence functionality. Usability and functionality were tested in the operating room over 1 year. The robotic microscope showed higher sensitivity for fluorescein sodium, higher detail in nonfluorescent background, and recorded/presented pictures with color quality similar to observation through the oculars. Protoporphyrin IX visualization was comparable to the previous microscope. Near-infrared ICG imaging three-step replay allowed for more convenient accurate assessment of blood flow. Point lock and pivot point functions were used in dissections to create 3D virtual reality microsurgical anatomy

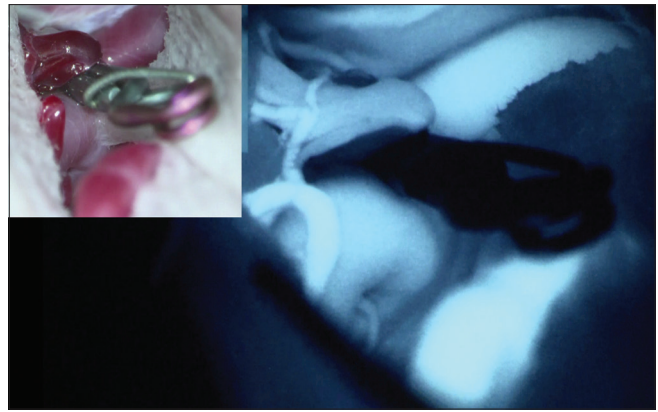


Figure 8: Indocyanine green showing clipped middle cerebral artery aneurysm

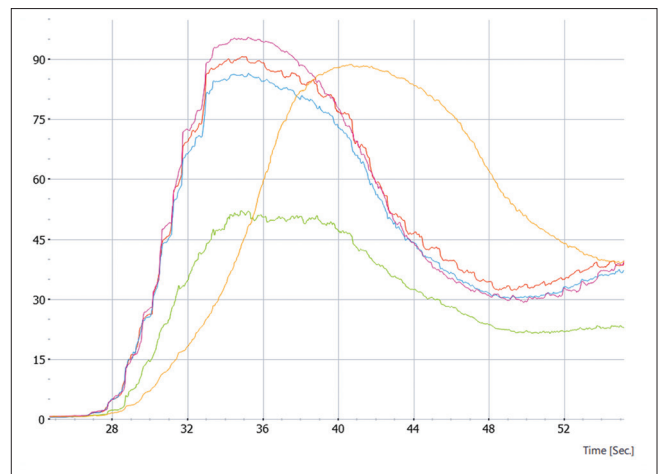


Figure 10: FLOW 800 graph showing significant blood flow in the aneurysm sac

demonstrations. Pivot point control was particularly useful in deep surgical corridors with dynamic retraction. 3D exoscopic function was successfully used in brain tumor and spine cases. Endoscopic assistance was used for around-the-corner views in minimally invasive approaches. Improvements of the robotic visualization platform include intraoperative fluorescence visualization, integrated microinspection tool, improved ocular imaging clarity, and exoscopic mode. New robotic movements positively assist the surgeon and provide improved ergonomics and a greater level of intraoperative comfort, with the potential to increase the viewing quality. New operational modes also allow significant impact for anatomy instruction. With the increasing number and complexity of functions, surgeons should receive additional training to avail themselves of the advantages of the numerous novel features.^[1]

FLOW 800 software is a proprietary technology of Carl Zeiss Meditec AG (Oberkochen, Germany) that can quantify relative fluorescence intensity under the microscope to generate color maps and intensity curves for *ad hoc* and *post hoc* analyses, respectively. The generated color maps of FLOW 800 are practical, easily interpreted

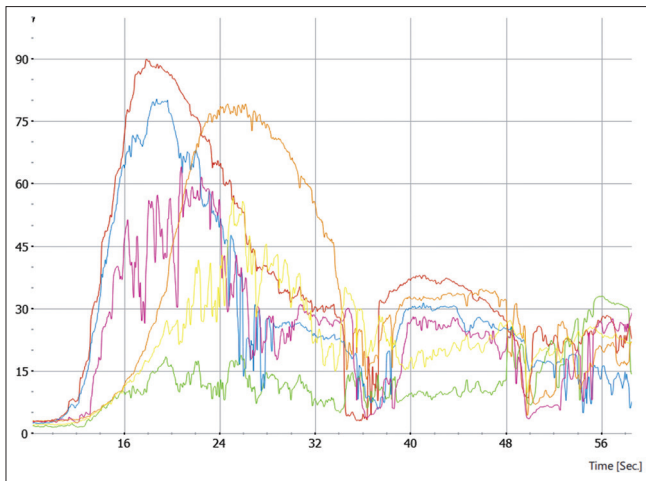


Figure 11: FLOW 800 graph showing the obliteration of the blood flow in the aneurysm sac

intraoperatively, and sufficient for guiding surgical resection in arteriovenous malformation.^[2]

Schebesch *et al.* reported their first experience in a cadaveric study and a clinical case series using the new microinspection tool QEVO that serves as a plug-in feature for the recently launched KINEVO 900 digital visualization platform (Carl Zeiss Meditec, Oberkochen, Germany). In both the cadaveric study and clinical case series, the QEVO tool was found to be beneficial in terms of high-quality visualization of fine structures and for displaying hidden anatomical details (“looking around the corner”). The handling was good, and the workflow was easy. The QEVO microinspection tool is an innovative, handheld, endoscopic tool that allows excellent additional visualization of the surgical field. In our opinion, this tool effectively enhances the modern neurosurgical armamentarium.^[3]

The authors conclude that, with advent of advanced optics and robotics, KINEVO 900 is a surgeon-friendly microscope minimizing time for small adjustments with great accuracy in visualizing the vascular structures. FLOW 800 is a special feature which gives boost to the ICG to identify partially clipped aneurysm sac and to prevent inadvertent clipping of small arterial branches. QEVO enhances surgical visualization by complementing the microsurgical view and enabling to look around corners. These advantages of KINEVO 900 lead to better surgical outcome with minimizing the intraoperative complications.

Declaration of patient consent

The authors certify that they have obtained all appropriate patient consent forms. In the form, the patient has given his/her consent for his/her images and other clinical information to be reported in the journal. The patient understands that his/her names and initials will not be published and due efforts will be made to conceal their identity, but anonymity cannot be guaranteed.

Acknowledgment

The study was done with the support from the Department of Neurosurgery, Fujita Health University Bantane Hospital, Nagoya, Aichi, Japan.

Financial support and sponsorship

Nil.

Conflicts of interest

There are no conflicts of interest.

Kazutaka Nakao¹, Binoy Damodar Thavara^{1,2}, Riki Tanaka¹, Yasuhiro Yamada¹, Girish Joshi^{1,3}, Kyosuke Miyatani¹, Tsukasa Kawase¹, Yoko Kato¹

¹Department of Neurosurgery, Fujita Health University Bantane Hospital, Nagoya, Aichi, Japan, ²Department of Neurosurgery, Government Medical College, Thrissur, Kerala, ³Department of Neurosurgery, Apollo Speciality Hospital, Bengaluru, Karnataka, India

Address for correspondence:

Dr. Kazutaka Nakao,
Department of Neurosurgery, Fujita Health University Bantane hospital,
Nagoya, Aichi, Japan.
Email: k_nakao_0920@yahoo.co.jp

References

1. Belykh EG, Zhao X, Cavallo C, Bohl MA, Yagmurlu K, Aklinski JL, *et al.* Laboratory evaluation of a robotic operative microscope: Visualization platform for neurosurgery. *Cureus* 2018;10:e3072.
2. Foster CH, Morone PJ, Tomlinson SB, Cohen-Gadol AA. Application of indocyanine green during arteriovenous malformation surgery: evidence, techniques, and practical pearls. *Front Surg* 2019;6:70.
3. Schebesch KM, Brawanski A, Tamm ER, Kühnel TS, Höhne J. QEVO® - A new digital endoscopic microinspection tool - A cadaveric study and first clinical experiences (case series). *Surg Neurol Int* 2019;10:46.

This is an open access journal, and articles are distributed under the terms of the Creative Commons Attribution-NonCommercial-ShareAlike 4.0 License, which allows others to remix, tweak, and build upon the work non-commercially, as long as appropriate credit is given and the new creations are licensed under the identical terms.

Access this article online	
Quick Response Code: 	Website: www.asianjns.org
	DOI: 10.4103/ajns.AJNS_40_20

How to cite this article: Nakao K, Thavara BD, Tanaka R, Yamada Y, Joshi G, Miyatani K, *et al.* Surgeon experience of the surgical safety with kinevo 900 in vascular neurosurgery: The initial experience. *Asian J Neurosurg* 2020;15:464-7.

Submitted: 03-Feb-2020

Revised: 18-Mar-2020

Accepted: 26-Mar-2020

Published: 29-May-2020

© 2020 Asian Journal of Neurosurgery | Published by Wolters Kluwer - Medknow