

The Use of Fusion Images as a Diagnostic and Neurosurgical Planning Tool in Microvascular Decompression

Abstract

Preoperative assessment of surgery using high-quality images can help surgeons to achieve best result of treatment. With the advances in computer technology, interactive multimodality fusion images have been developed. The use of fusion images as a preoperative planning tool is described with its examples in illustrative cases of trigeminal neuralgia and hemifacial spasm microvascular decompression (MVD). Interactive computer graphics such as multimodality fusion method is a useful tool to preoperatively predict the need of bone exposure and configuration of blood vessels with its correlation to cranial nerves in MVD.

Keyword: Fusion images, microvascular decompression, preoperative planning

Introduction

The advancement of science in the field of medical imaging up to this day has been tremendously fast. From the use of X-rays up to interactive fusion of images with the help of computer innovations, medical imaging has been giving a great support to medical service. Preoperative assessment of surgery using high-quality images can help surgeons to achieve best result of treatment. On this paper, the role of fusion images in the microvascular decompression (MVD) of cranial nerves is described.

Trigeminal Neuralgia

Trigeminal neuralgia is a syndrome of neuropathic pain, considered a debilitating condition, often described as “a fate worse than death.”^[1] This condition is characterized by sudden, usually unilateral, severe paroxysmal lancinating pain in trigeminal nerve distribution. Trigeminal neuralgia has been described in detail in 1773 by Fothergill^[2] and is classified into classic and symptomatic (or secondary). It is considered a rare condition with an annual incidence of 5.7/100,000 in women and 2.5/100,000 in men with a peak incidence in the fifth and sixth decades of life.^[3]

The etiology of trigeminal neuralgia is an abnormal conduction within the

trigeminal nerve. At the point just before where the trigeminal nerve enters the brainstem, a short segment of axons is unmyelinated by myelin produced by oligodendrocytes. After a few millimeters, there is a transition area from centrally myelinated to peripherally myelinated axons (produced by Schwann cells), called Obersteiner–Redlich zone or the dorsal root entry zone. Pulsatile mechanical microtrauma, caused by veins or arteries, to this zone can lead to myelin changes causing abnormal conduction of nerves (ectopic impulse discharge, triggered after discharge, and cross-excitation), which related to clinical symptoms of trigeminal neuralgia. The ultrastructural changes can be seen intraoperatively as an indentation and discoloration.^[4]

Trigeminal neuralgia has a differential diagnosis of other facial pain pathologies, such as postherpetic neuralgia, trigeminal neuropathic pain, multiple sclerosis, teeth and jaw problems, sinusitis, glaucoma, optic neuritis, migraine, cluster headache, and psychogenic. It is important to distinguish the type of pain, whether it is nociceptive or neuropathic pain, to establish the diagnosis of trigeminal neuralgia.

The treatment for trigeminal neuralgia can be classified into medication management (the

Thomas Tommy, Ittichai Sakarunchai¹, Yasuhiro Yamada², Koichiro Yoshida², Tsukasa Kawase², Yoko Kato²

Department of Neurosurgery, Universitas Pelita Harapan, Tangerang, Indonesia,

¹Department of Surgery,

Division of Neurosurgery,

Prince of Songkla University,

Songkla, Thailand, ²Department

of Neurosurgery, Banbuntane

Hotokukai Hospital, Fujita

Health University, Nagoya,

Japan

Address for correspondence:

Dr. Thomas Tommy,

Jalan Julang 2 No. 8, Kota

Bogor, Jawa Barat, Indonesia.

E-mail: thomastommy.

neurosurg@gmail.com

Access this article online

Website: www.asianjns.org

DOI: 10.4103/ajns.AJNS_413_20

Quick Response Code:



This is an open access journal, and articles are distributed under the terms of the Creative Commons Attribution-NonCommercial-ShareAlike 4.0 License, which allows others to remix, tweak, and build upon the work non-commercially, as long as appropriate credit is given and the new creations are licensed under the identical terms.

For reprints contact: WKHLRPMedknow_reprints@wolterskluwer.com

How to cite this article: Tommy T, Sakarunchai I, Yamada Y, Yoshida K, Kawase T, Kato Y. The use of fusion images as a diagnostic and neurosurgical planning tool in microvascular decompression. *Asian J Neurosurg* 2021;16:562-6.

Submitted: 01-Sep-2020

Revised: 07-Oct-2020

Accepted: 15-Feb-2021

Published: 14-Sep-2021

initial treatment) and surgical management. Carbamazepine is the drug of choice in the treatment of trigeminal neuralgia with drowsiness, dizziness, constipation, ataxia, and syndrome of inappropriate diuretic hormone as its side effects. Other medications agents can be used are oxcarbazepine, gabapentin, lamotrigine, phenytoin, and baclofen. If the clinical condition does not respond with medication or there are severe side effects that cannot be tolerated by patient, surgical management may be advised.

The surgical management is classified into postganglionic and preganglionic surgery. Postganglionic surgery, which is usually done in a percutaneous way, consists of various techniques: radiofrequency rhizotomy, glycerol rhizotomy, and balloon compression. Although there is some evidence regarding the efficacy of those techniques, postganglionic surgery has high incidence of facial sensory loss and motor weakness. Preganglionic surgery for trigeminal neuralgia is known as MVD. MVD was first performed by W. James Gardner in 1950 and subsequently refined and popularized by P. Janneta. MVD is a well-known effective modality to treat trigeminal neuralgia.^[5-7]

Hemifacial Spasm

Hemifacial spasm is an uncommon disorder. Patients usually presented with involuntary paroxysmal movement of ipsilateral face. This disorder is also considered caused by the compression of facial nerve or secondarily by brainstem damage^[8] by vascular structure at the root exit zone (RExZ), which can be relieved by repositioning of the offending vascular structure, which is primarily related to arterial compression (posterior inferior cerebellar artery, anterior inferior cerebellar artery [AICA], or vertebralbasilar artery).^[9] Hemifacial spasm has the same pathophysiology with trigeminal neuralgia but has a difference in the position of lesion. For hemifacial spasm, the place of neurovascular contact is on the RExZ. Contacts that are not at the RExZ are considered irrelevant to the hard flaccid syndrome.^[10]

This disorder has a prevalence of around 10/100,000 in the total population, and the true number might be higher caused by underdiagnosis, misdiagnosis, and absence of population-based data.^[11] Hemifacial spasm has differential diagnosis of facial tic, ocular myokymia, and blepharospasm.^[11]

The treatments of hemifacial spasm are medications and local administration of botulinum toxin into the involved facial muscles and surgery. Botulinum toxin can be used as it offers an alternative treatment to surgical therapy,^[12] but this drug has its limitations as it needs to be repeated every 3–6 months causing high economic cost.^[11] MVD for hemifacial spasm caused by ectatic vertebral artery compressing the facial nerve can be treated by vertebral artery pexy technique (suturing the superficial vessel wall to dura).^[13] MVD is an effective modality to treat hemifacial spasm^[6,7] and can be considered as a cure.^[9]

Methods

The fusion images technique was done and the images were acquired from all patients who were operated in Fujita Health University – Banbuntane Hotokukai Hospital, Japan. Fusion images were made and acquired in Imai Clinic, Nagoya, Japan. To acquire fusion images, in our institution, patients have to had brain magnetic resonance imaging (MRI) (Phillips Intera[®], 1.5 Tesla) and computed tomography (CT) angiography (Philips Brilliance[®] 64 slices), and then the data in Digital Imaging and Communications in Medicine are fused in a workstation (Fujifilm[®] Vincent[®] Ver. 3.0) [Figure 1]. The use of fusion images was described in illustrative cases.

Operative Technique

Under general anesthesia, a left park bench position and suboccipital retrosigmoid approach is used. The need of head rotation depends on which cranial nerve need to be approached. For approaching a trigeminal nerve or vestibulocochlear complex, the vertex is kept in parallel to the floor. For approaching facial nerve or lower cranial nerves, the vertex is dropped 15° toward the floor as mentioned by McLaughlin *et al.*^[14] The head is fixed with head frame and pins. In our institution, a curvilinear incision is used starting from 1 cm behind hairline extending to three fingerbreadths medial from mastoid notch and ends at paramedian line just at the hairline.

A 3 cm × 3 cm craniectomy or craniotomy should be done exposing the transverse sinus, sigmoid-transverse junction, sigmoid sinus, and pars squamosal of the occipital bone. All bleeding should be controlled using coagulation, bone wax, or hemostatic agents because it will make further procedure difficult. Dura is opened in a Y-shaped fashion to protect sinus.

The first step after opening dura is to slightly retract cerebellum and open the cisterna magna to let cerebrospinal fluid (CSF) egress slowly. Dissection then can be continued laterally following the arachnoid and identify lower cranial nerves that runs to jugular foramen. Depends on the location of lesion, further dissection can be continued to identifying cranial nerve (CN) VII and CN VIII that runs to internal acoustic meatus, and CN V can be identified by its course supero-antero-lateral to the Meckel's cave. Frequently, indentation of offending vessel can be seen on the cranial nerves. The configuration of the offending vessel can be imagined and a pre-planned surgical approach using multimodal fusion images. MVD can be done in interposition or transposition fashion. In interposition, Teflon pledgets are used to hinder the cranial nerve from vascular structures. Vascular patency after placement of Teflon pledgets is confirmed using ICG and endoscope. Dura is closed in watertight fashion, bone flap replaced and fixated, and skin closed with subcutaneous sutures and stapled.

Illustrative Cases

Case 1

A 50-year-old male consulted from a pain clinic with V2/V3 trigeminal neuralgia. The patient had taken carbamazepine and pregabalin for around 3 years and could not bear the side effects of medication. Three-dimensional (3D) CT reconstruction [Figure 2] had been done and showed SCA and AICA as the possible offending vessels. MVD of the CN V was indicated.

Case 2

A 42-year-old male presented with a history of hemifacial spasm for about 20 years. The patient had not taken any management of hemifacial spasm, medication, or surgery before he agreed to undergo surgery. Contact of AICA to the facial nerve was found on the preoperative assessment using fusion images [Figure 3].

Case 3

A 57-year-old male consulted from pain clinic with V3 trigeminal neuralgia and hemifacial spasm for about 4 years. The patient still had the symptoms although he had taken carbamazepine 1200 mg and gabapentine 600 mg daily. There was a history of botulinum toxin administration. A dolichoectasia of vertebral arteries was found and showed compression of the left 5th and 7th cranial nerve [Figure 4]. MVD of the CN V was indicated.

Discussion

From the early days when X-rays was founded by Wilhelm Rontgen, and used in the field of medicine, in 1895,^[15] the publication of axial CT scans by Hounsfield,^[16] MRI machine by Lauterbur in around 1973,^[17] and the

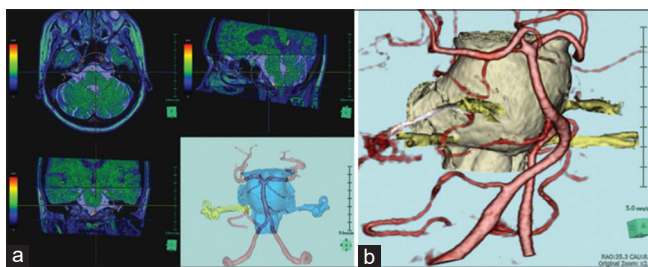


Figure 1: (a) Workstation display on fusing magnetic resonance imaging and computed tomographic angiogram images. (b) The result of fusion




Figure 3: (a) General overview of the relation of brainstem, 7th and 8th cranial nerve complex and neurovascular structures. An elongated anterior inferior cerebellar artery and its loop contacted the 7th and 8th cranial nerve complex can be seen. (b) Image rotation to evaluate surgical view. (c) Surgical view

introduction of computer-assisted diagnosis in the 1980s,^[18] imaging technology has extensively developed. Recently, the idea of interactive visualization using multimodal fusion images, a branch of computer science, is still being studied and tuned in search of new modality in medical imaging.^[19] 3D images from multiple modalities used in interactive visualization provide spatial information that would be useful in the management of patients, especially in the field of surgery where preoperative planning is very important to understand any encountered important structures even before making the incision.

The principle of MVD was first described by Dandy,^[20] and further popularized by Jannetta^[21] as an effective form of treatment in the cranial nerve. Evidence suggests that MVD is the best surgical modality which is effective, low recurrence rate, and nondestructive for the treatment microvascular compression.^[5] Reports have shown that MVD is useful in the treatment of microvascular compression of the optic chiasm,^[22-25] abducens nerve,^[26] glossopharyngeal neuralgia,^[27,28] positional vertigo,^[29] cochlear nerve syndrome,^[30] hemifacial spasm,^[6,7] intractable singultus,^[31] and vascular compression to lower cranial nerves.^[32]

The process of visualization by fusing multiple modalities images is named interactive computer graphics or fusion images.^[19] This technique has been used in the

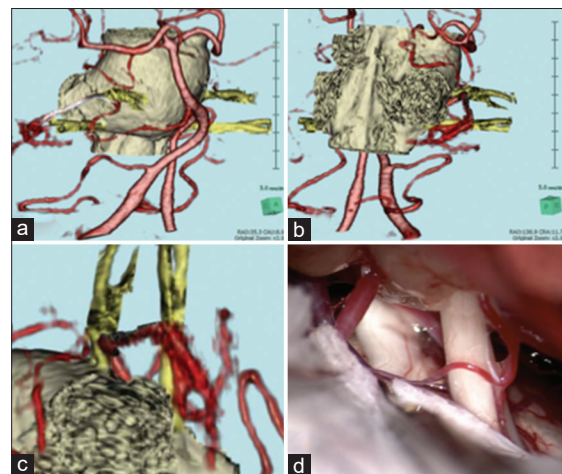


Figure 2: Fusion images, (a) Anterior view; (b) Posterior view. A compression of cranial nerves by dolichoectatic vertebral arteries can be seen in detail by using fusion images. (c) Preoperative orientation from the image was useful to predict the operative view as seen on (d)

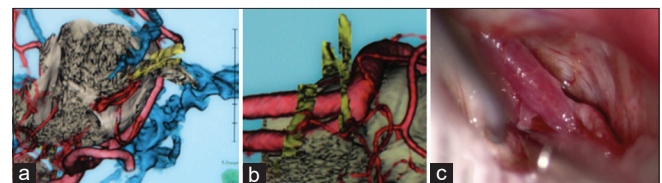


Figure 4: (a) Fusion image of the case. Compression of 5th and 7th cranial nerves by dolichoectatic vertebral artery can be seen. (b) Operative view of the fusion image can identify the configuration of neurovascular structures encountered during surgery (c)

treatment of trigeminal neuralgia,^[33] brainstem cavernous malformations,^[19] spinal lipoma, or tethered spinal cord.^[34] The usefulness of interactive computer graphics has been discussed in this paper with its association with MVD of cranial nerves. By using this technique, one can make diagnosis, hazards and landmark identification, and preoperative surgical planning.

Fusion images technique is also beneficial in other fields of surgery. The idea of using multimodality images and fusing them into one could be used for navigation in tumor surgery (tumor removal, stereotactic biopsy, and identification of important structures surrounding the resection area) and reconstructive surgery. This technique could also be used as a postoperative evaluation. By using volumetric rendering, one could evaluate whether surgery has successfully decompressed a nerve (in MVD), percentage of tumor removal, and results of reconstructive surgery.

Conclusion

Interactive computer graphics using multimodality fusion method is a useful tool to preoperatively predict the need of bone exposure and configuration of blood vessels with its correlation to cranial nerves in MVD.

Financial support and sponsorship

Nil.

Conflicts of interest

There are no conflicts of interest.

References

1. Sekula RF, Marchan EM, Fletcher LH, Casey KF, Jannetta PJ. Microvascular decompression for trigeminal neuralgia in elderly patients. *J Neurosurg* 2008;108:689-91.
2. Fothergill J. On a painful affliction of the face. *Med Observ Inquir* 1773;5:129-42.
3. Mathews MS, Binder DK, Linskey ME. Trigeminal neuralgia: Diagnosis and nonoperative management. In: Winn HR, editor. *Youmans Neurological Surgery*. Philadelphia: Elsevier; 2011. p. 1776-80.
4. Devor M, Govrin-Lippmann R, Rappaport ZH. Mechanism of trigeminal neuralgia: An ultrastructural analysis of trigeminal root specimens obtained during microvascular decompression surgery. *J Neurosurg* 2002;96:532-43.
5. Ashkan K, Marsh H. Microvascular decompression for trigeminal neuralgia in the elderly: A review of the safety and efficacy. *Neurosurgery* 2004;55:840-8.
6. Barker FG 2nd, Jannetta PJ, Bissonette DJ, Shields PT, Larkins MV, Jho HD. Microvascular decompression for hemifacial spasm. *J Neurosurg* 1995;82:201-10.
7. Barker FG 2nd, Jannetta PJ, Bissonette DJ, Larkins MV, Jho HD. The long-term outcome of microvascular decompression for trigeminal neuralgia. *N Eng J Med* 1996;334:1077-83.
8. Abbruzzese G, Berardelli A, Defazio G. Hemifacial spasm. *Handb Clin Neurol* 2011;100:675-80.
9. Sindou MP. Microvascular decompression for primary hemifacial spasm. Importance of intraoperative neurophysiological monitoring. *Acta Neurochir (Wien)* 2005;147:1019-26.
10. Naraghi R, Tanrikulu L, Troesch-Weber R, Bischoff B, Hecht M, Buchfelder M, *et al.* Classification of neurovascular compression in typical hemifacial spasm: Three-dimensional visualization of the facial and the vestibulocochlear nerves. *J Neurosurg* 2007;107:1154-63.
11. Kong DS, Park K. Hemifacial spasm: A neurosurgical perspective. *J Korean Neurosurg Soc* 2007;42:355-62.
12. Jankovic J, Brin MF. Drug therapy: Therapeutic uses of botulinum toxin. *N Eng J Med* 1991;324:1186-94.
13. Ferreira M, Walcott BP, Nahed BV, Sekhar LN. Vertebral artery pexy for microvascular decompression of the facial nerve in the treatment of hemifacial spasm. *J Neurosurg* 2011;114:1800-4.
14. McLaughlin MR, Jannetta PJ, Clyde BL, Subach BR, Comey CH, Resnick DK. Microvascular decompression of cranial nerves: Lesson learned after 4400 operations. *J Neurosurg* 1999;90:1-8.
15. Spiegel PK. The first clinical X-ray made in America – 100 years. *AJR Am J Roentgenol* 1995;164:241-3.
16. Hounsfield GN. Computerised transverse axial scanning (tomography): Part 1. Description of system. *BJR* 1973;46:1016-22.
17. Lauterbur PC. Image formation by induced local interactions: Examples of employing nuclear magnetic resonance. *Nature* 1973;242:190.
18. Doi K. Computer-aided diagnosis in medical imaging: Historical review, current status and future potential. *Comput Med Imaging Graph* 2007;31:198-211.
19. Kin T, Nakatomi H, Shojima M, Tanaka M, Ino K, Mori H, *et al.* A new strategic neurosurgical planning tool for brainstem cavernous malformations using interactive computer graphics with multimodal fusion images. *J Neurosurg* 2012;117:78-88.
20. Dandy WE. *Surgery of the brain*. In: Lewis D, editor. *Practice of Surgery*. Hagerstown: WF Prior; 1945. p. 177-200.
21. Jannetta PJ. Treatment of trigeminal neuralgia by suboccipital and transtentorial cranial operations. *Clin Neurosurg* 1977;24:538-49.
22. McLaughlin N, Bojanowski MW. Microvascular decompression of the optic chiasm. Case report. *J Neurosurg* 2011;114:857-60.
23. Rivet DJ, Dacey RG. Visual loss from a dolichoectatic anterior cerebral artery. Case illustration. *J Neurosurg* 2005;102:576.
24. Rafael H. Optic nerve compression by a dolichoectatic internal carotid artery: Case report. *Neurosurgery* 1998;42:1196-7.
25. Sacks JG, Lindenburg R. Dolichoectatic intracranial arteries: Symptomatology and pathogenesis of arterial elongation and distention. *Johns Hopkins Med J* 1969;125:95-106.
26. De Ridder D, Menovsky T. Neurovascular compression of the abducent nerve causing abducent palsy treated by microvascular decompression. Case report. *J Neurosurg* 2007;107:1231-4.
27. Rey-Dios R, Cohen-Gadol AA. Current neurosurgical management of glossopharyngeal neuralgia and technical nuances for microvascular decompression surgery. *Neurosurg Focus* 2013;34:E8.
28. Kondo A. Follow-up results of using microvascular decompression for treatment of glossopharyngeal neuralgia. *J Neurosurg* 1998;88:221-5.
29. Jannetta PJ, Moller MB, Moller AR. Disabling positional vertigo. *N Eng J Med* 1984;310:1700-5.
30. Okamura T, Kurokawa Y, Ikeda N, Abiko S, Ideguchi M, Watanabe K, *et al.* Microvascular decompression for cochlear symptoms. *J Neurosurg* 2000;93:421-6.
31. Farin A, Chakrabarti I, Giannotta SL, Vaynman S, Samudrala S. Microvascular decompression for intractable singultus: Technical case report. *Neurosurgery* 2008;62:E1180-1.

32. Resnick DK, Jannetta PJ. Hyperactive rhizopathy of the vagus nerve and microvascular decompression. Case report. *J Neurosurg* 1999;90:580-2.
33. Miller J, Acar F, Hamilton B, Burchiel K. Preoperative visualization of neurovascular anatomy in trigeminal neuralgia. *J Neurosurg* 108: 477-482, 2008.
34. Bamba Y, Nonaka M, Nakajima S, Yamasaki M. Three-dimensional reconstructed computed tomography - Magnetic resonance fusion image - Based preoperative planning for surgical procedures for spinal lipoma or tethered spinal cord after myelomeningocele repair. *Neurol Med Chir (Tokyo)* 2011;51:397-402.