

A Rare Combined Trigeminal Neuralgia with Hemifacial Spasm in a 78-year-old Male Patient

Abstract

This case reported a 78-year-old male patient presented with combined trigeminal neuralgia and hemifacial spasm, which is a rare finding and seldom addressed. Magnetic resonance imaging examination showed compression of right N.V by the right superior cerebellar artery (SCA) but did not prove any compression on the right N.VII. This patient is treated with microvascular decompression, and we found out compression of right N.V by right SCA and N.VII from the right anterior inferior cerebellar artery. Postoperatively, the symptoms were resolved with transient hypoesthesia and no recurrence after 1-year follow-up.

Keywords: Hemifacial spasm, hyperactive dysfunction syndrome, microvascular decompression, trigeminal neuralgia

**Donny Argie,
Christopher Lauren,
Elric Brahm Malelak**

*Department of Neurosurgery,
Prof. Dr. W.Z. Johannes Kupang
Regional General Hospital,
Kupang, East Nusa Tenggara,
Indonesia*

Introduction

Combined trigeminal neuralgia (TN) with hemifacial spasm (HFS) is a variant of combined cranial nerve hyperactive dysfunction syndrome (HDS), which is caused by vascular compression on the cranial nerve root entry zone. Combined cranial nerve HDS is a rare condition and comprised only 3% of reported HDS patients. Combined TN and HFS of cranial nerve HDS ranging from 7.3% (3 of 41 combined HDS cases), 13.5% (5 of 37 combined HDS cases), 27.4% (14 of 51 combined HDS cases), and 31.8% (14 of 44 combined HDS cases) based on some reported studies.^[1-4]

We report a case of a 78-year-old male patient that suffered from combined TN and HFS. We provided detailed descriptions of the patient clinical history, physical and supportive examination, surgical procedure, follow-up, and discussion based on some reported studies and literature.

Case Report

A 78-year-old male patient presented with a primary chief complaint of pain over the right half of his face, especially the right forehead and upper cheek, since 2014. When the patient wraps his right face, the pain was triggered by the gusts of wind,

and triggered simultaneously when the patient does nothing. This pain has a characteristic of stabbing-like pain that lasts about 1 min, which occurs about three times a day with a frequency of more or <6 days a week. He already takes a combination of anticonvulsants for about 5 years, but the pain does not decrease. He took carbamazepine for the first time in 2014 with a dose of 100 mg twice a day for 3 years, but the intensity and duration of pain do not decrease. Later, he takes a combination of carbamazepine with gabapentin 300 mg twice a day for about 2 years, but the medications do not be effective anymore. The patient also complains of a twitching over the right eyelid and forehead 3 years prior. For a month, the frequency is about seven times a week. The patient and his family had noticed that the twitching on the right eyelid and forehead persists even when he fell asleep. The patient does not complain about weakness on the right side face, decreased hearing, dizziness, or loss of balance.

The patient's visual analog scale is eight, the Barrow Neurological Institute (BNI) Pain Intensity Scale is 4, and the physical examination had revealed increased sensitivity to light touch over the right

Address for correspondence:

*Dr. Christopher Lauren,
Jl. Prof Johannes No. 14,
Oetete, Kupang, Nusa
Tenggara Timur, Indonesia.
E-mail: chrislauren11@gmail.
com*

Access this article online

Website: www.asianjns.org

DOI: 10.4103/ajns.AJNS_433_20

Quick Response Code:



How to cite this article: Argie D, Lauren C, Malelak EB. A rare combined trigeminal neuralgia with hemifacial spasm in a 78-year-old male patient. *Asian J Neurosurg* 2021;16:630-3.

Submitted: 15-Sep-2020

Revised: 25-Nov-2020

Accepted: 15-Apr-2021

Published: 14-Sep-2021

This is an open access journal, and articles are distributed under the terms of the Creative Commons Attribution-NonCommercial-ShareAlike 4.0 License, which allows others to remix, tweak, and build upon the work non-commercially, as long as appropriate credit is given and the new creations are licensed under the identical terms.

For reprints contact: WKHLRPMedknow_reprints@wolterskluwer.com

side face innervated by the ophthalmic and maxillary distribution of the N.V. No abnormalities found over the mandibular distribution of the right N.V. There are no abnormalities found in the examination of facial nerve (N.VII), vestibulocochlear nerve (N.VIII), and the other cranial nerves. The noncontrast T1 and T2 magnetic resonance imaging (MRI) showed a neurovascular contact of the right superior cerebellar artery (SCA) with the right N.V root entry zone [Figure 1]. There is no compression found over the N.VII structure.

The patient was considered to take a surgical procedure to release the neurovascular contact. Before we performed the procedure, the patient was informed about the surgery step-by-step, advantages, side effects, and complications that may be developed during and after the surgery, especially in elderly populations. This procedure was done in a retrosigmoid approach that bordered by transverse sinus superiorly and the sigmoid sinus laterally. The cerebellar hemisphere is retracted, and the arachnoid membrane is dissected. The N.VII and N.VIII complex is encountered from the root entry zone until the distal part enters the meatus. Anterior inferior cerebellar artery (AICA) compresses this structure along the lateral side of the N.VII/VIII complex [Figure 2a]. A shredded Teflon implant is interposed between the AICA and VII/VIII complex [Figure 2b]. The operation moved into the right N.V structure. The adjacent vascular and arachnoid membrane is dissected off, and the N.V is seen clearly from the root entry zone to the distal part. The SCA is seen and compresses the axillar side of the N.V [Figure 2c]. The shredded Teflon implant is interposed between the N.V and SCA complex [Figure 2d].

This patient is observed overnight in the intensive care unit (ICU) and given intravenous (IV) ceftriaxone 2 × 1 g; IV omeprazole 2 × 40 mg; IV ketorolac 2 × 30 mg; IV plasminex 3 × 500 mg; IV Vitamin K 3 × 40 mcg; and IV dexamethasone 3 × 5 mg. He does not complain of any pain and spasm after the operation, so the postoperative BNI pain intensity scale in this patient is one and it is considered a satisfactory outcome. He had a mild complication such as hypoesthesia over the right-half face that resolved until postoperative day 3. The patient does

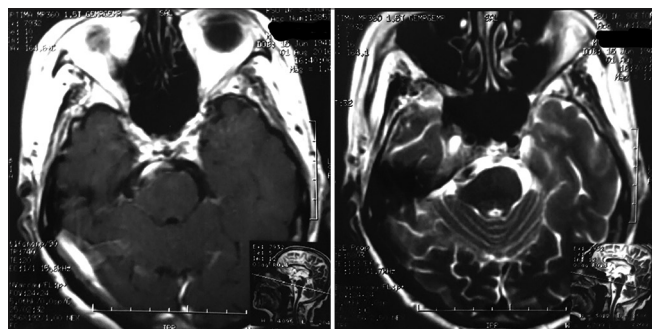


Figure 1: Noncontrast T1 and T2 magnetic resonance imaging

not complain of any dizziness, nausea, decreased hearing, and paralyzed over the right half face. After the patient is stabilized and the hypoesthesia is resolved, the patient is discharged on postoperative day 4. There is no recurrence in pain and spasm after 1-year follow-up in this patient.

Discussion

Cranial nerve HDS is a condition caused by vascular compression of the cranial nerve root entry zone, such as TN, HFS, and glossopharyngeal neuralgia. A combined variant of cranial nerve HDS is rare and seldom addressed, which only comprises 3% of reported HDS patients. We found some studies that report the number of cases of combined cranial nerve HDS in several institutions. [1] Cao *et al.* series reported 44 (3.03%) combined HDS cases in 1450 patients with HDS, including combined TN and HFS in 14 cases. [2] Kobata *et al.* also reported a combined HDS in 41 (2.8%) cases in a total of 1472 HDS patients who suffered from HDS and only 3 patients presented with combined TN and HFS. [3] Yang *et al.* reported a series of combined HDS in 51 (2.97%) cases in a total of 1720 HDS patients, with combined TN and HFS only represented in 14 cases. [4] Zhang *et al.* also reported 37 (2.9%) patients suffered from combined HDS in a total of 1275 HDS patients, which included 5 patients with combined TN and HFS. Taking all the reported studies together, combined TN and HFS of cranial nerve HDS ranging from 7.3% (3 of 41 combined HDS cases), 13.5% (5 of 37 combined HDS cases), 27.4% (14 of 51 combined HDS cases), and 31.8% (14 of 44 combined HDS cases). [1-4]

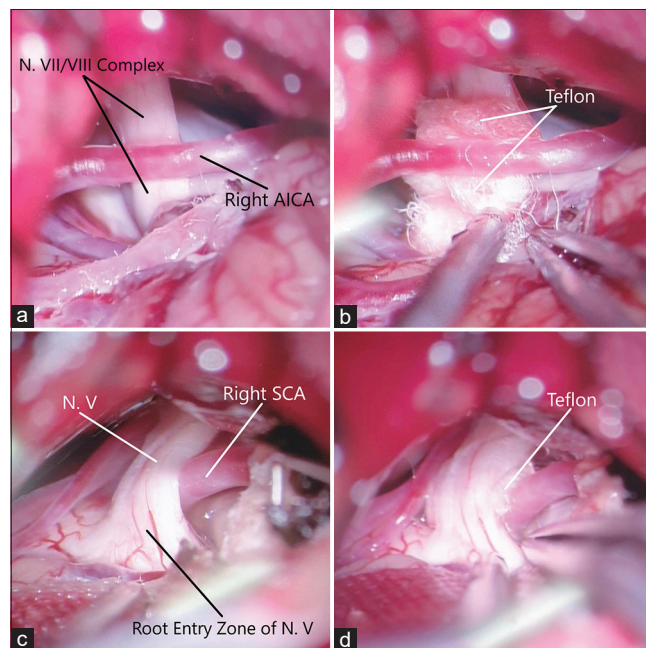


Figure 2: Intraoperative approach to the neurovascular contact site. (a) N.VII/VIII compression by right AICA. (b) Decompression with Teflon implant. (c) N.V compression by right SCA and (d) Decompression with Teflon implant. N – Nerve; V – Trigeminal; VI – Facial; VIII – Vestibulocochlear; SCA – Superior cerebellar artery; AICA – Anterior inferior cerebellar artery

Combined HDS has been reported to associate with aging, hypertension, and female gender. Progressive atherosclerotic vascular changes in an elderly patient have to lead to elongation of the vessels and contact the nearby nerve structures. This condition occurs more frequently if associated with hypertension.^[1-4] In this case, the patient has an aging factor as the only condition that has been associated with a higher risk of developing a combined HDS.

MRI is one of the supportive examinations that have been used widely to diagnosing a TN. Three-dimensional constructive interference in steady-state (3D-CISS) MRI is a novel imaging modality that is more superior and advanced in searching for possible etiology and preoperative planning of a TN, whom neurovascular compression is the most frequently founded, than a conventional MRI.^[5] In this case, we could not perform a 3D-CISS MRI because of the patient's will due to the higher cost of this examination than the conventional one. Although MRI is thought to be superior in searching for an underlying neurovascular compression in TN, it still should be viewed as supportive rather than diagnostic.^[6,7] The MRI in this patient shows that the N.V is compressed by an adjacent vascular structure but does not prove any compression along the N.VII. Geneidi *et al.* reported that MRI could depict the etiology in 25 of 45 patients with TN, but not in the other 20 patients.^[6] In Hitchon *et al.* series of 51 patients with TN and 12 with HFS, the MRI shows a compressed nerve that was congruent with the operative findings in 84% of patients with TN and 75% in HFS.^[7] Thereby, the diagnostic of TN and HFS should be based on clinical diagnosis and not by visualization of a compressing vessel by MRI.^[6,7]

We considered doing a microvascular decompression (MVD) procedure because of the better outcome in relieving the symptoms, lower complication, and it is suitable for an elderly patient, especially without a comorbid condition, with the same outcome as a younger patient.^[1,2,8-12] Most reported studies and literature had shown a satisfactory outcome, low complication, and low recurrence rate with this procedure in all age groups.^[1,2,4,13-15] Some complications from MVD have been reported and the most common is transient hypoesthesia, followed by hearing loss, facial palsy, cerebellar hematoma, supratentorial subdural hemorrhage, cerebrospinal fluid leak, and meningitis.^[16-19] In this case, this patient only suffered postoperative transient hypoesthesia over the right half of the face and resolved spontaneously in postoperative day 3.

Declaration of patient consent

The authors certify that they have obtained all appropriate patient consent forms. In the form, the patient has given his consent for his images and other clinical information to be reported in the journal. The patient understands that name and initials will not be published and due efforts

will be made to conceal identity, but anonymity cannot be guaranteed.

Financial support and sponsorship

Nil.

Conflicts of interest

There are no conflicts of interest.

References

- Cao J, Jiao J, Du Z, Xu W, Sun B, Li F, *et al.* Combined Hyperactive Dysfunction Syndrome of the Cranial Nerves: A Retrospective Systematic Study of Clinical Characteristics in 44 Patients. *World Neurosurg* 2017;104:390-7.
- Kobata H, Kondo A, Iwasaki K, Nishioka T. Combined hyperactive dysfunction syndrome of the cranial nerves: Trigeminal neuralgia, hemifacial spasm, and glossopharyngeal neuralgia: 11-year experience and review. *Neurosurgery* 1998;43:1351-61.
- Yang KH, Na JH, Kong DS, Park K. Combined hyperactive dysfunction syndrome of the cranial nerves. *J Korean Neurosurg Soc* 2009;46:351-4.
- Zhang YQ, Yu F, Zhao ZY, Men XZ. Combined Hyperactive Dysfunction Syndrome of the Cranial Nerves: Analysis of 37 Cases and Literature Review. *World Neurosurg* 2019;129:e650-e656.
- Besta R, Shankar YU, Kumar A, Rajasekhar E, Prakash SB. MRI 3D CISS- A Novel Imaging Modality in Diagnosing Trigeminal Neuralgia - A Review. *J Clin Diagn Res* 2016;10:ZE01-3.
- Geneidi EAS, Ali HI, Abdel Ghany WA, Nada MA. Trigeminal pain: Potential role of MRI. *Egypt J Radiol Nucl Med* 2016;47:1549-55.
- Hitchon PW, Zanaty M, Moritani T, Uc E, Pieper CL, He W, *et al.* Microvascular decompression and MRI findings in trigeminal neuralgia and hemifacial spasm. A single center experience. *Clin Neurol Neurosurg* 2015;139:216-20.
- Bick SK, Huie D, Sneh G, Eskandar EN. Older patients have better pain outcomes following microvascular decompression for trigeminal neuralgia. *Neurosurgery* 2019;84:116-22.
- Jeon CJ, Kong DS, Lee JA, Park K. The efficacy and safety of microvascular decompression for hemifacial spasm in elderly patients. *J Korean Neurosurg Soc* 2010;47:442-5.
- Ruiz-Juretschke F, Vargas AJ, Gonzalez-Quarante LH, Gil de Sagredo OL, Montalvo A, Fernandez-Carballal C. Microsurgical treatment of trigeminal neuralgia in patients older than 70 years: An efficacy and safety study. *Neurologia* 2017;32:424-30.
- Sekula RF Jr, Frederickson AM, Jannetta PJ, Quigley MR, Aziz KM, Arnone GD. Microvascular decompression for elderly patients with trigeminal neuralgia: A prospective study and systematic review with meta-analysis. *J Neurosurg* 2011;114:172-9.
- Youn J, Kwon S, Kim JS, Jeong H, Park K, Cho JW. Safety and effectiveness of microvascular decompression for the treatment of hemifacial spasm in the elderly. *Eur Neurol* 2013;70:165-71.
- Ballantyne ES, Page RD, Meaney JF, Nixon TE, Miles JB. Coexistent trigeminal neuralgia, hemifacial spasm, and hypertension: Preoperative imaging of neurovascular compression. Case report. *J Neurosurg* 1994;80:559-63.
- Muhammad S, Niemelä M. Surgical management of coexisting trigeminal neuralgia and hemifacial spasm. *Surg Neurol Int* 2018;9:214.
- Zhong J, Zhu J, Li ST, Guan HX. Microvascular decompressions

- in patients with coexistent hemifacial spasm and trigeminal neuralgia. *Neurosurgery* 2011;68:916-20.
16. Nunta-Aree S, Patiwech K, Sitthinamsuwan B. Microvascular decompression for treatment of trigeminal neuralgia: Factors that predict complete pain relief and study of efficacy and safety in older patients. *World Neurosurg* 2018;110:e979-e988.
 17. Oesman C, Mooij JJ. Long-term follow-up of microvascular decompression for trigeminal neuralgia. *Skull Base* 2011;21:313-22.
 18. Sharma GR, Jha R, Poudel P, Adhikari DR, Bista P. Microvascular decompression for trigeminal neuralgia: Our experiences at Bir Hospital. *Nepal J Neurosci* 2017;14:11-5.
 19. Sindou M, Mercier P. Microvascular decompression for hemifacial spasm: Outcome on spasm and complications. A review. *Neurochirurgie* 2018;64:106-16.