

## Isolated Aqueductal Blood Clot in Primary Intraventricular Hemorrhage Leading to Acute Obstructive Hydrocephalus in an Adult

Sir,

Acute obstructive hydrocephalus is a well-known complication of intraventricular hemorrhage (IVH).<sup>[1]</sup> Accurate diagnosis, timely intervention with ventricular drainage remains the treatment of choice. Noncontrast computed tomography (NCCT) is the investigation of choice. Very few cases of primary IVH with an isolated aqueductal blood clot have been reported in the literature. We would like to report one such case to highlight this rare but important clinical entity to young neurosurgeons in training.

A 60-year-old hypertensive gentleman was brought to the emergency room with history of progressively declining consciousness over 2–3 h. He was deeply comatose, heart rate was 80/min, blood pressure was 110/70 mm hg, breathing spontaneously and maintaining 98% oxygen saturation on room air. He was afebrile and had adequate urine output. There was no history of seizure or head injury. His Glasgow coma scale (GCS) was 4/15 (E1 V1 M2), with bilateral extensor response. He had down gaze with equal pupillary light reaction. Working diagnosis was acute hydrocephalus. Urgent NCCT head confirmed this and showed IVH with triventricular obstructive hydrocephalus due to a small hyperdense blood clot plugging the cerebral aqueduct [Figure 1]. The patient underwent emergency ventricular tapping followed by placement of continuous external ventricular drainage (EVD) system following which he showed dramatic improvement in sensorium. He was awake, attentive and was communicating coherently with grade 5/5 power in all limbs. Cerebrospinal fluid (CSF) was non meningitic. Repeat serial imaging showed dissolution of the aqueductal blood clot and hydrocephalus [Figure 2] and EVD was removed on day 4. Contrast enhanced brain magnetic resonance imaging (MRI) [Figures 3-5] and digital subtraction angiography ruled out any vascular or structural cause of the bleed. He was discharged on day 10 of admission with full recovery.

The aqueduct of Sylvius is the narrowest structure of the ventricle. Aqueductal atresia, stenosis, tectal plate gliomas, pineal region tumors, IVH are well known causes of obstructive hydrocephalus. Primary IVH occurs within the ventricles. Etiologies include hypertension, vascular malformations, subependymal hemorrhage, trauma, tumours, anticoagulation or bleeding disorders. Till date, the literature has reported many cases of IVH but very few cases of IVH with an isolated aqueductal blood clot have been reported.<sup>[2]</sup>

Acute obstructive hydrocephalus is a medical emergency and treatment of choice is continuous EVD. Yoshimoto *et al.*<sup>[3]</sup> describe a 59 year-old patient with moyo-moya disease with a small blood clot plugging the aqueduct. He was treated with ventriculostomy

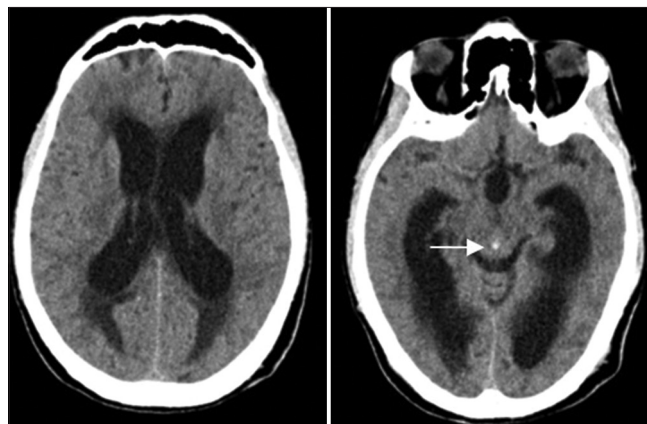


Figure 1: Computed tomography on admission shows enlarged lateral ventricles (left). A small blood clot is seen blocking the aqueduct (white arrow) along with dilatation of the third ventricle (right)

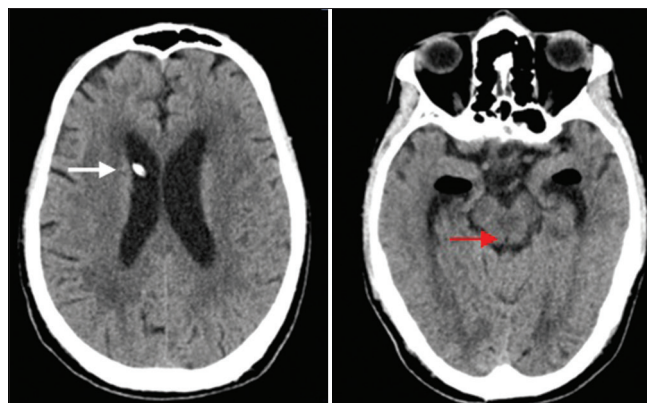


Figure 2: Computed tomography on day 4 of admission shows resolution of hydrocephalus and the external ventricular drain is seen in the frontal horn of right lateral ventricle (white arrow) (left). The blood clot has cleared and the aqueduct of Sylvius now appears hypodense (red arrow) (right)

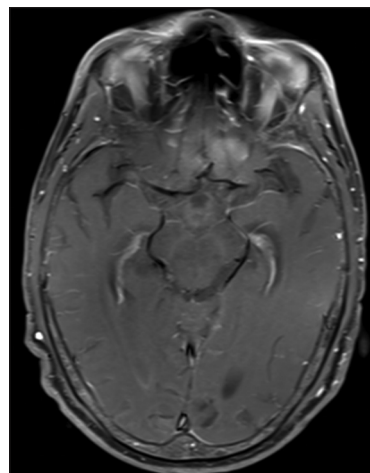


Figure 3: Axial contrast enhanced magnetic resonance imaging section at the level of aqueduct in midbrain

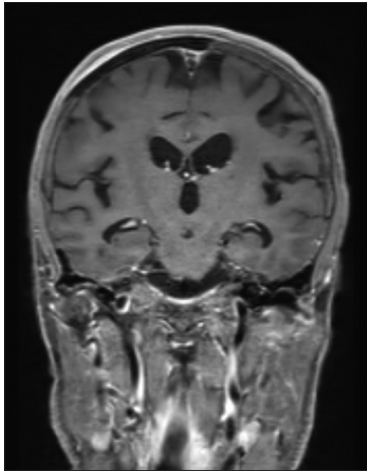


Figure 4: Coronal contrast enhanced magnetic resonance imaging section at the level of aqueduct in midbrain

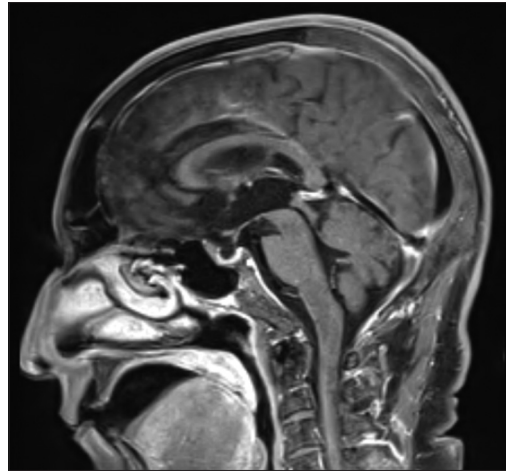


Figure 5: Sagittal contrast enhanced magnetic resonance imaging section at the level of aqueduct in midbrain

and had complete neurological recovery. Spennato *et al.*<sup>[4]</sup> reported 6 patients with post traumatic IVH and hydrocephalus; two patients recovered with EVD alone, two required endoscopic third ventriculostomy and the remaining two who had delayed presentation required permanent CSF diversion. In a few cases, spontaneous resolution of hydrocephalus secondary to IVH has also been reported, although this is a rare occurrence.<sup>[5]</sup> Despite all aggressive treatment measures, IVH is known for its poor functional outcome and high mortality. Primary IVH has a relatively better prognosis than secondary IVH.

Thus, prompt diagnosis and timely intervention in IVH improves functional outcome. EVD is the treatment of choice in acute hydrocephalus. A small blood clot in the aqueduct as seen in our patient can be easily missed by a young doctor in training. Hence it is very important to remember this rare but plausible clinical entity.

#### Declaration of patient consent

The authors certify that they have obtained all appropriate patient consent forms. In the form the patient(s) has/have given his/her/their consent for his/her/their images and other clinical information to be reported in the journal. The patients understand that their names and initials will not be published and due efforts will be made to conceal their identity, but anonymity cannot be guaranteed.

#### Financial support and sponsorship

Nil.

#### Conflicts of interest

There are no conflicts of interest.

**Anagha Sudhakar Prabhune,  
Ranjitsingh K. Deshmukh<sup>1</sup>**

*Department of Neurological Surgery, Deenanath Mangeshkar Multispeciality Hospital and Research Centre, <sup>1</sup>Department of Neurological Surgery, Sahyadri Superspeciality Hospital, Pune, Maharashtra, India*

#### Address for correspondence:

*Dr. Anagha Sudhakar Prabhune,  
Department of Neurosurgery, Deenanath Mangeshkar Multispeciality Hospital and Research Centre, Erandwane, Pune - 411 004, Maharashtra, India.*

*E-mail: anaghaprabhune@gmail.com*

#### References

1. Shakeri M, Vahedi P, Lotfinia I. A review of hydrocephalus. *Neurosurg Q* 2008;18:216-20.
2. Ikeda Y, Yamakawa K, Nakazawa S. [A case of traumatic intraventricular hemorrhage (author's transl)]. *No Shinkei Geka* 1980;8:667-71.
3. Yoshimoto Y, Ochiai C, Kawamata K, Endo M, Nagai M. Aqueductal blood clot as a cause of acute hydrocephalus in subarachnoid hemorrhage. *AJNR Am J Neuroradiol.* 1996;17:1183-86.
4. Spennato P, Ruggiero C, Parlato RS, Trischitta V, Mirone G, De Santi MS, Cinalli G. Acute post-traumatic hydrocephalus in children due to aqueductal obstruction by blood clot: A series of 6 patients. *Childs Nerv Sys* 2019;35:2037-2041.
5. Diamond EL, Kimchi EY, Shankar GM, Silverman SB. Transient aqueductal occlusion in intracerebral haemorrhage. *Pract Neurol* 2012;12:388-9.

This is an open access journal, and articles are distributed under the terms of the Creative Commons Attribution-NonCommercial-ShareAlike 4.0 License, which allows others to remix, tweak, and build upon the work non-commercially, as long as appropriate credit is given and the new creations are licensed under the identical terms.

Access this article online	
<b>Quick Response Code:</b> 	<b>Website:</b> <a href="http://www.asianjns.org">www.asianjns.org</a>
	<b>DOI:</b> 10.4103/ajns.AJNS_450_20

**How to cite this article:** Prabhune AS, Deshmukh RK. Isolated aqueductal blood clot in primary intraventricular hemorrhage leading to acute obstructive hydrocephalus in an adult. *Asian J Neurosurg* 2021;16:661-2.

**Submitted:** 28-Sep-2020 **Revised:** 15-Feb-2021  
**Accepted:** 04-May-2021 **Published:** 14-Sep-2021

© 2021 Asian Journal of Neurosurgery | Published by Wolters Kluwer - Medknow