

Analysis of 93 Brain Abscess Cases to Review the Effect of Intervention to Determine the Feasibility of the Management Protocol: A Tertiary Care Perspective

Abstract

Context: Brain abscess is a suppurative process within the brain parenchyma, which remains a challenge for clinicians. Surgical excision or aspiration combined with prolonged antibiotics (usually 4–8 weeks) or only conservative management remains the treatment of choice. **Aims:** The purpose of this study is to analyze the epidemiology of brain abscess and to determine the potential factors leading to better outcomes. **Settings and Design:** This was a retrospective analysis of 93 patients undergoing various treatment options for brain abscess in a tertiary care center. **Materials and Methods:** Their preoperative status, etiology, and microbiological and clinical outcomes were analyzed. **Statistical Analysis Used:** Statistical analysis was done by Chi-square, one-way analysis of variance, and *post hoc* Newman–Keuls multiple comparison test wherever applicable using SPSS software. **Results:** Among 93 brain abscess cases, only 21 cases had a diameter <2.5 cm. Among them, conservative treatment was done for 38% of patients (8/21), aspiration for 47.6% (10/21) of patients, and excision for only 3 (14.2%) of cases. About 37.5% (3/8) persons among these conservatively managed patients had recurrence. None of the patients of <2.5 cm abscess having surgical management had recurrence or any new neurological deficits postsurgery during the 6-month follow-up. **Conclusions:** There was a significantly high recurrence among the nonsurgically treated patients with lesions <2.5 cm and there was no recurrence or neurological deficit after aspiration among these patients. Probably, aspiration has better results among these patients contrary to previous recommendations of antibiotic therapy alone.

Keywords: Abscess size, aspiration, brain abscess, craniotomy, recurrence

Introduction

Brain abscess is a pyogenic infection of the brain parenchyma.^[1] The incidence rate has been estimated from 0.2 to 1.9/100,000 person-years. The major predisposing factors include an associated contiguous focus of infection, trauma, and hematogenous spread from a distant focus.^[2]

The microbiological etiology depends on various factors such as primary site infection, age of the patient, underlying condition with immune status, and geographic location. The organisms most commonly isolated are anaerobic bacteria, aerobic and microaerophilic streptococci, Enterobacteriaceae, and *Staphylococcus aureus*.^[3] Once an abscess has formed, surgical excision or drainage combined with prolonged

antibiotics (usually 4–8 weeks) remains the treatment of choice based on the size, location, and symptoms.^[4]

This retrospective study is based on our experience with brain abscess treated in our tertiary care hospital over the past 2 years. The demographics data, predisposing factors, clinical characteristics, radiology findings, microbiological findings, treatment, clinical outcome, and recurrence were recorded, and we analyzed these variables to identify predictive factors for better clinical outcomes and feasibility of the management protocol.

Materials and Methods

The department of neurosurgery in our institution conducted this study on the patients who were undergoing treatment for brain abscess, for a period of around

Sambuddha Dhar, Barnava Pal^{1,2}

Departments of Neurosurgery and ¹Anesthesiology, Institute of Medical Sciences–Banaras Hindu University, Varanasi, Uttar Pradesh, ²Department of Anesthesiology, JIMSH, Kolkata, West Bengal, India

Address for correspondence:

Dr. Sambuddha Dhar,
503, Maa Vaishnav
Apartments, Saket Nagar,
Near Banaras Sweet
House, Varanasi - 221 005,
Uttar Pradesh, India.
E-mail: dharsambuddha20@
gmail.com

Access this article online

Website: www.asianjns.org

DOI: 10.4103/ajns.AJNS_467_20

Quick Response Code:



This is an open access journal, and articles are distributed under the terms of the Creative Commons Attribution-NonCommercial-ShareAlike 4.0 License, which allows others to remix, tweak, and build upon the work non-commercially, as long as appropriate credit is given and the new creations are licensed under the identical terms.

For reprints contact: WKHLRPMedknow_reprints@wolterskluwer.com

How to cite this article: Dhar S, Pal B. Analysis of 93 brain abscess cases to review the effect of intervention to determine the feasibility of the management protocol: A tertiary care perspective. Asian J Neurosurg 2021;16:483-7.

Submitted: 11-Oct-2020

Revised: 23-Dec-2020

Accepted: 10-Apr-2021

Published: 14-Sep-2021

2 years beginning from January 2018 to December 2019. All the patients were admitted after clinical assessment under a standard medical protocol and subjected to complete basic hematochemical, radio-imaging evaluation wherever feasible. The neurological status of patients was assessed on admission by the Glasgow Coma Scale (GCS). The following information was documented for each patient: sex, age, mode of presentation, clinical status on admission, abscess size, and predisposing factors.

Management was done by conservative method or surgical intervention either with aspiration via a bur hole or complete excision of abscesses through craniotomy or craniectomy. The diameter of the abscess was defined as the mean maximum diameter in length, width, and height on computed tomography (CT) or magnetic resonance images.

To evaluate abscess size after aspiration, CT imaging was performed ~ 4 h after aspiration/excision. All patients received antibiotics preoperatively and postoperatively for 6 weeks with third-generation cephalosporin and metronidazole empirically. The antibiotics were changed to more appropriate ones as soon as the results of culture and sensitivity tests were available.

Immediate postoperative neurological status was also assessed. The pus was sent for microbiological culture in cases of surgical intervention. Patients were also followed up for recurrence or complication for 6 months on average.

Statistical analysis was done using IBM SPSS (Statistical Package for the Social Sciences) version 25.0. Standard descriptive statistical calculations (mean \pm standard deviation) and one-way analysis of variance were used in the comparison of groups, the *posthoc* Newman–Keuls multiple comparison test was used to compare different groups, and the Chi-square test was performed for qualitative data. $P < 0.05$ was taken as statistically significant.

Results

Over the period of 2 years (from January 2018 to December 2019), 93 patients with brain abscess were managed by the Department of Neurosurgery at the Institute of Medical Sciences, Banaras Hindu University, Varanasi. Out of these cases, 52 patients (55.9%) were male and 41 patients (44.1%) were female. The male-to-female ratio was 1.3:1.

A total of 94.6% (88/93) of patients were below 25 years of age which were equally distributed between pediatric (<12 years) and young adult (12–25 years) patients. Only 5.4% of patients were between 25 and 50 years, there were no cases above 50 years of age.

Chronic suppurative otitis media (CSOM) was the most common predisposing factor of brain abscess with 67.7% (63/93) cases and heart disease was the second most common with 20.4% (19/93) cases. In ten cases, no

predisposing factor could be found. There was one case of suspected dental infection causing brain abscess. Among the 44 pediatric patients, 36% (16/44) had heart disease and 47.7% (21/44) had CSOM as the predisposing factor. Among the young adult group, 86% (38/44) had otic cause of abscess.

Most cases (71%) cases were supratentorial and the rest were infratentorial. In pediatric patients (<12 years' age), 79.5% (35/44) were supratentorial.

About 77.4% (72/93) abscesses were larger than 2.5 cm. Among them, 49 cases were supratentorial and 23 were infratentorial. All of them were subjected to surgical intervention either with aspiration (48.6%, 35/72) or with excision (51.3%, 37/72). However among the 21 cases with lesions smaller than 2.5 cm, 17 (80.9%) were supratentorial and 4 (19%) were infratentorial. Conservative treatment was done for just 38% (8/21) of patients with smaller than 2.5 cm lesion. The rest 10 (47.6%) cases needed aspiration and excisions were needed for three (14.2%) cases [Table 1].

Three persons among these eight conservatively managed patients had a recurrence. None of the patients of <2.5 cm diameter lesion who received surgical treatment had a recurrence or any new neurological deficits postsurgery during the 6-month follow-up. Statistically, a significant difference was found in the recurrence between conservative and surgical management options.

Among the 10 total recurrences, the rest six patients had abscess more than 2.5 cm. Predisposing factors in recurrence cases were CSOM in six cases and heart disease in two cases [Table 2].

For patients on conservative management, microbiological testing could not be done. In the rest of the patients, microbiology was assessed where 52.7% (49/93) sterile, 28 aerobic, 5 cases of anaerobic, and 1 fungal were found. *Staphylococcus aureus* was the most common aerobic bacteria noted and one case of fungal among an immunocompromised elderly was found. Anaerobic culture was taken in the Robertson cooked broth media immediately after taking the sample postoperatively.

Preoperative and postoperative GCS was also compared [Table 3]. One of the patients who recurred among the conservative cases recurred with a larger abscess and expired before getting shifted to the operation theater on an emergency basis.

Figure 1 shows a CT scan view of different abscesses and Figure 2 shows intraoperative pus from the frontal abscess in the subfrontal approach. Figure 3 shows a CT scan of postoperative day 1 of parietal abscess excision.

Discussion

Brain abscess is a suppurative process within the brain parenchyma. Despite the presence of effective and specific antimicrobial agents and improved neurosurgical

Table 1: Relationship between abscess size and management options with recurrence

Management options	<2.5 cm		>2.5 cm		Total
	Recurrence	No recurrence	Recurrence	No recurrence	
Conservative	3	5	0	0	8
Aspiration	0	10	2	28	40
Excision	0	3	5	37	45
Total	3	18	7	65	93

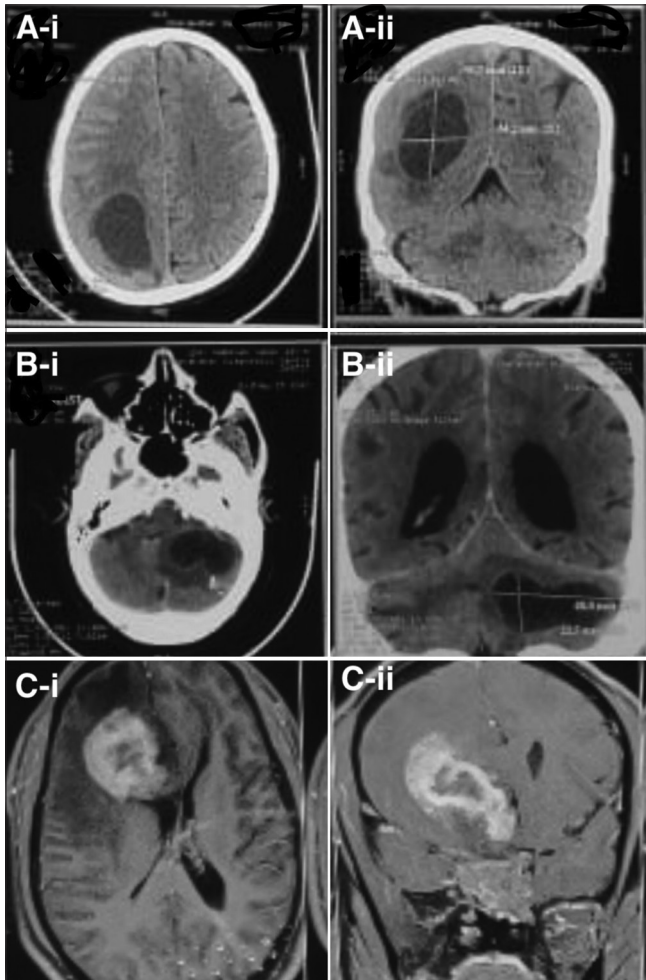


Figure 1: (a) Computed tomography scan showing supratentorial abscess (i) axial view, (ii) coronal view. (b) Computed tomography scan showing infratentorial abscess (i) axial view, (ii) coronal view. (c) Computed tomography scan showing fungal abscess (i) axial view, (ii) coronal view

techniques, morbidity was high.^[5] However, significant improvement occurred in the previous couple of decades for the advancement of noninvasive diagnostic techniques and the use of a combined medicalsurgical approach.^[6]

In our study, male predominance was found; which is analog to previous studies.^[7,8] Most of the studies showed that the median age of brain abscess was 24–57 years.^[9] However, pediatrics and young adults were the key populations in our study, which is similar to the study by Menon *et al.*^[10]

There are several predisposing factors of brain abscess such as immunocompromised state, preexisting medical

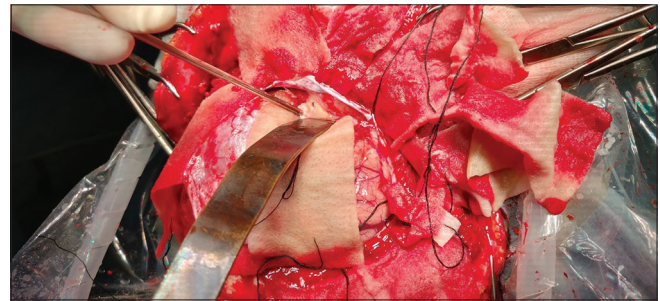

Figure 2: Intra-operative pus from frontal abscess in subfrontal approach

conditions, and distant infection.^[11] Consistent with Sharma *et al.*, an adjacent focus of infections such as sinusitis, otogenic, odontogenic, and postmeningitis was found in 42.5% of patients of brain abscess, followed by distant infections and neurosurgical procedures.^[12] Nathoo *et al.* reported that oto-rhinogenic infections (38.5%) and trauma (32.8%) were the two most common causes of brain abscess.^[13] Similarly, in our study, CSOM and heart disease are found to be the most common predisposing factors. No case of posttraumatic brain abscess was found in our study. Site and microbiological findings have followed a pattern normally.^[14]

The aim of brain abscess management is to reduce the intracranial pressure and the space-occupying activity, with the eradication of pathogenic microorganisms. Management of brain abscess is also influenced by its anatomical location, number and size, stage of abscess formation, age, and neurological status of the patient.^[15] Medical therapy alone may be successful if the patient is neurologically stable with no signs of increased intracranial pressure and abscess <2.5 cm in diameter with illness duration <2 weeks.^[16] However, surgical drainage followed by antimicrobial therapy is the treatment of choice for most brain abscesses.^[17] Surgical treatment can involve either aspiration or excision of the abscess. The choice of surgical method for brain abscess is still a debated subject.^[18] The mean mortality for aspiration post-1990 was 6.6% for studies having more than five patients and with surgical excision by craniotomy, the mean mortality was 12.7% within the same period.^[19] The benefit of aspiration is that it is simple, it may be used in the cerebritis stage, and it has less potential morbidity than surgical trauma.^[20] Excision was found to be better than aspiration in terms of length of hospital stay and reoperation.^[21] In our study, there was no statistically significant difference found between surgical methods.

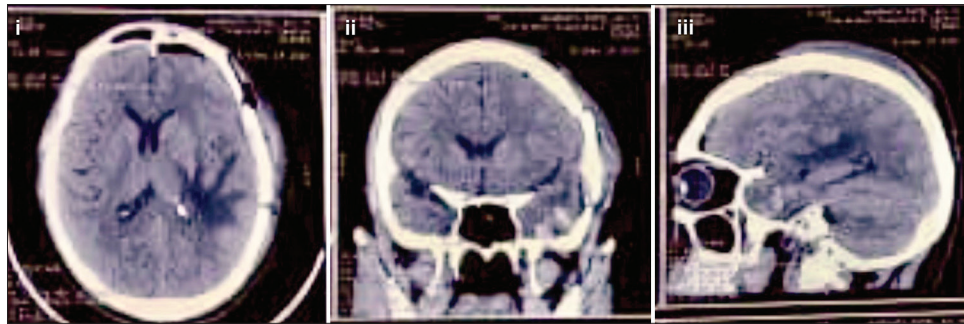


Figure 3: Computed tomography scan showing picture of post-operative day 1 of Parietal abscess excision (i) axial view, (ii) coronal view, (iii) sagittal view

Table 2: Relationship between predisposing factor and recurrence

Predisposing factors	Recurrence	No recurrence	Total
CSOM	6	57	63
Heart disease	2	17	19
Idiopathic	2	8	10
Others	0	1	1
Total	10	83	93

CSOM - Chronic suppurative otitis media

Table 3: Comparison between pretreatment and posttreatment Glasgow Coma Scale

GCS score	Pretreatment GCS	Posttreatment GCS
<8	17	0
8-14	52	15
15	24	78
Total	93	93

GCS - Glasgow Coma Scale

The cerebritis phase refers to abscesses in an early stage of formation within which there is inward migration of leukocytes and significant secondary edema but no well-formed fibrous capsule. These abscesses are usually seen within the first 0–9 days of development,^[21] and since they are not encapsulated, antibiotic therapy is more likely to provide adequate therapy without surgery.^[22] In such cases, the abscess would only be aspirated for diagnosis and organism identification. Most of the patients in this series were treated using aspiration via a single bur hole and had a favorable outcome.

The choice of initial antimicrobial therapy depends on the suspected pathogen and also the ability of antibiotics to penetrate the brain tissue and abscess cavity. For brain abscesses related to sinusitis, mastoiditis, or otitis, a third-generation cephalosporin plus metronidazole is usually recommended. With the increasing prevalence of methicillin-resistant *S. aureus* and *Staphylococcus epidermidis*, vancomycin should be added to third-generation cephalosporin with metronidazole, in cases related to penetrating head trauma, ventriculoperitoneal shunts, or endocarditis. Patients with immunocompromise are susceptible to infections by difficult-to-treat pathogens

such as *Nocardia* species, mycobacteria, fungi, and parasites.^[23] Guidelines are recommended for a treatment protocol to be cautiously applied for high-risk patients with small abscesses.^[24] In our study, patients were treated with cephalosporin and metronidazole while awaiting the bacteriological culture report, and therefore, the regimens were promptly changed to a more suitable antimicrobial based on the results of culture and antibiotic sensitivity testing.

In our study, we surprisingly did not find any case of tubercular abscess, which is probably because most of our patients had been on various antibiotics preoperatively including fluoroquinolones and aminoglycosides which are antitubercular in nature. A separate study can be done on patients who did not receive any antibiotics before sampling the pus to evaluate the role of tuberculosis in our group of brain abscess patients.

Detection rate of an organism in culture is high in respect to other publications. Probably, the high rate of preoperative antibiotics used in other studies gave a false low detection. One more possibility may be contamination while sampling. Antibiotic resistance could also be another assumption, as when there is antibiotic resistance, there will be more growth and antibiotic resistance is quite common in our country.

Usually, antibiotic therapy alone produced satisfactory results when the diameter of abscess became <2.5 cm. No abscess recurrence was noted in <2.5 cm lesion patients who underwent excision with open surgery.

Conclusions

There was a significantly high recurrence rate found among the nonsurgically treated patients with lesions <2.5 cm. However in the similar-sized abscess cases, who were treated by aspiration, no recurrence or no neurological deficits were found. Probably, aspiration can give better results among these patients contrary to previous recommendations of antibiotic therapy alone. Further studies are required to validate our findings in our population.

Financial support and sponsorship

Nil.

Conflicts of interest

There are no conflicts of interest.

References

- Ackerman L, Traynelis V. Dural space infections. In: Osenbach RK, Zeidman SM, editors. *Infections in Neurological Surgery: Diagnosis and Management*. Philadelphia, PA: Lippincott-Raven; 1999. p. 85-99.
- Laulajainen-Hongisto A, Lempinen L, Färkkilä E, Saat R, Markkola A, Leskinen K, *et al*. Intracranial abscesses over the last four decades; changes in aetiology, diagnostics, treatment and outcome. *Infect Dis (Lond)* 2016;48:310-6.
- Brook I. Microbiology and treatment of brain abscess. *J Clin Neurosci* 2017;38:8-12.
- Takeshita M, Kagawa M, Izawa M, Takakura K. Current treatment strategies and factors influencing outcome in patients with bacterial brain abscess. *Acta Neurochir (Wien)* 1998;140:1263-70.
- Alvis Miranda H, Castellar-Leones SM, Elzain MA, Moscote-Salazar LR. Brain abscess: Current management. *J Neurosci Rural Pract* 2013;4:S67-81.
- Wispelwey B, Scheld WM. Brain abscess. *Clin Neuropharmacol* 1987;10:483-510.
- Aras Y, Sabanci PA, Izgi N, Boyali O, Ozturk O, Aydoseli A, *et al*. Surgery for pyogenic brain abscess over 30 years: Evaluation of the roles of aspiration and craniotomy. *Turk Neurosurg* 2016;26:39-47.
- Amornpojnimm T, Korathanakun P. Predictors of clinical outcomes among patients with brain abscess in Thailand. *J Clin Neurosci* 2018;53:135-9.
- Patel K, Clifford DB. Bacterial brain abscess. *Neurohospitalist* 2014;4:196.
- Menon S, Bharadwaj R, Chowdhary A, Kaundinya DV, Palande DA. Current epidemiology of intracranial abscesses: A prospective 5 year study. *J Med Microbiol* 2008;57:1259-68.
- Brouwer MC, Tunkel AR, McKhann GM, Van de Beek D. Brain abscess. *N Engl J Med* 2014;371:447-56.
- Sharma R, Mohandas K, Cooke RP. Intracranial abscesses: Changes in epidemiology and management over five decades in Merseyside. *Infection* 2009;37:39-43.
- Nathoo N, Nadvi SS, Narotam PK, van Dellen JR. Brain abscess: Management and outcome analysis of a computed tomography era experience with 973 patients. *World Neurosurg* 2011;75:716-26.
- Yogev R, Bar-Meir M. Management of brain abscesses in children. *Pediatr Infect Dis J* 2004;23:157-9.
- Cavuşoglu H, Kaya RA, Türkmenoglu ON, Colak I, Aydin Y. Brain abscess: Analysis of results in a series of 51 patients with a combined surgical and medical approach during an 11-year period. *Neurosurg Focus* 2008;24:E9.
- Mamelak AN, Mampalam TJ, Obana WG, Rosenblum ML. Improved management of multiple brain abscesses: A combined surgical and medical approach. *Neurosurgery* 1995;36:76-85.
- Chew Y. Brain abscess: Awareness make a difference. *J Neurosci Rural Pract* 2013;4:S7-8.
- Yamamoto M, Fukushima T, Hirakawa K, Kimura H, Tomonaga M. Treatment of bacterial brain abscess by repeated aspiration--Follow up by serial computed tomography. *Neurol Med Chir (Tokyo)* 2000;40:98-104.
- Ratnaike TE, Das S, Gregson BA, Mendelow AD. A review of brain abscess surgical treatment--78 years: Aspiration versus excision. *World Neurosurg* 2011;76:431-6.
- Heineman HS, Braude AI, Osterholm JL. Intracranial suppurative disease. Early presumptive diagnosis and successful treatment without surgery. *JAMA* 1971;218:1542-7.
- Wispelwey B, Scheld WM. Brain abscess. *Clin Neuropharmacol* 1987;10:483-510.
- Sarmast AH, Showkat HI, Kirmani AR, Bhat AR, Patloo AM, Ahmad SR, *et al*. Aspiration versus excision: A single center experience of forty-seven patients with brain abscess over 10 years. *Neurol Med Chir (Tokyo)* 2012;52:724-30.
- Bodilsen J, Dalager-Pedersen M, van de Beek D, Brouwer MC, Nielsen H. Incidence and mortality of brain abscess in Denmark: A nationwide population-based study. *Clin Microbiol Infect* 2020;26:95-100.
- Rosenblum ML, Hoff JT, Norman D, Edwards MS, Berg BO. Nonoperative treatment of brain abscesses in selected high-risk patients. *J Neurosurg* 1980;52:217-25.