

Revisiting Dandy–Walker Malformation with Associated Neurofibromatosis

Abstract

This report describes a very rare Dandy–Walker malformation (DWM) associated with neurofibromatosis (NF) and bony defect over torcula emphasizing the role of meticulous follow-up for asymptomatic DWM. The clinical aspects of an adolescent patient with undiagnosed DWM who was asymptomatic until the age of 14 years are being discussed. Computed tomography and magnetic resonance imaging were revealed DWM. To our knowledge, this is the first report from India that describes a patient who has been diagnosed with DWM with associated NF with bony defect over torcula creating a management dilemma.

Keywords: *Bony defect, Dandy–Walker syndrome, neurofibromatosis 1*

Introduction

The Dandy–Walker syndrome (DWS) is a congenital anomaly characterized by hydrocephalus, a posterior fossa cyst, and the absence of the cerebellar vermis. This syndrome is well-known but only occurs in 4%–8% of neonates with congenital hydrocephalus. In 80%–90% of individuals with Dandy–Walker malformation (DWM), the signs and symptoms appear within 1st year of life. Multiple associated conditions have been described; however, neurofibromatosis (NF) with a Dandy–Walker is even rarer condition. We report an adolescent patient with DWS associated with NF.

Case Report

A 14-year-old boy with a family history of NF1 born of nonconsanguineous parents presented with complaints of hollowness over the posterior aspect of the scalp since birth for what he was under the follow-up with a local physician. At 14 years of age, he became symptomatic with a history of vomiting, mostly after food intake, since 2–3 years with increased frequency of vomiting at the time of presentation (4 times/week). There was no associated history of headache/seizure/speech difficulty/weakness/gait disturbance/visual disturbance/limb weakness/facial deviation/hearing loss/

dysphagia. On examination, there was wrist hyperflexibility and multiple café au lait spots over chest, abdomen, and back with largest size 2 by 1 cm and Lisch nodules on slit-lamp examination. Bony defect over the posterior parieto-occipital region was noted more in the midline. Father had multiple NF with café au lait spots and grandmother had multiple neurofibromas all over the body. The patient was evaluated radiologically with magnetic resonance imaging of brain and found to have large posterior fossa arachnoid cyst with hypoplastic vermis and posterior superior calvarial defect with focal hyperintensity involving left globus pallidus as shown in Figure 1. Digital subtraction angiography (DSA) showed torcular lambdoid inversion which is seen in DWM due to abnormally high tentorium. CT head showed a bony defect in the midline in parieto-occipital region as shown in Figure 2.

The patient underwent four-vessel DSA to rule out venous anomaly and to exclude sinus thrombosis. Cerebral Angiograms showed a normal outline and branching pattern of the rest of all major arteries including the internal cerebral artery, anterior cerebral artery, middle cerebral artery, posterior cerebral artery, and vertebrobasilar system. No evidence of any steno-occlusive lesions or aneurysms/ectasia were seen. No abnormal blush or early draining veins was seen. There was

Shreykumar Pravinchandra Shah, Jaypalsinh Ashoksinh Gohil, Krishnakumar Kesavapisharady, Harihara Venkat Easwer

Department of Neurosurgery, Sree Chitra Tirunal Institute for Medical Sciences and Technology, Thiruvananthapuram, Kerala, India

Address for correspondence:
Dr. Shreykumar Pravinchandra Shah,
C22, Old PG Block, Sree Chitra Quarters, Poonthi Road, Kumarapuram, Thiruvananthapuram - 695 011, Kerala, India.
E-mail: shrey161@gmail.com

Access this article online

Website: www.asianjns.org

DOI: 10.4103/ajns.AJNS_468_20

Quick Response Code:



This is an open access journal, and articles are distributed under the terms of the Creative Commons Attribution-NonCommercial-ShareAlike 4.0 License, which allows others to remix, tweak, and build upon the work non-commercially, as long as appropriate credit is given and the new creations are licensed under the identical terms.

For reprints contact: WKHLRPMedknow_reprints@wolterskluwer.com

How to cite this article: Shah SP, Gohil JA, Kesavapisharady K, Easwer HV. Revisiting dandy–Walker malformation with associated neurofibromatosis. *Asian J Neurosurg* 2021;16:850-3.

Submitted: 14-Oct-2020

Revised: 14-Jun-2021

Accepted: 21-Aug-2021

Published: 18-Dec-2021

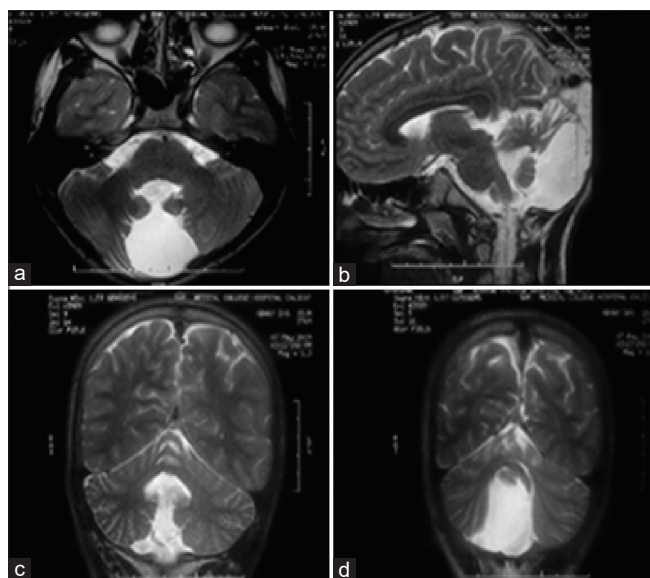


Figure 1: (a) Axial T2-weighted image, (b) Sagittal T2-weighted image, (c and d) coronal T2-weighted image magnetic resonance imaging brain of the patient showing large posterior fossa cyst communicating with fourth ventricle with aplasia of vermis. Other brain parenchyma looks grossly normal

an elevation of torcula and straight sinus with splaying of the transverse sinuses, suspended from the high torcula, giving an inverted Y-shaped appearance. The Vein of Galen was minimally elongated. A distinct avascular zone was seen in the posterior fossa, posterior to the elevated lateral sinuses. There was herniation of the vasculature through the calvarial defect in the occipital region into the scalp. However, the patient was asymptomatic; and hence, he has advised follow-up with advice regarding helmet whereas traveling and to avoid contact sports.

Discussion

DWS is a rare congenital posterior fossa malformation and is reported in only 1 in 25–30,000 live births.^[1] It occurs during the embryonic development of the cerebellum and 4th ventricle^[2] characterized by vermian hypoplasia and posterior fossa cyst, which communicates with fourth ventricle.^[3]

Although syndrome was first described by Sutton in 1887, Dandy and Blackfan in 1914, many new case reports with different features are added later.^[4] The incidence is higher in females compared to males, about 1.5 times higher with a median age of 1 year.^[5,6] Dandy and Blackfan initially believed that this disorder resulted from intrauterine inflammatory process related to the obstruction of foramen of Luschka. However, following his review, Dandy concluded that this disorder resulted from the failure of the development of foramen of Luschka rather than secondary closure.^[7] Many authors have challenged this atresia theory, in which foramina was patent. Embryological studies have shown that cerebellar vermis develops much earlier than the opening of

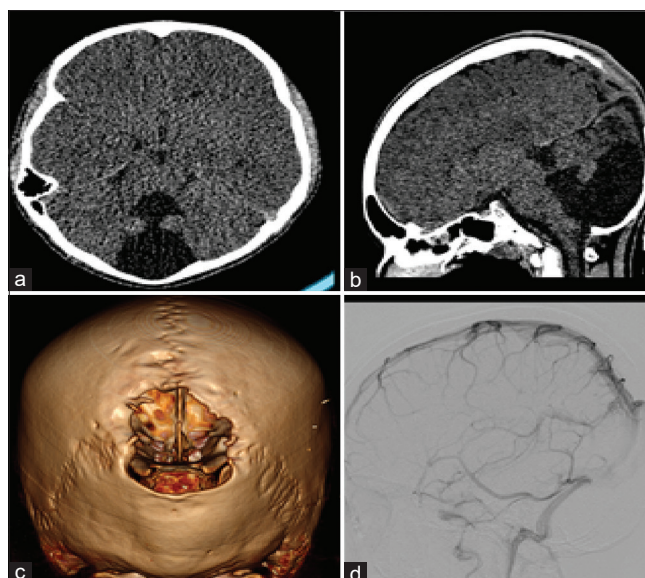


Figure 2: (a) Axial view (b) Sagittal view, and (c) three-dimensional reconstructed bony window image of plain computed tomography head of the patient showing bony defect in parieto-occipital region near junction of lambdoid suture with sagittal suture with hypodense cyst in posterior fossa which is communicating with fourth ventricle. (d) Digital subtraction angiogram of the patient in lateral view showing elevated torcula with splaying of transverse sinus with minimal herniation of vasculature through defect

foramina. This implies an event that must have occurred before the opening of foramina.^[8,9]

Clinical presentation

incidence of DWM is reported to be 1 in 30,000 live births.^[10] Among the various associated anomalies with DWM, corpus callosum agenesis is the most common. Other anomalies included microcephaly, cerebral sulcigyrar pattern abnormality, syringomyelia, aqueduct stenosis, Klippel-Feil syndrome, meningocele, and encephalocele.^[6] Various risks associated with DWM are preterm birth, low birth weight, and twin pregnancy.^[10] Other associated risk factors are the maternal treatment of infertility particularly, warfarin use, clomiphene citrate use, etc., however, the certainty of these finding has been questioned by the same author.^[11,12] In our case, there was no maternal history of any infection, treatment for infertility, abnormal drug abuse, and twin pregnancy.

DWS is diagnosed by clinical examination, ultrasound, or radiological images. Antenatal ultrasound sometimes reveals an enlarged posterior fossa cyst. Neurosonography may be helpful for early detection.^[13] The time of intrauterine origin of this syndrome is unknown, but some case reports revealed that the association of occipital meningocele may suggest the development of this syndrome before the closure of the neural tube.^[14]

NF is based on established clinical criteria by the National Institute of Health consensus development conference on NF.^[15] In our patient, there was a positive family history of

NF, and the patient had multiple café au lait spots with the largest size 2 cm × 1 cm. This proves NF 1 syndrome in our patients.

Although multiple associated conditions have been described with DWS, the association of NF with Dandy–Walker has been reported only in few cases.^[16-18] We report another case of NF1 with DWS which may support the genetic association of this syndrome. In the literature review, one case was reported in German literature and the other cases were reported in monozygotic twins in Oman.^[17,18] One more case was reported in China in March 2014.^[16] In our case, the patient had large additional bony defect over parieto-occipital region near torcula with displaced venous anatomy which has not been reported yet in DWS. This large calvarial defect can be explained by two possibilities. Meningomyelocele and occipital encephalocele have been reported with a Dandy–Walker which may explain the relationship with neural tube defect. The bony defect may be related to this ectodermal development defect in the Dandy–Walker. Other possibility, bony dysplasia is well recognized in the NF 1 population. Arrington *et al.* reported an association of calvarial defect in NF patient and found the most common location near lambdoid suture which may explain bony defect in our case may be part of NF.^[19] Although defect can be present in another part of the skull, this feature may relate to common or adjacent genetical development defects in syndrome. This anomaly is also associated with other congenital malformations as congenital heart malformations, cleft palate, neural tube defects, and urinary malformations.^[20] This syndrome may be associated with nonneurological clinical entities such as neurocutaneous syndromes which can be a treatment challenge and are currently under research.^[21,22]

DWS requires management if one becomes symptomatic mainly for hydrocephalus. Shunting of the lateral ventricle along with cyst is effective management. However, our patient was asymptomatic till the age of 14 years, and hence, we decided to keep him on regular follow-up. We feel this case report may be helpful in further research in genetical association between neurocutaneous syndrome and DWS.

Conclusion

DWS is a rare congenital anomaly with very few cases reported to the date with associated NF. This case report may suggest the involvement of a common genetical or related allele.

Acknowledgment

We would like to acknowledge the support extended by Sree Chitra Tirunal Institute for Medical Sciences and Technology, Trivandrum, Kerala, India. Study participants and their family members.

Declaration of patient consent

The authors certify that they have obtained all appropriate patient consent forms. In the form, the patient(s) has/have given his/her/their consent for his/her/their images and other clinical information to be reported in the journal. The patients understand that their names and initials will not be published and due efforts will be made to conceal their identity, but anonymity cannot be guaranteed.

Financial support and sponsorship

Nil.

Conflicts of interest

There are no conflicts of interest.

References

- Spennato P, Mirone G, Nastro A, Buonocore MC, Ruggiero C, Trischitta V, *et al.* Hydrocephalus in Dandy-Walker malformation. *Childs Nerv Syst* 2011;27:1665-81.
- Bosemani T, Orman G, Boltshauser E, Tekes A, Huisman TA, Poretti A. Congenital abnormalities of the posterior fossa. *Radiographics* 2015;35:200-20.
- Imataka G, Yamanouchi H, Arisaka O. Dandy-Walker syndrome and chromosomal abnormalities. *Congenit Anom (Kyoto)* 2007;47:113-8.
- Dandy WE, Blackfan KD. An experimental, clinical and pathological study: Part 1.–Experimental studies. *Am J Dis Child* 1914;8:406-82.
- Osenbach RK, Menezes AH. Diagnosis and management of the Dandy-Walker malformation: 30 years of experience. *Pediatr Neurosurg* 1992;18:179-89.
- Pascual-Castroviejo I, Velez A, Pascual-Pascual SI, Roche MC, Villarejo F. Dandy-Walker malformation: Analysis of 38 cases. *Childs Nerv Syst* 1991;7:88-97.
- Dandy WE. The diagnosis and treatment of hydrocephalus due to occlusions of the foramina of Magendie and Luschka. *Surg Gynec Obstet* 1921;32:112-24.
- Brodal A, Hauglie-Hanssen E. Congenital hydrocephalus with defective development of the cerebellar vermis (Dandy-Walker syndrome) clinical and anatomical findings in two cases with particular reference to the so-called atresia of the foramina of Magendie and Luschka. *J Neurol Neurosurg Psychiatry* 1959;22:99-108.
- Hart MN, Malamud N, Ellis WG. The Dandy-Walker syndrome. *Neurology* 1972;22:771.
- Reeder MR, Botto LD, Keppler-Noreuil KM, Carey JC, Byrne JL, Feldkamp ML, *et al.* Risk factors for Dandy–Walker malformation: A population-based assessment. *Am J Med Genet Part A* 2015;167A: 2009-16.
- Kaplan LC. Congenital Dandy Walker malformation associated with first trimester warfarin: A case report and literature review. *Teratology* 1985;32:333-7.
- Reefhuis J, Honein MA, Schieve LA, Rasmussen SA; National Birth Defects Prevention Study. Use of clomiphene citrate and birth defects, National Birth Defects Prevention study, 1997-2005. *Hum Reprod* 2011;26:451-7.
- Alam A, Chander BN, Bhatia M. Dandy-Walker variant: Prenatal diagnosis by ultrasonography. *Med J Armed Forces India* 2004;60:287-9.
- Sautreaux JL, Giroud M, Dauvergne M, Nivelon JL, Thierry A.

- Dandy-Walker malformation associated with occipital meningocele and cardiac anomalies: A rare complex embryologic defect. *J Child Neurol* 1986;1:64-6.
15. Neurofibromatosis. Conference statement. National Institutes of Health Consensus Development Conference. *Arch Neurol* 1988;45:575-8.
 16. Na M, Xie C, Wang H, Shen H, Lin Z. Calvarial defects and Dandy-Walker malformation in association with neurofibromatosis type 1. *Chin Med J (Engl)* 2014;127:1187-8.
 17. Sander A, Dörrler J, von Einsiedel HG, Horch HH. Rare combination of neurofibromatosis and Dandy-Walker syndrome. *Dtsch Z Mund Kiefer Gesichtschir* 1989;13:433-43.
 18. Koul RL, Chacko A, Leven HO. Dandy-Walker syndrome in association with neurofibromatosis in monozygotic twins. *Saudi Med J* 2000;21:390-2.
 19. Arrington DK, Danehy AR, Peleggi A, Proctor MR, Irons MB, Ullrich NJ. Calvarial defects and skeletal dysplasia in patients with neurofibromatosis Type 1: Clinical article. *J Neurosurg Pediatr* 2013;11:410-6.
 20. Jurcă MC, Kozma K, Petcheși CD, Bembea M, Pop OL, Mușiu G, *et al.* Anatomic variants in Dandy-Walker complex. *Rom J Morphol Embryol* 2017;58:1051-5.
 21. Infante JR, Garcia L, Rayo JI, Serrano J, Dominguez ML, Moreno M. PET/CT in a patient diagnosed With Dandy-Walker syndrome. *Clin Nucl Med* 2016;41:e58-59.
 22. Stambolliu E, Ioakeim-Ioannidou M, Kontokostas K, Dakoutrou M, Kousoulis AA. The most common comorbidities in Dandy-Walker syndrome patients: A systematic review of case reports. *J Child Neurol* 2017;32:886-902.