

A Piece of Wire into the Brain

Sir,

A 38-year male presented to the emergency department because of headache and fever over 38°C. From the patient's previous history, it was concluded that he had a small trauma in the right temporal region while he worked with a mowing machine 2 days before the admission. The clinical examination did not reveal any pathological signs while the laboratory examinations showed a leukocytosis and elevated C-reactive protein. Skull X-ray revealed the presence of a foreign body [Figure 1]. Brain computed tomography scan that ensued showed that a foreign metallic object penetrated the skin, temporalis muscle, and skull and was embedded in the brain parenchyma of the right temporal lobe. The patient did not understand what was the object that hit him and he thought that it was a stone.

He was operated under general anesthesia with a temporal craniotomy. In the skin of preauricular area and temporalis muscle, there was a small trauma, when the lepidoid bone had a small point of insertion. After opening the dura, we found a laceration in the right temporal lobe with a perifocal edema (subarachnoid hemorrhage, and contusion). The object was a piece of wire and was removed and also the bone flap because of suspicion of contamination after 2 days with this object into the brain [Figure 1]. The patient received antibiotics (ceftriaxone, metronidazole, and vancomycin) for 6 weeks and made a full recovery.

Financial support and sponsorship

Nil.

Conflicts of interest

There are no conflicts of interest.

**Andreas Zigouris, Nikolaos Konsolakis,
George Alexiou, Spyridon Voulgaris**

*Department of Neurosurgery, University Hospital of Ioannina,
Ioannina, Greece*

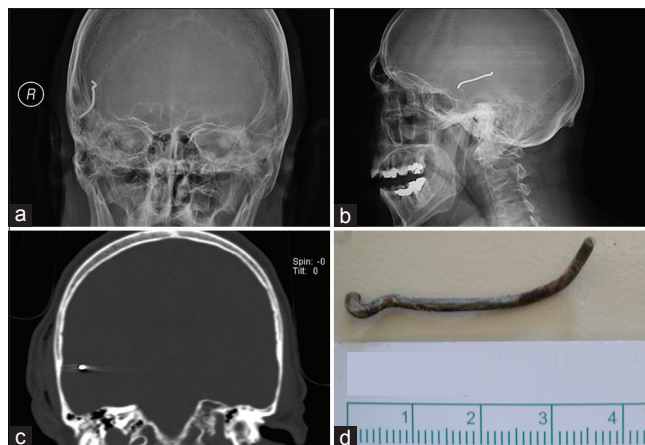


Figure 1: (a and b) Skull X-ray revealing the presence of a foreign body. (c) Coronal computed tomography. (d) Photograph showing the foreign body

Address for correspondence:

Dr. Andreas Zigouris,

*Department of Neurosurgery, University Hospital of Ioannina,
Ioanninon Avenue, 45500 Ioannina, Greece.*

E-mail: andzy76@hotmail.com

This is an open access journal, and articles are distributed under the terms of the Creative Commons Attribution-NonCommercial-ShareAlike 4.0 License, which allows others to remix, tweak, and build upon the work non-commercially, as long as appropriate credit is given and the new creations are licensed under the identical terms.

Access this article online

Quick Response Code:



Website:

www.asianjns.org

DOI:

10.4103/ajns.AJNS_46_17

How to cite this article: Zigouris A, Konsolakis N, Alexiou G, Voulgaris S. A piece of wire into the brain. *Asian J Neurosurg* 2019;14:333.

© 2018 Asian Journal of Neurosurgery | Published by Wolters Kluwer - Medknow