

## Transfalcine Approach for the Resection of a Bilateral Falx Meningioma: Technical Nuances and Review of Literature

### Abstract

The tendency to reduce invasive surgeries is gaining more adepts, and the primary goal in meningioma surgery is the maximal safe resection. Falx meningioma is common location for intracranial meningioma, and according to their deep localization, falx meningioma represents a neurosurgical challenge. The objective of the study is to report the feasibility of a transfalcine nontumor dominant side approach for a bilateral falx meningioma. We report a technical note about the surgical approach of a 44-year-old female suffering from an evolutive meningioma of the middle third of the falx. According to the venous drainage anatomy, and the tumor conformation, a contralateral transfalcine approach was done. We described with details this surgical approach, and a reflection about transfalcine approach is proposed, which is a variant of the interhemispheric approach. It permits a good exposure of the medial surface of the contralateral hemisphere thanks to a falx incision. Moreover, a literature review is proposed about 278 articles with a special emphasis on transfalcine approach in meningioma surgery. We report an original minimal invasive approach for an intracranial meningioma, with a complete resection (Simpson I) without any technical complication. This contralateral transfalcine approach brings new technical nuances for the resection of falx or midline intracranial tumors.

**Keywords:** Meningioma, minimal invasive surgery, nontumor dominant side approach, transfalcine approach

### Introduction

Falx meningioma is common location for intracranial meningioma. According to their deep localization, falx meningioma represents a neurosurgical challenge. Especially about the preservation of the bridging veins, and the cerebral cortex, these elements are more challenging than the extent of resection. The primary goal of the surgery is the maximal safe resection. However, the tendency to reduce invasive surgeries is gaining more adepts.

### Technical Note

We report a technical approach of a 44-year-old female suffering from an evolutive meningioma of the middle third of the falx, with a major axis of 40 mm, and a mass effect on the corpus callosum, also on the frontal left anterior cingulum. A centimetric contralateral extension is observed, and a left 35 mm extension is totally covered by the left supplementary

motor area, with a volume of 26.2 cc [Figure 1].

According to the venous drainage anatomy, and the tumor conformation, a nontumor dominant side approach was chosen. Indeed, the venous drainage docked the cerebral cortex, and no bridging vein in front of the meningioma was observed on the right side. These elements lead us to choose a contralateral transfalcine approach.

### Technical notes of the procedure

We did a cranial parietal flap on the right side very close to midline, with the neuronavigation system (Brainlab\*). The dura mater was opened with a medial insertion, thanks to this; we exposed and we mobilized the right hemispheric edge without any venous sacrifice. The right part of the tumor was removed by this way. The falx was opened around the meningioma insertion first at the above side, then on the anterior part, and *in fine* the posterior

**Sebastien Boissonneau<sup>1,2</sup>,  
Nathan Beucler<sup>3</sup>,  
Thomas Graillon<sup>1,4</sup>,  
Kaissar Farah<sup>1</sup>,  
Stephane Fuentes<sup>1</sup>,  
Henry Dufour<sup>1,4</sup>**

<sup>1</sup>Neurosurgical Department, Aix-Marseille University, APHM, CHU Timone, <sup>2</sup>Institute of Neurosciences of Systems, INSERM, <sup>3</sup>Sainte-Anne Military Teaching Hospital, Toulon, France, <sup>4</sup>CNRS, CRN2M, CHU Timone, Marseille, Aix Marseille University, France

### Address for correspondence:

Dr. Sebastien Boissonneau, Neurosurgical Department, Aix-Marseille University, APHM, CHU Timone, Institute of Neurosciences of Systems, INSERM, Aix Marseille University, Marseille, France. E-mail: sebastien.boissonneau@ap-hm.fr

### Access this article online

Website: [www.asianjns.org](http://www.asianjns.org)

DOI: 10.4103/ajns.AJNS\_476\_20

### Quick Response Code:



This is an open access journal, and articles are distributed under the terms of the Creative Commons Attribution-NonCommercial-ShareAlike 4.0 License, which allows others to remix, tweak, and build upon the work non-commercially, as long as appropriate credit is given and the new creations are licensed under the identical terms.

For reprints contact: WKHLRPMedknow\_reprints@wolterskluwer.com

**How to cite this article:** Boissonneau S, Beucler N, Graillon T, Farah K, Fuentes S, Dufour H. Transfalcine approach for the resection of a bilateral falx meningioma: Technical nuances and review of literature. Asian J Neurosurg 2021;16:821-3.

Submitted: 20-Oct-2020

Revised: 06-Feb-2021

Accepted: 13-May-2021

Published: 18-Dec-2021

part until the inferior sagittal sinus. This last one was invaded by the meningioma and was removed during the procedure [Figure 2].

These technical elements allowed us to mobilize the tumor, to hollow the meningioma, and did an extra-arachnoid dissection. This led us to uncouple the contralateral cortex to the meningioma [Figure 3].

According to the fusion of the postoperative computed tomography scan and the preoperative magnetic resonance imaging (MRI), we did a small unilateral parasagittal bone flap for this procedure [Figure 4].

Three months after, the patient did not report any neurological disorder, or seizure, and the radiological MRI control did not show any postoperative residual tumor due to the Simpson I resection [Figure 5].<sup>[1]</sup>

**Review of literature**

We used PubMed (<https://www.ncbi.nlm.nih.gov/pmed/>) to do a review of literature, by using words: (meningioma) and (transfalcine); we also used the combination (meningioma) and (contralateral). We found, respectively, 10 articles and 268 articles. Among these 278 articles, the authors kept and discussed on the next paragraph only the relevant articles (cf infra).

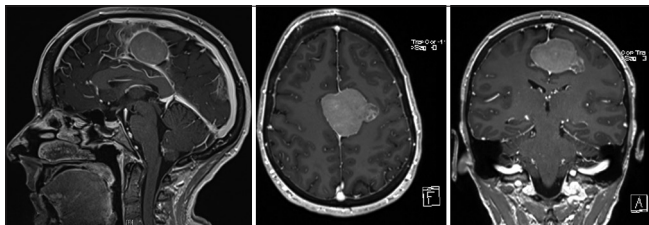


Figure 1: Preoperative magnetic resonance imaging

Informed consent was given by the patient before surgical procedure and publication, and no ethic committee approval/institutional review board was needed due to the retrospective report of this case.

**Discussion**

According to Zuo *et al.* who proposed a surgical planning classification for falcine meningioma, the major axes of the surgery are the minimal brain retraction, perfect visual angle, and early devascularization. Thanks to Hattori *et al.* who reported the interesting series of falcine meningioma with contralateral artery supply; our approach permits to follow the one of classic principles of microneurosurgery for meningioma (i.e., devascularization).<sup>[2]</sup> Indeed, Barajas

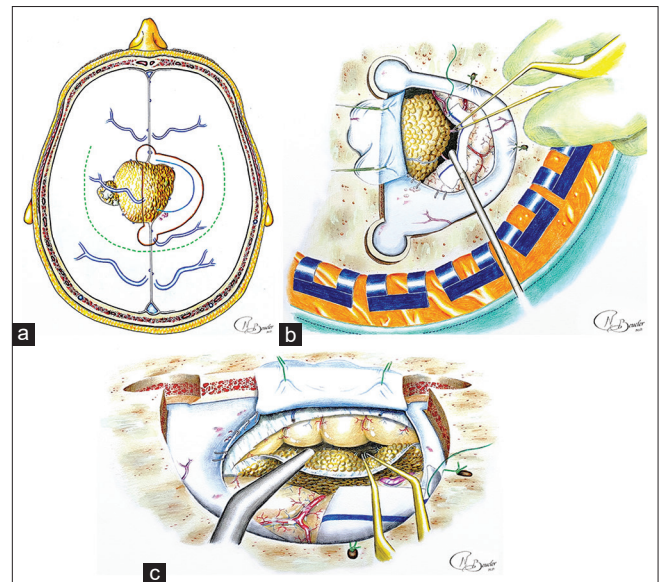


Figure 2: Pencil drawing illustrations. (a): Skin incision (dotted green line), craniotomy (brown line), and dura mater opening (blue line). (b): Right-sided approach because of the absence of bringing vein, and resection of the right side of the meningioma. (c): Inclination of the microscope and tilt of the operative table, which allows transfalcine approach for the resection of the left side of the tumor

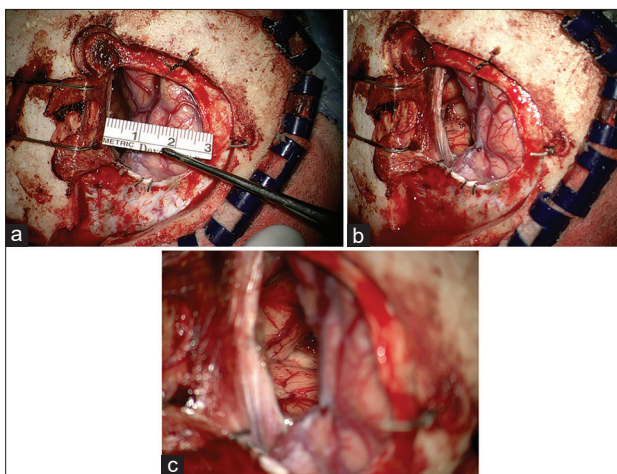


Figure 3: Preoperative pictures after the resection. (a) - 3 x 3 cm dural opening (1.18 inches), (b and c) - Oblique view by the right side of the resection with brain collapsus after resection, showing the right hemispheric crest, the border of resection of the falx, and the operative bed of the contralateral extension of the meningioma. Microscope angulation permits to control the contralateral sides of the tumor and expose the other sides of the brain without any venous sacrifice

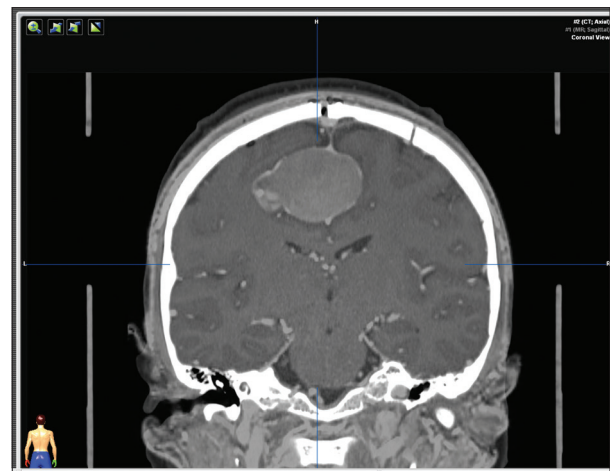


Figure 4: Fusion with postoperative computed tomography scan and preoperative magnetic resonance imaging

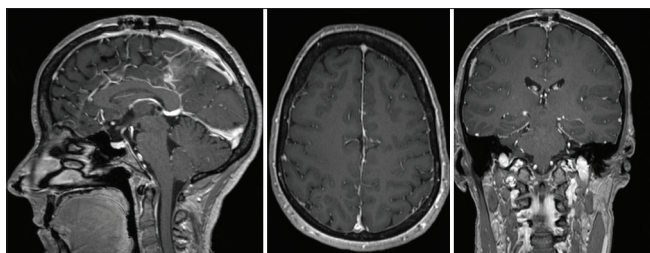


Figure 5: Three-month postoperative magnetic resonance imaging

*et al.* report that a case report of the resection of a falx meningioma by a contralateral interhemispheric approach fed by callosomarginal branch.<sup>[3]</sup>

In other words, transfalcine approach is a variant of the interhemispheric approach and permits a good exposure of the medial surface of the contralateral hemisphere thanks to a falx incision.<sup>[4]</sup> Other lesions such as intra-axial tumor<sup>[5]</sup> could be eligible to a transfalcine removal. This could avoid brain retraction, especially in patient with perilesional edema, and decrease the risks of transparanchymal dissection and retraction of a swollen brain. Indeed, in this case, we can see a peritumoral edema around the dominant side of the tumor. This is the reason why we chose a nontumor dominant side approach for this patient, to avoid brain injury due to the brain swelling. This nontumor dominant side approach optimizes the surgery, the time duration of the procedure, decrease the risk of venous infarction, and optimize the comfort of the surgeon during the resection.

Hence, transfalcine approach could be an interesting option in some cases, especially for patient suffering from meningioma.<sup>[6]</sup>

Moreover, few authors report the use of endoscopic to assist transfalcine surgery, and this seems to be a great option, especially in these cases with deep-seated lesions.<sup>[7,8]</sup> Endoscopic approach seems to be great to overcome the limitation of a small bone flap in this philosophy of minimal invasive cranial surgery.

This nontumor dominant side approach should be used selectively and judiciously; otherwise, the risk of complications is likely to limit its adoption. Indeed, the possibility of complications (i.e., bleeding or venous ischemia) through this corridor requires certain expertise to avoid these, which was described by few authors for intraventricular meningiomas.<sup>[9-11]</sup>

This alternative approach is challenging, especially for young neurosurgeon, and is determined by appropriate patient selection. However, this nondogmatic operative route to minimize brain transgression and retraction with a total lesional resection is the *sine qua none* philosophy to advance the field of microneurosurgery.

## Conclusion

We report an original minimal invasive approach for an intracranial meningioma, with a complete

resection (Simpson I) without any technical complication. This nontumor dominant side transfalcine approach brings new technical nuances for resection of falx or midline intracranial tumors.

## Declaration of patient consent

The authors certify that they have obtained all appropriate patient consent forms. In the form the patient(s) has/have given his/her/their consent for his/her/their images and other clinical information to be reported in the journal. The patients understand that their names and initials will not be published and due efforts will be made to conceal their identity, but anonymity cannot be guaranteed.

## Financial support and sponsorship

Nil.

## Conflicts of interest

There are no conflicts of interest.

## References

1. Simpson D. The recurrence of intracranial meningiomas after surgical treatment. *J Neurol Neurosurg Psychiatry* 1957;20:22-39.
2. Hattori K, Miyachi S, Kobayashi N, Kojima T, Hattori K, Negoro M, *et al.* Contralateral meningeal artery supply of paramedian meningiomas. *Surg Neurol* 2005;64:242-8.
3. Barajas RF Jr, Sughrue ME, McDermott MW. Large falx meningioma fed by callosomarginal branch successfully removed following contralateral interhemispheric approach. *J Neurooncol* 2010;97:127-31.
4. Mukherjee S, Minhas PS. Contralateral approach to resection of a parafalcine meningioma – A technical note. *Br J Neurosurg* 2014;28:699-700.
5. Ferroli P, Russo A, Albanese E, Tringali G, Broggi G. Gravity-aided trans-falcine removal of a contralateral subcortical ependymoma. *Acta Neurochir (Wien)* 2007;149:1147-50.
6. Mendez-Rosito D. The supra/infra transtentorial transfalcine approach for the removal of a falcotentorial meningioma: 2-dimensional video. *Oper Neurosurg (Hagerstown)* 2019;16:E166-7.
7. Liu JK, Cohen MA. Endoscopic-assisted posterior interhemispheric retrocallosal transfalcine approach for microsurgical resection of a pineal region falcotentorial meningioma: Operative video and technical nuances. *Neurosurg Focus* 2016;40 Video Suppl 1:2016.1.FocusVid. 15453.
8. Roser F, Rigante L. The endoscope-assisted contralateral paramedian approach to large falx meningiomas. *Acta Neurochir (Wien)* 2018;160:79-82.
9. Misra BK. Contralateral approach to the trigone of the lateral ventricle. *World Neurosurg* 2015;83:51.
10. Nehls DG, Marano SR, Spetzler RF. Transcallosal approach to the contralateral ventricle. Technical note. *J Neurosurg* 1985;62:304-6.
11. Zhu W, Xie T, Zhang X, Ma B, Wang X, Gu Y, *et al.* A solution to meningiomas at the trigone of the lateral ventricle using a contralateral transfalcine approach. *World Neurosurg* 2013;80:167-72.