

Functional outcome of surgically treated patients of ossified posterior longitudinal ligament of cervical and dorsal spine in Indian population – A single center retrospective analysis of 40 patients

Abstract

Aims: The aim of the study was to retrospectively evaluate the neurological outcome in operated patients of ossified posterior longitudinal ligament (OPLL) of cervical and/or dorsal spine using modified Japanese orthopedic association (mJOA) score and find out the factors affecting the outcome. **Settings and Design:** The study design was a retrospective study. **Materials and Methods:** Forty operated patients of cervical and/or dorsal spine OPLL were included in the study. Neurological examination was conducted and analyzed using mJOA score pre- and postoperatively at 1, 6, and 12 months. Improvement in the mJOA score based on age, sex, type of OPLL, duration of symptoms, type of surgical procedure, and radiological parameters were calculated, analyzed, and compared with previous records of the patient. **Results:** Significant improvement in mJOA scores with mean preoperative being 12.27 ± 1.95 with 1-year postoperative 13.85 ± 2.02 ($P < 0.0001$) noted. There is a significant difference in mean mJOA scores in posterior approach with instrumentation ($P < 0.0001$) as compared with laminoplasty group ($P < 0.005$). Patients with occupancy ratio $<60\%$ had better results ($P < 0.0001$) as compared to those with occupancy ratio of $>60\%$ ($P = 0.003$). Patients with duration of symptoms >1 year had poorer results compared to those of <1 year duration. Mean ossification kyphosis angle was $19.4^\circ \pm 5.73^\circ$. **Conclusion:** OPLL is a progressive disease which causes severe neurological deficit if left untreated. OPLL in a young patient with short duration of symptoms, low occupancy ratio, and low ossification kyphosis had better chances of neurological recovery. Type of OPLL and sex of patient do not affect the recovery. OPLL managed early and surgically has better results irrespective of anterior or posterior approach with significant improvement in mJOA score. Decompression with fusion has better results than decompression alone.

Keywords: Cervical and dorsal spine, modified Japanese orthopedic association score, occupancy ratio, ossification kyphosis angle, ossified posterior longitudinal ligament

Introduction

Ossification of posterior longitudinal ligament is a multifactorial disease characterized by calcification of posterior longitudinal ligament, leading to narrowing of spinal canal. Cervical spine is the most common region affected followed by dorsal spine [Figures 1 and 2]⁵. Tsuteimoto first described ossified posterior longitudinal ligament (OPLL) of cervical spine in 1960 [Figure 1]. OPLL is a common cause of cervical myelopathy in Asian population with incidence of 1.9%–4.3% as compared to western population of 0.1%–1.7%. It is rarely seen before third decade of life.^[1] According to Epstein, the distribution of OPLL is 70% in cervical

spine, 15% in upper and mid-thoracic, and 15% in upper lumbar spine. Cause of OPLL has been attributed to genetic and environmental factors.^[2,3] It has been classified based on pattern of ossification into segmental, continuous, mixed, and focal types [Figure 3]. Dorsal spine OPLL is of two types: flat type and beak type [Figure 4]. Symptoms are progressive due to stenosis, and early intervention is fruitful. Surgical decompression is frequently indicated in patients with cervical myelopathy due to OPLL. Anterior decompression typically consists of discectomy or corpectomy along with direct removal of the OPLL mass. Posterior approaches use an indirect decompression

Sudhir K Srivastava, Manojkumar Basavareddy Gaddikeri¹, Sunil Bhosale, Aditya Raj, Atif Naseem, Nandan Marathe²

Department of Orthopaedics, Seth GS Medical College and KEM Hospital, ²Assistant Professor, KEM Hospital, Mumbai ¹Assistant Professor, Rajawadi Hospital, Mumbai, Maharashtra, India

Address for correspondence: Dr. Manojkumar Gaddikeri, Department of Orthopaedics, Seth GS Medical College and KEM Hospital, Mumbai, Maharashtra, India. E-mail: mmano394@gmail.com

Access this article online

Website: www.asianjns.org

DOI: 10.4103/ajns.AJNS_477_20

Quick Response Code:



This is an open access journal, and articles are distributed under the terms of the Creative Commons Attribution-NonCommercial-ShareAlike 4.0 License, which allows others to remix, tweak, and build upon the work non-commercially, as long as appropriate credit is given and the new creations are licensed under the identical terms.

For reprints contact: WKHLRPMedknow_reprints@wolterskluwer.com

How to cite this article: Srivastava SK, Gaddikeri MB, Bhosale S, Raj A, Naseem A, Marathe N. Functional outcome of surgically treated patients of ossified posterior longitudinal ligament of cervical and dorsal spine in Indian population – A single center retrospective analysis of 40 patients. Asian J Neurosurg 2021;16:738-44.
Submitted: 21-Oct-2020 Revised: 25-Nov-2020
Accepted: 10-Apr-2021 Published: 18-Dec-2021

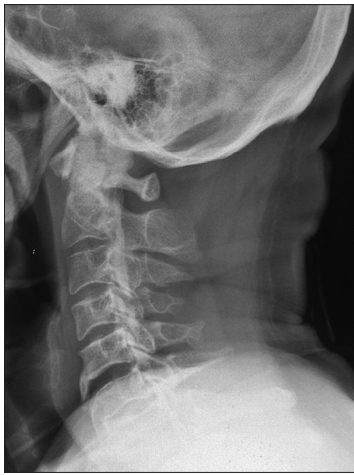

Figure 1: X-ray showing cervical spine ossified posterior longitudinal ligament

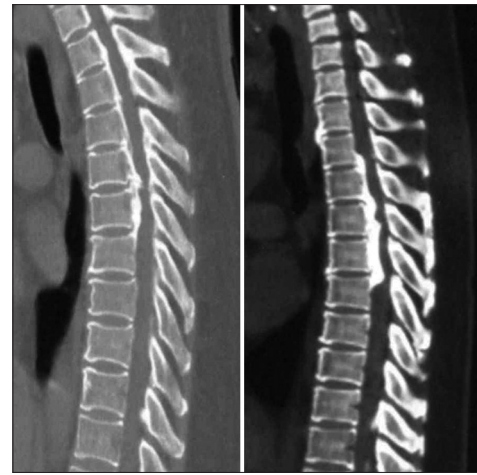

Figure 2: Computed tomography scan showing ossified posterior longitudinal ligament of dorsal spine

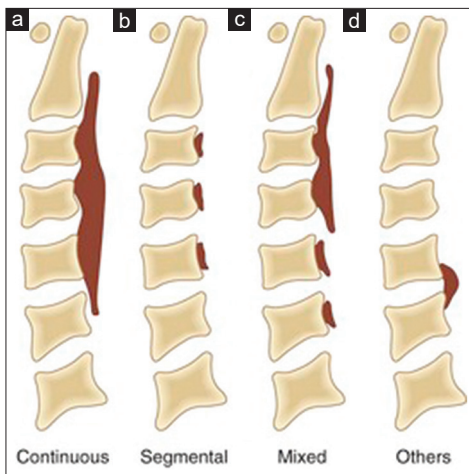


Figure 3: Types of cervical ossified posterior longitudinal ligament (a) continuous type. (b) segmental type. (c) mixed type. (d) others

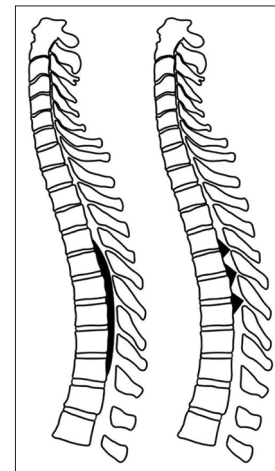


Figure 4: Types of thoracic ossified posterior longitudinal ligament

through either laminoplasty or laminectomy.^[4-7] Anterior decompression and direct removal of OPLL seem to be radical, because the major pathomechanism of OPLL is anterior compression of the spinal cord; moreover, some authors have shown the benefit of anterior decompression in cases with a high occupying ratio of OPLL. However, the procedure is more complicated and prone to high risk of complications. Posterior decompression is the preferred choice of surgical treatment for cervical OPLL in many institutes. For it is a relatively safer procedure and can provide extensive decompression of segments more easily. However, such an approach has a risk of OPLL progression and limited effectiveness in cases of OPLL with severe kyphotic deformity.^[8-10] The purpose of the study is to evaluate the neurological improvement in operated patients of OPLL using modified Japanese Orthopaedic Association (mJOA) score [Figure 5].

Materials and Methods

This study is a single-center retrospective analysis of forty patients of cervical and/or dorsal spine OPLL operated

and were followed up postoperatively for at least 1 year. The neurological recovery was serially evaluated using modified JOA scores during immediate postoperative period, at 1 month, 6 months, and 1 year successively and compared with preoperative mJOA scores. Patients with inadequate follow-up and cases of myelopathy other than OPLL were excluded from the study. Plain X-ray, computed tomography (CT), and magnetic resonance imaging (MRI) scans were taken preoperatively and were analyzed for K-line, occupancy ratio, and Ossification-Kyphosis angle [Figure 6]. Dynamic lateral flexion-extension X-rays were taken in all patients preoperatively to look for signs of instability and to decide on instrumentation. Postoperatively, radiological assessment was done using X-rays taken immediate postoperative, at 1 month, 3 months, 6 months, and 1 year and were analyzed for fixation status, loss of correction, and worsening of kyphosis. Postoperatively, if required CT and MRI scans were repeated in cases of no improvement or worsening of symptoms. All participants of the study have given written consent to participate in the study. The study was in accordance with the ethical

Score	Definition
Motor dysfunction	
Upper extremities	
0	Unable to move hands
1	Unable to eat with a spoon, but able to move hands
2	Unable to button shirt, but able to eat with a spoon
3	Able to button shirt with great difficulty
4	Able to button shirt with slight difficulty
5	Able to button shirt, but has difficulty in tearing roti/chapaathi and/or scooping rice from the plate
6	No dysfunction
Lower extremities	
0	Complete loss of motor and sensory function
1	Sensory preservation without ability to move legs
2	Able to move legs, but unable to walk
3	Able to walk on flat floor with a walking aid (cane or crutch)
4	Able to walk unaided, but requires vertical support to get up from squatting or sitting on the ground
5	Able to walk up and/or downstairs with the aid of a handrail
6	Mild difficulty in walking, but not having difficulty as in 4 or 5 above
7	No dysfunction
Sensory dysfunction	
Upper extremities	
0	Complete loss of hand sensation
1	Severe sensory loss or pain
2	Mild sensory loss
3	No sensory loss
Sphincter dysfunction	
0	Unable to micturate voluntarily
1	Marked difficulty in micturition
2	Mild-to-moderate difficulty in micturition
3	Normal micturition

Figure 5: Modified Japanese Orthopedic Association score

standards of our institutional ethics committee and with the Helsinki declaration of 1975 and has been approved by the institutional review board and institutional ethics committee (ref no: 019020/2019).

Surgical technique

Anterior approach to cervical spine

Anterior approach was considered in patients who are K-line negative with high occupancy ratio. All patients were operated by Smith-Robinson anterior approach technique from left side. Anterior corpectomy or discectomy was done as per the severity of OPLL, thorough cord and root decompression was done. In cases with double dura sign, resection of OPLL mass was attempted using surgical burr. In cases where OPLL mass was found to be adherent to dura, OPLL mass was released from surrounding

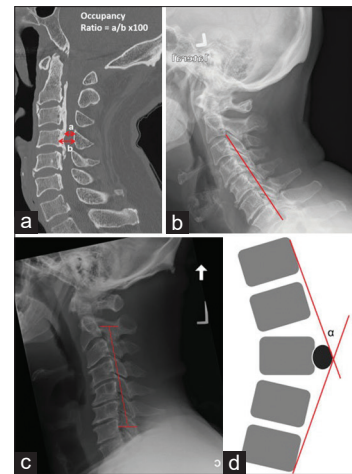


Figure 6: Radiological parameters used in ossified posterior longitudinal ligament. (a) Occupancy ratio. (b) K-line positive ossified posterior longitudinal ligament. (c) K-line negative ossified posterior longitudinal ligament. (d) Ossification Kyphosis angle used in dorsal spine ossified posterior longitudinal ligament

structures and left as floating islands. Reconstruction was done in most cases using iliac crest autograft, and in few cases, Titanium cages were used, and stabilization was achieved using locking anterior cervical plate of appropriate length.^[11-12]

Posterior approach to cervical and dorsal spine

Posterior approach was considered in patients with a positive K-line and low occupancy ratio. In dorsal spine, posterior approach was done in those with Ossification-Kyphosis angle of $<23^\circ$. All of our dorsal OPLL patients were qualified for posterior approach. Standard mid-line posterior approach was used after elevating the paraspinal muscles and achieving hemostasis screws were inserted in indicated cases which was decided based on instability seen on preoperative lateral flexion-extension X-rays. Open door laminoplasty and cord decompression were done in all patients and laminoplasty was fixed using bone graft harvested from iliac crest and local graft.^[13,14] Mobilization was done after drain removal on day 3.

Results

In the above study of forty patients, 35 were male and 5 female presenting with OPLL of cervical spine in 40 patients, OPLL of cervical and dorsal spine in eight patients. The mean preoperative mJOA score was 12.27 ± 1.95 and mean postoperative mJOA score of 12.8 ± 2.04 at 1 month postoperative, 13.85 ± 2.02 at 6 months, and 13.85 ± 2.02 at 1 year postoperative. The improvement in mJOA scores at 1-year postoperative compared to preoperative is statistically significant ($P < 0.0001$). Among various types of OPLL, mixed type constituted 52.5% followed by segmental type 35%, continuous 7.5%, and focal type 5%. Mean occupancy ratio was 59.85 ± 9.02 . Mean ossification

kyphosis angle was $19.4^\circ \pm 5.73^\circ$ with mean mJOA score of 12.63 ± 2.44 preoperatively, 13 ± 2.56 at 1 month postoperative, 14 ± 1.85 at 6 months, and 14 ± 1.85 at 1-year postoperative ($P = 0.073$). Of the forty patients, 26 had K-line positive OPLL and 14 K-line negative.

Out of forty patients, ten were operated by anterior approach and thirty patients by posterior approach. Of those operated by posterior approach, eight patients had coexisting cervical and dorsal spine OPLL and 22 patients had isolated cervical spine OPLL. All 10 patients operated by anterior approach had isolated cervical spine OPLL. All patients with dorsal spine OPLL qualified for posterior approach and hence none of them required anterior transthoracic approach.

Decompression with instrumented fusion was done in 25 patients and isolated decompression was performed in 15 patients. Mean mJOA scores in those operated by anterior approach were 12.9 ± 0.99 preoperatively and 14.3 ± 2.21 on 1-year postoperative ($P < 0.021$). Mean mJOA score in posterior approach with instrumentation was 11.87 ± 2.06 preoperatively and 13.8 ± 1.89 at 1-year follow-up ($P < 0.0001$), whereas in posterior approach without instrumentation mean mJOA score was 12.27 ± 2.28 preoperatively and 13.6 ± 2.09 at 1-year follow-up ($P = 0.005$). However, we could not find significant difference in postoperative mJOA scores between laminoplasty and instrumented group ($P = 0.786$). Out of forty patients of OPLL, eight had OPLL of cervical and dorsal spine with mean ossification kyphosis angle being $19.4^\circ \pm 5.73^\circ$. Mean preoperative mJOA score was 12.63 ± 2.44 , and mean scores at 1-year postoperative were 14 ± 1.85 . There was no statistically significant recovery ($P = 0.073$). All the patients were operated by posterior decompression. Mean mJOA score in those with occupancy ratio of $<60\%$ was 12.63 ± 1.89 preoperatively and 14.36 ± 2.06 at 1-year follow-up ($P < 0.0001$), and in those with occupancy ratio $>60\%$ mean mJOA score was 11.83 ± 1.97 preoperative and 13.22 ± 1.83 at 1-year follow-up ($P = 0.003$). The above shows that there are better results in those with low occupancy ratio. There is a significant improvement in mJOA scores in those with short duration of symptoms <1 year ($P < 0.0001$) as compared to those with longer duration of symptoms >1 year ($P = 0.002$).

The statistical analysis was performed by SPSS 23.0 version. Continuous variables were described as mean and variation of each observation from the mean value (standard deviation) represented as mean \pm standard deviation categorical variables were described by taking percentages. Independent *t*-test was used for finding out the association between continuous variables. Paired *t*-test was used to find out association at different intervals in the same patients. $P < 0.05$ was considered statistically significant.

Discussion

In the above study of forty patients, cervical and/or dorsal OPLL was selected, of which 35 were male and 5 female. In accordance with a study by Choi *et al.*,^[15] OPLL is more common in men compared to women, the prevalence in their studies is male-to-female ratio of 2:1, but in our study, the ratio is 7:1 indicating that, in Indian population, OPLL is far more common in men.

Of the forty patients, 32 had OPLL of cervical spine and eight patients had OPLL of cervical and dorsal spine. In our study, the prevalence of OPLL in cervical spine is 80% and in dorsal spine is 20% which goes in accordance with other studies. In the study conducted by Hirai *et al.*,^[16] it was found that 56.2% had coexistence of OPLL cervical and dorsolumbar spine, while in our study, the prevalence was 20%. Cervical OPLL is more common in men, whereas OPLL in multiple regions is more common in female population.^[16] Whereas in our study, it was found that OPLL in multiple regions was more common in men than women, out of eight patients with OPLL in multiple regions, seven were male and one female.

On preoperative clinical examination, it was found that, out of forty patients, all forty had paresthesia of upper and lower limbs, neck pain in 39 (97.5%), radiculopathy in 11 patients (27.5%), and spasticity in 24 patients (60%) and none had bowel or bladder involvement. From our study, it is seen that paresthesia is common finding in a patient of OPLL. In a study conducted by Raykar *et al.*,^[11] neck pain was found to be more common complaint than radiculopathy. Postoperatively, there was symptomatic relief in all forty patients with improvement in paresthesia, neck pain, and radiculopathy seen by 3 months and spasticity was relieved by 6 months in all 40 patients. No bowel bladder involvement was seen pre and postoperatively.

Among the types of OPLL, it was seen that, out of 40 patients of cervical OPLL, mixed type of OPLL was seen in 21 patients (52.5%), segmental type in 14 patients (35%), and continuous type in three patients (7.5%) and focal type in two patients (5%). This goes in accordance with a study conducted by Raykar *et al.*^[11] who also found that mixed type of OPLL is more common followed by segmental, continuous, and focal type.

Among the radiological parameters, K-line was positive in 26 patients (65%) and negative in 14 patients (35%). K-line measures the lordosis of cervical spine by line drawn from mid-point of C2 spinal canal to mid-point of C7 spinal canal. K-line helps to decide the approach to be used and also chances of developing postoperative kyphosis. Out of 26 patients with K-line positive, 22 were operated by posterior approach and 4 were operated by anterior approach. Out of 14 patients with K-line negative, six were operated by anterior approach and eight were operated by posterior approach. In accordance with the study

conducted by Mehdi SK *et al.*,^[17] it was found that patients with K-line positive needs to be operated by posterior approach and had higher postoperative mJOA scores when supplemented by fusion. Anterior approach can also be used in patients with K-line positive. K-line-negative patients had significant neurological recovery when operated by anterior and posterior fusion surgery and had worse outcomes when treated by laminoplasty line. The study found that, for patients with K-line -ve OPLL, which indicates thick ossification foci and/or kyphotic alignment, the bowstringing effect of laminoplasty is ineffective and results in insufficient decompression. They also found progression of kyphosis in patients with K-line negative treated by laminoplasty.

Mean occupancy ratio in our study was $59.85\% \pm 9.02\%$ (range = 44%–76%). Out of forty patients, 22 patients had occupancy ratio <60% and 18 patients having occupancy ratio $\geq 60\%$. It was found that prevalence of myelopathy in patients with occupancy ratio of >60% was found to be 100% in a study by Abiola *et al.*^[18] In patients with occupancy ratio <60% ($n = 22$), mean preoperative mJOA score was 12.63 ± 1.89 , and mean postoperative scores at 3 months were 14.36 ± 2.06 . The recovery was found to be statistically significant ($P < 0.0001$). In patients with occupancy ratio $\geq 60\%$, the mean preoperative mJOA score was 11.83 ± 1.97 and score at 3 months postoperative was 13.22 ± 1.83 . The recovery was found to be statistically significant ($P = 0.003$). From the above, it is seen that patients with preoperative occupancy ratio of <60% had better neurological recovery as compared to those with occupancy ratio $\geq 60\%$. This goes in accordance with the study conducted by Li *et al.*^[19] where they found that patients with higher occupancy ratio, higher residual ratio had poor outcome.

Out of forty patients, 18 had duration of symptoms ≤ 1 year and 22 had duration of >1 year. Mean preoperative mJOA score in patients with duration ≤ 1 year was 12.83 ± 1.42 and mean score at 6 months postoperative was 14.83 ± 1.75 . The recovery rate was found to be statistically significant ($P < 0.0001$). Mean preoperative mJOA score in patients with duration ≤ 1 year was 11.82 ± 2.22 , and mean score at 3-month postoperative was 13.04 ± 1.89 . The recovery rate was found to be statistically significant ($P = 0.002$). It was found from our study that patients with duration of symptoms ≤ 1 year had more recovery compared to those presenting late with >1-year duration of symptoms. This goes in accordance with the study conducted by Baaj AA *et al.*^[20] where they reviewed poor prognostic factors in OPLL and found that longer the duration of symptoms poorer are the results.

The mean preoperative mJOA score of forty patients was 12.27 ± 1.95 , mean postoperative mJOA score was 12.8 ± 2.04 at 1 month and 13.85 ± 2.02 at 6 months and 13.85 ± 2.02 at 1 year postoperative. The above scores

are irrespective of the approach and type of surgery done. Severity of myelopathy according to mJOA score is graded as mild if score is 15 or more, moderate if scores between 12 and 14, and scores <12 as severe myelopathy. In our study, it was found that eight patients had scores below 12.28 patients had scores between 12 and 14 and four patients above 15. Mean postoperative mJOA score was 12.8 ± 2.04 at 1 month and 13.85 ± 2.02 at 6 months postoperative. The improvement in the mJOA score was statistically significant at 6 months postoperative when compared with the preoperative mJOA score ($P < 0.0001$).

Of the forty patients, thirty were operated by posterior approach and ten by anterior approach. In the anterior approach group, the mean preoperative mJOA score was 12.9 ± 0.99 and mean postoperative mJOA score was 14.3 ± 2.21 at 1 year. The improvement in mJOA score was found to be statistically significant ($P = 0.021$). Of the 10 operated by anterior approach, all of the 10 were treated by corpectomy and fusion by anterior cervical plating and bone grafting. Single level corpectomy in two patients, two level corpectomy in seven patients, and three level corpectomy in one patient. The above results are in accordance with the study conducted by Feng *et al.*^[21] where they found significant improvement in the neurology in patients operated by anterior corpectomy and fusion.

Out of thirty patients operated by posterior approach, 15 patients were treated by laminoplasty and 15 patients were treated by laminectomy supplemented by fusion by instrumentation. The mean preoperative mJOA score was 12.06 ± 2.15 and 13.7 ± 1.96 at 6 months and 13.7 ± 1.96 at 1 year postoperative. There was significant neurological recovery postoperatively ($P < 0.0001$).

In patients operated by laminoplasty, mean preoperative mJOA score was 12.27 ± 2.28 and the scores at 1 year postoperative was 13.6 ± 2.09 . The neurological recovery was found to be significant ($P = 0.005$).

In patients operated by laminectomy and fusion by instrumentation, mean preoperative mJOA score was 11.87 ± 2.06 and scores at 1 year postoperative was 13.8 ± 1.89 . The neurological recovery was found to be significant ($P < 0.0001$).

From the above, it can be seen that the neurological recovery as calculated by mJOA is more in instrumented group as compared to laminoplasty group. This goes in accordance with studies conducted by Feng *et al.*^[5] and Mehdi *et al.*^[17] where they found higher recovery with instrumented group when compared with laminoplasty group.

Out of forty patients of OPLL, 8 had OPLL of cervical and dorsal spine with mean ossification kyphosis angle being $19.4^\circ \pm 5.73^\circ$. Mean preoperative mJOA score was 12.63 ± 2.44 and mean scores at 1-year postoperative was 14 ± 1.85 . There was no statistically significant

recovery ($P = 0.073$). All the patients were operated by posterior decompression in accordance with a study conducted by Uei *et al.*,^[22] Abiola *et al.*,^[18] and Baaj *et al.*^[20] where they found that ossification kyphosis angle of $\leq 23^\circ$ must be operated by posterior decompression and angle $>23^\circ$ needs anterior decompression. They found better recovery and lower recurrence rates with posterior decompression and fusion as compared to decompression alone. Results of surgical treatment of dorsal spine OPLL are poorer as compared to that of cervical spine. Factors responsible for poorer outcome as described by Kalb *et al.*^[23] are:

- a. Natural kyphosis of dorsal spine prevents posterior translation of the spinal cord after laminectomy, thereby decreasing its effectiveness
- b. Poor vascularity of the spinal cord at the site of compression.

The neurological recovery in forty operated patients of OPLL of cervical and/or dorsal spine was found to be poor in 13 patients, fair in 11 patients, good in 10 patients, and excellent in six patients. Neurological recovery is calculated using the formula used by Li *et al.*^[19] in their study on potential risk factors for poor outcome after anterior surgery in patients of OPLL. In their study, they found that many factors were accounting for poor outcome such as age, duration of symptoms, type of OPLL, location of OPLL, number of segments involved, coexistence of other degenerative conditions, comorbidities, preoperative neurology, type of approach used, and instrumented fusion.^[24,25]

Conclusion

Based on our retrospective study, the results were satisfactory in terms of postoperative mJOA scores irrespective of surgical approach. We could not find significant difference in postoperative mJOA scores between instrumented and laminoplasty group. Studies show that decompression alone led to increase in kyphosis and progression of OPLL. Outcome in our study was found to be dependent on preoperative mJOA score, duration of symptoms, occupancy ratio, and surgical techniques. Factors not affecting the outcome were sex of the patient, type of OPLL, and number of levels involved. Ossification of posterior longitudinal ligament is a progressive disease with variable presentation which if tackled early has better outcomes.

Financial support and sponsorship

Nil.

Conflicts of interest

There are no conflicts of interest.

References

1. Raykar R, Bettaswamy G, Singh R. Retrospective and prospective analysis of clinical, radiological and prognostic factors affecting surgical denouement in ossified posterior longitudinal ligament: an institutional experience. *International surgery journal*. 2019;6(3). DOI: <http://dx.doi.org/10.18203/2349-2902.isj20190518>
2. Matsunaga S, Sakou T. Ossification of the posterior longitudinal ligament of the cervical spine: etiology and natural history. *Spine (Phila Pa 1976)*. 2012 Mar 1;37(5):E309-14. doi: 10.1097/BRS.0b013e318241ad33. PMID: 22146284.
3. Yan L, Gao R, Liu Y, He B, Lv S, Hao D. The Pathogenesis of Ossification of the Posterior Longitudinal Ligament. *Aging Dis*. 2017 Oct 1;8(5):570-582. doi: 10.14336/AD.2017.0201. PMID: 28966802; PMCID: PMC5614322.
4. Li H, Jiang LS, Dai LY. A review of prognostic factors for surgical outcome of ossification of the posterior longitudinal ligament of cervical spine. *Eur Spine J*. 2008 Oct;17(10):1277-88. doi: 10.1007/s00586-008-0740-8. Epub 2008 Aug 14. PMID: 18704517; PMCID: PMC2556477.
5. Masaki Y, Yamazaki M, Okawa A, Aramomi M, Hashimoto M, Koda M, *et al.* An analysis of factors causing poor surgical outcome in patients with cervical myelopathy due to ossification of the posterior longitudinal ligament: anterior decompression with spinal fusion versus laminoplasty. *J Spinal Disord Tech*. 2007 Feb;20(1):7-13. doi: 10.1097/01.bsd.0000211260.28497.35. PMID: 17285045.
6. Yudoyono F, Cho PG, Park SH, Moon BJ, Yi S, Ha Y, *et al.* Factors associated with surgical outcomes of cervical ossification of the posterior longitudinal ligament. *Medicine (Baltimore)*. 2018 Jul;97(29):e11342. doi: 10.1097/MD.00000000000011342. PMID: 30024507; PMCID: PMC6086522.
7. Muzumdar D. Surgery for multilevel cervical spondylotic myelopathy and ossified posterior longitudinal ligament. *Neurol India*. 2016 Jan-Feb;64(1):16-8. doi: 10.4103/0028-3886.173630. PMID: 26754984.
8. Hou Y, Liang L, Shi GD, Xu P, Xu GH, Shi JG, *et al.* Comparing effects of cervical anterior approach and laminoplasty in surgical management of cervical ossification of posterior longitudinal ligament by a prospective nonrandomized controlled study. *Orthop Traumatol Surg Res*. 2017 Sep;103(5):733-740. doi: 10.1016/j.otsr.2017.05.011. Epub 2017 Jun 12. PMID: 28619269.
9. Kommu R, Sahu BP, Purohit AK. Surgical outcome in patients with cervical ossified posterior longitudinal ligament: A single institutional experience. *Asian J Neurosurg*. 2014 Oct-Dec;9(4):196-202. doi: 10.4103/1793-5482.146602. PMID: 25685216; PMCID: PMC4323963.
10. Koda M, Mochizuki M, Konishi H, Aiba A, Kadota R, Inada T, *et al.*, Furuya T. Comparison of clinical outcomes between laminoplasty, posterior decompression with instrumented fusion, and anterior decompression with fusion for K-line (-) cervical ossification of the posterior longitudinal ligament. *Eur Spine J*. 2016 Jul;25(7):2294-301. doi: 10.1007/s00586-016-4555-8. Epub 2016 Apr 13. PMID: 27072553.
11. Mizuno J, Nakagawa H. Outcome analysis of anterior decompressive surgery and fusion for cervical ossification of the posterior longitudinal ligament: report of 107 cases and review of the literature. *Neurosurg Focus*. 2001 Apr 15;10(4):E6. doi: 10.3171/foc.2001.10.4.7. PMID: 16732633.
12. Chen Y, Yang L, Liu Y, Yang H, Wang X, Chen D. Surgical results and prognostic factors of anterior cervical corpectomy and fusion for ossification of the posterior longitudinal ligament. *PLoS One*. 2014 Jul 7;9(7):e102008. doi: 10.1371/journal.pone.0102008. PMID: 25000183; PMCID: PMC4084983.
13. Meyer SA, Wu JC, Mummaneni PV. Laminoplasty outcomes: is there a difference between patients with degenerative stenosis and those with ossification of the posterior longitudinal

- ligament? *Neurosurg Focus*. 2011 Mar;30(3):E9. doi: 10.3171/2011.1.FOCUS10279. PMID: 21361755.
14. Maruo K, Moriyama T, Tachibana T, Inoue S, Arizumi F, Daimon T, *et al.* The impact of dynamic factors on surgical outcomes after double-door laminoplasty for ossification of the posterior longitudinal ligament of the cervical spine. *J Neurosurg Spine*. 2014 Dec;21(6):938-43. doi: 10.3171/2014.8.SPINE131197. Epub 2014 Oct 3. PMID: 25279653.
 15. Choi BW, Song KJ, Chang H. Ossification of the posterior longitudinal ligament: a review of literature. *Asian Spine J*. 2011 Dec;5(4):267-76. doi: 10.4184/asj.2011.5.4.267. Epub 2011 Nov 28. PMID: 22164324; PMCID: PMC3230657.
 16. Hirai T, Yoshii T, Iwanami A, Takeuchi K, Mori K, Yamada T, *et al.* Prevalence and Distribution of Ossified Lesions in the Whole Spine of Patients with Cervical Ossification of the Posterior Longitudinal Ligament A Multicenter Study (JOSL CT study). *PLoS One*. 2016 Aug 22;11(8):e0160117. doi: 10.1371/journal.pone.0160117. PMID: 27548354; PMCID: PMC4993375.
 17. Mehdi SK, Alentado VJ, Lee BS, Mroz TE, Benzel EC, Steinmetz MP. Comparison of clinical outcomes in decompression and fusion versus decompression only in patients with ossification of the posterior longitudinal ligament: a meta-analysis. *Neurosurg Focus*. 2016 Jun;40(6):E9. doi: 10.3171/2016.3.FOCUS1630. PMID: 27246492.
 18. Abiola R, Rubery P, Mesfin A. Ossification of the Posterior Longitudinal Ligament: Etiology, Diagnosis, and Outcomes of Nonoperative and Operative Management. *Global Spine J*. 2016 Mar;6(2):195-204. doi: 10.1055/s-0035-1556580. Epub 2015 Jun 30. PMID: 26933622; PMCID: PMC4771496.
 19. Li S, Zhang P, Gao X, Miao D, Gao Y, Shen Y. Potential risk factors for poor outcome after anterior surgery for patients with cervical ossification of the posterior longitudinal ligament. *Ther Clin Risk Manag*. 2018 Feb 20;14:341-347. doi: 10.2147/TCRM.S152416. PMID: 29503553; PMCID: PMC5824755.
 20. Baaj AA, Smith DA, Vale FL, Uribe JS. Surgical approaches to thoracic ossification of the posterior longitudinal ligament. *J Clin Neurosci*. 2012 Mar;19(3):349-51. doi: 10.1016/j.jocn.2011.05.025. Epub 2012 Jan 16. PMID: 22249019.
 21. Feng F, Ruan W, Liu Z, Li Y, Cai L. Anterior versus posterior approach for the treatment of cervical compressive myelopathy due to ossification of the posterior longitudinal ligament: A systematic review and meta-analysis. *Int J Surg*. 2016 Mar;27:26-33. doi: 10.1016/j.ijssu.2016.01.038. Epub 2016 Jan 19. PMID: 26804354.
 22. Uei H, Tokuhashi Y, Oshima M, Maseda M, Nakahashi M, Nakayama E. Efficacy of posterior decompression and fixation based on ossification-kyphosis angle criteria for multilevel ossification of the posterior longitudinal ligament in the thoracic spine. *J Neurosurg Spine*. 2018 Aug;29(2):150-156. doi: 10.3171/2017.12.SPINE17549. Epub 2018 May 4. PMID: 29726802.
 23. Matsuyama Y, Yoshihara H, Tsuji T, Sakai Y, Yukawa Y, Nakamura H, *et al.* Surgical outcome of ossification of the posterior longitudinal ligament (OPLL) of the thoracic spine: implication of the type of ossification and surgical options. *J Spinal Disord Tech*. 2005 Dec;18(6):492-7; discussion 498. doi: 10.1097/01.bsd.0000155033.63557.9c. PMID: 16306836.
 24. McClendon J Jr, Sugrue PA, Ganju A, Koski TR, Liu JC. Management of ossification of the posterior longitudinal ligament of the thoracic spine. *Neurosurg Focus*. 2011 Mar;30(3):E16. doi: 10.3171/2010.12.FOCUS10282. PMID: 21361754.
 25. Kalb S, Martirosyan NL, Perez-Orribo L, Kalani MY, Theodore N. Analysis of demographics, risk factors, clinical presentation, and surgical treatment modalities for the ossified posterior longitudinal ligament. *Neurosurg Focus*. 2011 Mar;30(3):E11. doi: 10.3171/2010.12.FOCUS10265. PMID: 21361749.