

# Central Nervous System Tuberculoma in the Corpus Callosum Mimicking a Butterfly Glioma: Literature Review of Radiological Findings and Our Experience

## Abstract

**Context:** Central nervous system (CNS) tuberculoma is the most common form of intracranial parenchymal tuberculosis (TB) which accounts for approximately 40% of misdiagnosed brain lesions mimicking intracranial tumors. The most common sites are the cerebral hemispheres, basal ganglia, cerebellum, and brainstem. **Materials and Methods:** Radiological findings of corpus callosum tuberculomas have been described and set in relation with the available literature. **Results:** Corpus callosum tuberculomas are extremely rare, with only five cases reported in the current literature. Even though isolated CNS tuberculoma of the corpus callosum without systemic TB in immunocompetent patients occurs rarely, as in our case, it should be considered in the differential diagnosis of solitary corpus callosum lesions. **Conclusions:** Careful evaluation of the neuroradiological images with adequate clinoradiological correlation allows for accurate diagnosis and ensures the proper and timely care.

**Keywords:** Central nervous system, corpus callosum lesion, intracranial tuberculosis, tuberculoma

## Introduction

Tuberculosis (TB) is the clinical manifestation of the infection caused by *Mycobacterium tuberculosis* with high morbidity and mortality reported each year. In recent years, the infection has shown a re-emergent role even in non-endemic areas with the diffusion of acquired immunodeficiency syndrome and increasing immigration from developing nations.

Central nervous system (CNS) involvement is a rare but dramatic consequence of the infection and it accounts for roughly 1% of all TB cases and about 15% of the extrapulmonary TB cases. Tuberculoma is the most common form of intracranial parenchymal TB which accounts for approximately 40% of misdiagnosed brain lesions mimicking intracranial tumors.<sup>[1]</sup>

Even if isolated CNS tuberculomas of the corpus callosum without systemic TB, as in our case, are exceptional, they are usually misdiagnosed.

The authors present a case of a CNS tuberculoma in the corpus callosum

mimicking a butterfly glioma with no signs of systemic TB in immunocompetent patient. A review of scientific literature has been performed, analyzing radiological features of corpus callosum tuberculomas with the aim to raise awareness about taking into account intracranial tuberculomas as a differential diagnosis in the solitary lesion of the corpus callosum.

## Materials and Methods

### Review of literature

We present a literature review using the National Library of Medicine based on the keywords: “tuberculoma,” “intracranial TB,” “corpus callosum lesion,” and “CNS.” Only English reports were considered. Among 157 articles, only 4 manuscripts describe a single TB lesion in the corpus callosum.<sup>[2-5]</sup>

### Case report

A 44-year-old Senegalese man was admitted to our department of neurological surgery complaining of headache, progressive confusion, memory impairment, behavior

## Claudia Scudieri<sup>1,2</sup>, Fotios Kalfas<sup>3</sup>

<sup>1</sup>Department of Neurosurgery and Gamma Knife Radiosurgery, IRCCS San Raffaele Scientific Institute, Vita-Salute University, Milan, <sup>2</sup>Department of Neurological Surgery, Galliera Hospitals, Genova, <sup>3</sup>Department of Neurosurgery Padua University Hospital, Padua, Italy

### Address for correspondence:

Dr. Claudia Scudieri,  
Department of Neurosurgery  
and Gamma Knife Radiosurgery,  
IRCCS San Raffaele Scientific  
Institute, Vita-Salute University,  
Via Olgettina, 60 20132,  
Milan Italy.  
E-mail: claudiascudieri@gmail.  
com

### Access this article online

Website: [www.asianjns.org](http://www.asianjns.org)

DOI: 10.4103/ajns.AJNS\_482\_20

### Quick Response Code:



**How to cite this article:** Scudieri C, Kalfas F. Central nervous system tuberculoma in the corpus callosum mimicking a butterfly glioma: Literature review of radiological findings and our experience. Asian J Neurosurg 2021;16:488-93.

Submitted: 27-Oct-2020

Revised: 23-Dec-2020

Accepted: 06-Mar-2021

Published: 14-Sep-2021

This is an open access journal, and articles are distributed under the terms of the Creative Commons Attribution-NonCommercial-ShareAlike 4.0 License, which allows others to remix, tweak, and build upon the work non-commercially, as long as appropriate credit is given and the new creations are licensed under the identical terms.

For reprints contact: WKHLRPMedknow\_reprints@wolterskluwer.com

disorder with tendency toward aggression, dysarthria, and right hemiparesis for a period of 2 weeks. The patient was immunocompetent, with no relevant past history; routine hematologic examination, serology tests, and chest radiography were normal. The patient denied any history of fever, TBC exposure, or respiratory tract infections.

The patient underwent brain magnetic resonance imaging (MRI) with and without contrast administration. The examination showed a lesion of the rostrum of the corpus callosum extended into the left frontal lobe, causing compression and dislocation of the frontal horn of the lateral ventricle and an initial subfalcine herniation. The lesion appeared on T1-weighted images (T1WI) after contrast administration (gadolinium) scans as hypointense with nonhomogeneous rim contrast enhancement. On T2-weighted sequences (T2WI), a central hypointense core surrounded by perilesional edema was distinctive [Figure 1a-e].

A high-grade “butterfly” glioma was suspected, given the young age of the patient, his clinical history, the symptoms, the physical examination, and the laboratories results. The patient underwent a left frontal craniotomy. Microscopical instrumentation was set. The dura was opened preserving the superior sagittal sinus. The tumor, coming on the medial surface of the left frontal lobe and originating

from the rostrum of the corpus callosum, appeared as a less vascular yellowish mass. Gross total resection was achieved. Postoperative computed tomography (CT) scan was uneventful [Figure 1f].

As shown in Figure 1a-e, preoperative coronal T1WI, without and after contrast administration, axial T1WI without and after contrast administration, and axial T2WI MRIs show lesion of the rostrum of the corpus callosum extended into the left frontal lobe, causing compression and dislocation of the frontal horn of the lateral ventricle. As shown in Figure 1f, postoperative CT scan shows tumor gross total resection.

Microscopic examination showed a caseous necrotic center surrounded by a granulomatous reaction that included epithelioid and Langhans giant cells.

The overall features of the specimen were sufficiently characteristic to suggest the diagnosis of intracranial tuberculoma. The Ziehl-Neelsen and periodic acid-Schiff stains did not demonstrate acid-fast bacilli and bacteriologic cultures were negative. Anti-TB treatment was immediately started with a five drug regimen (rifampin, isoniazid, ethambutol, moxifloxacin, and pyrazinamide).

The postoperative course was uneventful with no surgical morbidity and clinical improvement. The 2-month postoperative follow-up MRI showed complete regression of the lesion with complete resolution of the symptoms.

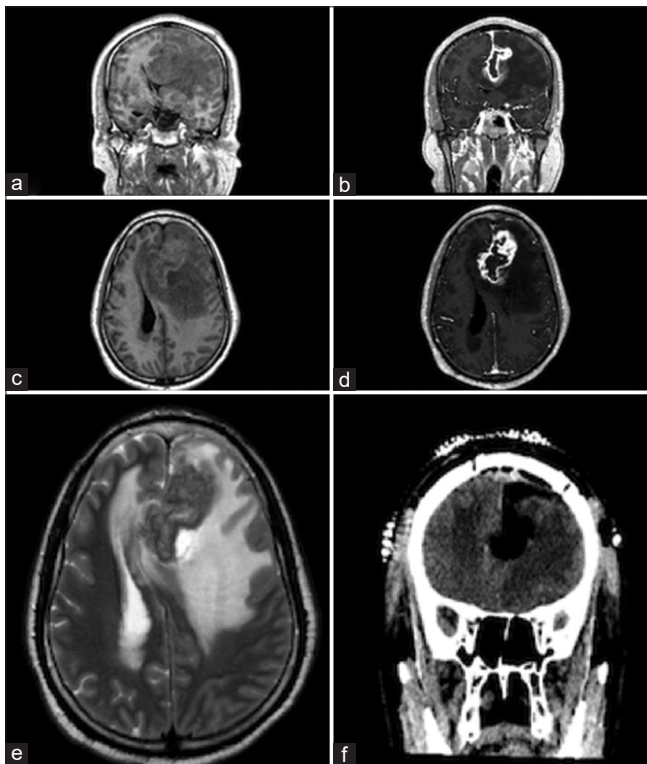
## Results

Table 1 shows detailed features of our literature review, included our case.

Montgomery<sup>[4]</sup> in 1933 described a case of 69-year-old man suffering from headache, dizziness, and weakness, especially in the left leg. Since in 1933 there were not any medical diagnostic devices such as CT or MRI, no information is available about the radiological features of the lesion. The diagnosis was achieved through postmortem autopsy which confirmed a lesion of the corpus callosum extended in the right frontal lobe of about 4 cm transversely and 2.25 cm vertically. This mass was composed of very soft material, which on the left had a red color, while on the right, it was yellowish white. Microscopic examination showed necrotic areas surrounded by cellular condensation arranged in a radial fashion suggesting a tubercle.

Brismar *et al.*<sup>[2]</sup> in 1996 analyzed all patients affected by intracranial tuberculomas misdiagnosed as brain tumors treated at their department. Among them, there were only 2 cases of intraparenchymal corpus callosum tuberculoma resembling a high-grade glioma.

First case a 16-year-old female presented 8-month history of headache and vomiting and 5-month history of retro-orbital pain and papilledema. CT scans described an isodense corpus callosum lesion with ipodense center with



**Figure 1:** (a-e) Preoperative coronal T1-weighted, without and after contrast administration, axial T1-weighted without and after contrast administration, axial T2-weighted magnetic resonance images showing lesion of the rostrum of the corpus callosum extended into the left frontal lobe, causing compression and dislocation of the frontal horn of the lateral ventricle. (f) Postoperative computed tomography scan shows tumor gross total resection

**Table 1: Corpus callosum tuberculomas: Clinical and radiological features, histological characteristics, treatment, and outcome**

Authors	Age (years)/sex	Clinical history/ neurological examination	Laboratories results	Radiological findings	Histopathological findings	Treatment and outcome
Montgomery 1933 <sup>[4]</sup>	69/male	Headache, dizziness, and weakness, especially in the left leg	NA	NA	Postmortem autopsy: Lesion of the corpus callosum extended in the right frontal lobe of about 4 cm transversely and 2.25 cm vertically. This mass is composed of very soft material, which on the left has a red colour, while on the right it is yellowish-white. This mass displaces the floors of the lateral ventricles upwards. Microscopic examination showed necrotic areas surrounded by cellular condensation arranged in a radial fashion suggesting a tubercle	Patient died
Brismar <i>et al.</i> 1996 <sup>[2]</sup>	16/female	8-months history of headache and vomiting 5-months history of retro-orbital pain and papilledema	NA	CT: Isodense corpus callosum lesion with ipodense center CT postcontrast: Irregular ring enhancement Cerebral angiography: Occlusion of left middle parietal Sylvian branches that fill in a retrograde fashion from posterior cerebral arteries	NA	Anti-TB medication (not specified). Good
Brismar <i>et al.</i> 1996 <sup>[2]</sup>	56/female	8-month history of back pain. 4-month history of mental changes 2-month history of inability to walk and incontinence. Intermittent fever	NA	CT: Isodense corpus callosum lesion with ipodense center surrounded by edema CT postcontrast: Irregular ring enhancement Cerebral angiography: Avascular mass lesion	NA	Surgery. Good
Fath-Ordoubadi <i>et al.</i> 1997 <sup>[3]</sup>	NA/male	Acute right-sided facial and limb weakness 2 weeks later sudden deterioration with increasing weakness, headache and dysphasia. Reflexes were exaggerated on the right, with a Babinski sign, and he exhibited a right sided grasp reflex	NA. A chest radiograph showed no evidence of pulmonary tuberculosis	CT: A single large, irregular enhancing lesion crossing the midline arising from the corpus callosum	A necrotizing, granulomatous inflammatory lesion. Ziehl-Neelsen staining confirmed the presence of acid-fast bacilli	300 mg isoniazid, 600 mg rifampacin, and 2 g pyrazinamide daily. Good

Contd...

Table 1: Contd...

Authors	Age (years)/sex	Clinical history/ neurological examination	Laboratories results	Radiological findings	Histopathological findings	Treatment and outcome
Psimaras <i>et al.</i> 2014 <sup>[5]</sup>	52/female	Asthenia, tremor, progressive fatigability, weakness in the left leg, bilateral occipital headaches with nausea and vomiting. Impaired central vision in the left eye, bilateral papilledema, ideomotor apraxia	Blood panel was normal. The patient was negative for HIV infection	MRI revealed a lesion with a mass effect involving the left side of the frontal lobe, crossing the corpus callosum, and displacing the ventricles and median line TIWI with Gd: Nonhomogeneous contrast enhancement and a central hypointense core T2WI peripheral hypersignal and a hypointense core Single-voxel spectroscopy (MRS) elevated choline peak, a decreased NAA and lipid peak Perfusion- weighted MRI: No focal elevation of the cerebral blood flow (rCBV) in the lesion	Granuloma with giant cells and central caseation. Positivity of <i>Mycobacterium tuberculosis</i> in culture	Anti-tuberculous therapy (isoniazid, rifampin, pyrazinamide, and ethambutol, plus steroids. Ethambutol and pyrazinamide were discontinued after 2 months). After 18 months of treatment, clinical examination was normal, follow up MRI showed near-complete regression of the lesion
Case report	44/male	2-weeks history of headache and confusion. Progressive onset of aggressive behavior and memory loss, dysphasia, and right hemiparesis	Blood panel was normal. Patient was negative for HIV infection; a chest radiograph showed no evidence of pulmonary tuberculosis	MRI: Lesion of the rostrum of the corpus callosum extended into the left frontal lobe, causing compression and dislocation of the frontal horn of the lateral ventricle and an initial subfalcine herniation. The lesion appeared in TIWI with Gd scans as hypointense with nonhomogeneous rim contrast enhancement In T2WI scans: A central hypointense core surrounded by perilesional edema	Lesion with caseous necrotic center surrounded by a granulomatous reaction that included epithelioid and Langhans giant cells. Ziehl-Neelsen and PAS stains did not demonstrate acid-fast bacilli and bacteriologic cultures were negative	The 2 - months postoperative follow-up MRI showed complete regression of the lesion with complete resolution of the symptoms

MRI – Magnetic resonance imaging; TIWI – T1-weighted image; T2WI – T2-weighted image; Gd – Gadolinium; NA – Not available; MRS – Magnetic resonance spectroscopy; CT – Computed tomography; NAA – N-acetylaspartate; PAS – Periodic acid–Schiff



irregular ring enhancement after contrast administration. Cerebral angiography showed an avascular lesion causing occlusion of left middle parietal Sylvian branches.

Similar radiological CT features were noted in a 56-year-old female admitted complaining of 4-month history of mental changes and intermittent fever and of 2-month history of inability to walk and incontinence.

Fath-Ordoubadi *et al.*<sup>[3]</sup> in 1997 described a single large with irregular enhancing lesion crossing the midline arising from the corpus callosum at CT scans in a middle-aged male patient with gradual onset of acute right-sided facial and limb weakness. Two weeks later, the patient developed sudden deterioration with increasing weakness, headache, and dysphasia.

Psimaras *et al.*<sup>[5]</sup> in 2014 first reported the MRI features of a lesion involving the left side of the frontal lobe, crossing the corpus callosum, and displacing the ventricles and median line. On T1WI after gadolinium administration, the lesion appeared defined by a central hypointense core with nonhomogeneous rim contrast enhancement. T2WI scans shows peripheral hypersignal and a hypointense core. T2WI sequences (T2WI) show a distinct central hypointense core surrounded by perilesional hyperintense signal due to perilesional edema. Single-voxel spectroscopy (MRS) confirmed the characteristic elevated choline peak and a decreased NAA and lipid peak.

## Discussion

CNS tubercular involvement is related to hematogenous spreading from a distant primary site, usually lungs to regions that are highly vascularized and oxygenated, such as the brain.

HIV infection or other acquired forms of immunosuppression significantly increase the risk for acquisition of TB, the rate of progression from latent to active disease, and TB-associated morbidity and mortality. In particular, extrapulmonary manifestations appear in 40% of HIV-infected patients with TB.<sup>[6]</sup> Nevertheless unexpected, CNS tuberculoma can affect also immunocompetent patients with normal routine hematologic examination, serology tests, and chest radiography as reported by the authors.

Most tuberculomas are found at the corticomedullary junction because of narrowing of the arterioles as they enter the white matter or develop from the extension of CSF infection into the adjacent parenchyma via cortical veins or perivascular Virchow–Robin spaces around small penetrating arteries.<sup>[7]</sup> These lesions are generally multiple and hemispheric and associated with enhancing exudates in basal and suprasellar cisterns, hydrocephalous with ventricular ependymal enhancement, focal or diffuse leptomeningeal enhancement, focal cerebritis, and infarcts.<sup>[8]</sup> In the adults, the lesions are predominantly

located supratentorially, while in the pediatric counterpart, they are mainly distributed infratentorially. The most common sites are cerebral hemispheres, basal ganglia, cerebellum, and brainstem.<sup>[9]</sup>

Although uncommon, intracranial tuberculomas can arise from the corpus callosum white matter and extend to the adjacent brain parenchyma. The lesion can appear as a large-size solitary lesion, as in our case, in recognition of the fact that cerebral tuberculoma has to reach a certain critical size in this location before producing symptoms of a space-occupying lesion. This process can take a long time explained by the fact that tuberculoma is the expression of a chronic inflammatory response to M. TB infection. In addition, cerebral tuberculoma could be the only pathological expression of CNS TB, making the radiological diagnosis more challenging.

Tuberculomas may also be variable in size. As long as there is no clear definition about the definition of “giant” tuberculoma, the authors agree with Kumar *et al.*<sup>[8]</sup> defining “giant” a lesion of more than 1 cm size. In our case, the lesion was 60 mm × 51 mm × 36 mm; Brismar *et al.*<sup>[2]</sup> did not report any information about size, but in their report, single lesions were typically of about 3 cm in diameter and surrounded by moderate or marked edema. In Montgomery’s report,<sup>[4]</sup> postmortem autopsy confirmed a lesion of about 4 cm transversely and 2.25 cm vertically.

In conclusion, the authors presented the largest corpus callosum tuberculoma described up to now.

At the moment of the clinical presentation and then of the diagnosis, analyzing, and comparing the radiological findings of our literature review,<sup>[2-5]</sup> the authors report that all CT scans showed an isodense corpus callosum lesion with ipodense central core; MRI revealed a lesion with a mass effect characterized by central hypointense core and nonhomogeneous contrast enhancement after gadolinium administration on T1WI images, while on T2WI scans, the corpus callosum tuberculoma appeared defined by peripheral hypersignal and a hypointense core surrounded by edema. All these features are consistent with the radiological findings of our case and are summarized in Table 1.

Pathologically, the initial lesion consists of a typical granuloma with epithelioid cells, Langhans giant cells, and a peripheral rim of lymphocytes called noncaseating tuberculoma. Central caseous necrosis and liquefaction develop in subsequent stages. Tuberculoma development occurs in four stages (noncaseating granuloma, caseating granuloma, caseating granuloma with central liquefaction, and calcified granuloma) and the MRI features change as well as the histopathology.

In the first “non caseating” stage, tuberculoma appears hyperintense on T2WI images, isointense or hypointense on T1, and shows nodular or ring enhancement on postcontrast studies.

Caseating tuberculomas are usually isointense or hypointense surrounded by a hyperintense rim on both T2WI and T1WI with rim contrast enhancement after gadolinium administration. The solid caseation core is high in lipid contents, with macrophage infiltration responsible for the T2WI hypointensity.

When liquefaction of the core occurs within a tuberculoma, it appears as a T2 hyperintense lesion with a peripheral hypointense rim. On T1WI images, the center is hypointense with rim enhancement on postcontrast studies.

In the final stage, tuberculomas often undergo calcification with a consensual reduction of the perilesional edema noticeable on T1WI and T2WI images by the lack of the peripheral hyperintensity and of rim enhancement.

On CT scan, occasionally, tuberculomas show up a central calcification surrounded by a hypodense area; this pattern defines that “target sign” is highly suggestive of TB, although not specific.<sup>[10]</sup>

MRI is highly sensitive but has low specificity for the diagnosis of tuberculomas and the differential diagnosis of ring-enhancing lesions includes several possibilities.

The major ones include high-grade glioma, metastasis and neurocysticercosis.

Metastases and high-grade gliomas are usually hyperintense on T2W in contrast to the T2W hypointense tuberculomas except in the first non-caseating stage. In this stage, 1H proton spectroscopy is also helpful because it shows a choline peak at 3.2 ppm in metastases, while tuberculoma shows a lipid peak. In addition, the extent of perilesional edema is disproportionately high in metastases as compared to tuberculomas.<sup>[9]</sup>

Neurocysticercosis lesions are generally multiple, placed in the sulcal subarachnoid spaces and usually size <2 cm; they appear as T2 hyperintense cysts lacking of rim enhancement on T1WI postcontrast administration.<sup>[11]</sup>

## Conclusion

CNS tuberculoma is a rare expression of the extrapulmonary TB disease usually misdiagnosis. This lesion can develop in any region of the brain, also in unusual locations, such as the corpus callosum and can occur in immunocompetent patients with no history of systemic TB, leading to a wrong diagnosis.

The evolution of the neuroimaging tools such as MRI and spectroscopy aids the differential diagnosis with other more common conditions. Careful evaluation of the neuroradiological images with adequate clinicoradiological

correlation allows for accurate diagnosis and ensures the proper care.

## Declaration of patient consent

The authors certify that they have obtained all appropriate patient consent forms. In the form the patient(s) has/have given his/her/their consent for his/her/their images and other clinical information to be reported in the journal. The patients understand that their names and initials will not be published and due efforts will be made to conceal their identity, but anonymity cannot be guaranteed.

## Financial support and sponsorship

Nil.

## Conflicts of interest

There are no conflicts of interest.

## References

1. Thwaites G, Fisher M, Hemingway C, Scott G, Solomon T, Innes J. British Infection Society guidelines for the diagnosis and treatment of tuberculosis of the central nervous system in adults and children. *J Infect* 2009;59:167-87.
2. Brismar J, Hugosson C, Larsson SG, Lundstedt C, Nyman R. Imaging of tuberculosis. III. Tuberculosis as a mimicker of brain tumour. *Acta Radiol* 1996;37:496-505.
3. Fath-Ordoubadi F, Lane RJ, Richards PG. Histological surprise: Callosal tuberculoma presenting as malignant glioma. *J Neurol Neurosurg Psychiatry* 1997;63:98-9.
4. Montgomery LC. Hemiplegia due to tuberculosis of the corpus callosum. *Can Med Assoc J* 1933;29:375-8.
5. Psimaras D, Bonnet C, Heinzmann A, Cárdenas G, Hernández José Luis S, Tungaria A, *et al.* Solitary tuberculous brain lesions: 24 new cases and a review of the literature. *Rev Neurol (Paris)* 2014;170:454-63.
6. Nelson CA, Zunt JR. Tuberculosis of the central nervous system in immunocompromised patients: HIV infection and solid organ transplant recipients. *Clin Infect Dis Off Publ Infect Dis Soc Am* 2011;53:915-26.
7. Krishnan N, Robertson BD, Thwaites G. The mechanisms and consequences of the extra-pulmonary dissemination of *Mycobacterium tuberculosis*. *Tuberc Edinb Scotl* 2010;90:361-6.
8. Kumar D, Sheoran RK, Bansal SK, Arora OP. Revisiting the CNS tuberculosis with emphasis on giant tuberculomas and introducing the “outer rim excrescence sign”. *Neuroradiol J* 2011;24:357-66.
9. Gupta RK, Kumar S. Central nervous system tuberculosis. *Neuroimaging Clin* 2011;21:795-814.
10. Bargalló J, Berenguer J, García-Barrionuevo J, Ubeda B, Bargalló N, Cardenal C, *et al.* The “target sign”: Is it a specific sign of CNS tuberculoma? *Neuroradiology* 1996;38:547-50.
11. Khatri GD, Krishnan V, Antil N, Saigal G. Magnetic resonance imaging spectrum of intracranial tubercular lesions: One disease, many faces. *Pol J Radiol* 2018;83:e524-35.