

Case Report

Rare Consequence of Pituitary Apoplexy Surgery: Artery of Percheron Infarction

Abstract

Management of pituitary apoplexy is multimodal. The surgical intervention followed by endocrinological management is the standard of care. Various vascular complications have been described in the literature after pituitary adenoma surgery. Artery of Percheron (AOP) infarct is a rare finding. Few cases were reported in the English literature after the endoscopic approach for pituitary adenoma. We present a 55-year-old lady presented with sudden-onset headache followed by vision loss. She was evaluated with imaging and diagnosed pituitary adenoma with apoplexy. She underwent an endoscopic transnasal approach and decompression of the tumor. In the postoperative period, she developed bilateral ptosis with altered sensorium. Imaging showed infarction of bilateral paramedian thalamus and rostral midbrain, suggestive of AOP infarct. Gradually, the patient improved, and at 3 months of follow-up, she was conscious and obeying with partial improvement of ptosis.

Keywords: Artery of Percheron, endoscopic surgery, infarction, pituitary apoplexy

Introduction

Pituitary apoplexy is an acute emergency condition in neurosurgery. Urgent surgical decompression is mandatory for decompression. Various complications reported after pituitary apoplexy surgery such as vascular (infarcts or bleed, direct vascular injury), endocrinology (panhypopituitarism), and delayed surgery, resulting in nonimprovement of visual symptoms or oculomotor deficits.^[1] Various arterial territory can be involved either anterior circulation such as small perforator of the internal carotid artery or middle/anterior cerebral artery or posterior circulation such as the basilar top, posterior cerebral artery, or perforators.^[2] Few cases of artery of Percheron (AOP) infarction reported in the English literature after the endoscopic approach for pituitary adenoma.^[2-4] AOP infarct following endoscopic transphenoidal surgery for pituitary apoplexy is not reported in the literature.

Case Report

A 55-year-old lady presented a sudden-onset headache followed by

bilateral sudden visual loss for 2 days. No prior history of visual loss or headache was noted. On examination, she was drowsy, obeying, right eye perception of light (-), and left eye-hand movement close to face without motor or sensory deficits. Computed tomography (CT) scan shows a sellar-suprasellar lesion with hyperdensity within the lesion [Figure 1a]. Magnetic resonance imaging (MRI) shows sellar-suprasellar lesion size (3.5 × 3 × 2.8) Cm, the lesion heterogeneously hyperintense in both T1W and T2W [Figure 1b] with areas of blooming on SWI [Figure 1c]. However, no evidence of infarction was found. Postcontrast images showed a thin rim of peripheral contrast enhancement. Imaging was suggestive of pituitary apoplexy. She underwent an endoscopic transnasal approach and decompression of tumor. Tumor was soft, vascular, and subtotal decompression was performed. During surgery, there was no notable cerebrospinal fluid (CSF) leak. In the postoperative period, the patient was in altered sensorium with bilateral ptosis, and an immediate CT scan showed subtotal decompression with blood in the interpeduncular cistern [Figure 1d]. Postoperative MRI showed (T2W and

**Subhas Konar,
Sadashiva
Nishanth,
B. Indira Devi**

*Department of Neurosurgery,
National Institute of Mental
Health and Neurosciences,
Bengaluru, Karnataka, India*

Address for correspondence:

*Dr. Subhas Konar,
Department of Neurosurgery,
National Institute of Mental
Health and Neurosciences,
Bengaluru, Karnataka, India.
E-mail: drsubhaskonar@gmail.
com*

Access this article online

Website: www.asianjns.org

DOI: 10.4103/ajns.AJNS_491_20

Quick Response Code:



How to cite this article: Konar S, Nishanth S, Devi Bl. Rare consequence of pituitary apoplexy surgery: Artery of percheron infarction. Asian J Neurosurg 2021;16:595-7.

Submitted: 26-Nov-2020 **Revised:** 02-May-2021
Accepted: 30-May-2021 **Published:** 14-Sep-2021

This is an open access journal, and articles are distributed under the terms of the Creative Commons Attribution-NonCommercial-ShareAlike 4.0 License, which allows others to remix, tweak, and build upon the work non-commercially, as long as appropriate credit is given and the new creations are licensed under the identical terms.

For reprints contact: WKHLRPMedknow_reprints@wolterskluwer.com

fluid-attenuated inversion recovery) [Figure 1e and f] hyperintense signal changes involving bilateral medial thalamus and rostral midbrain. Diffusion imaging showed bilateral paramedian thalamic infarcts with rostral midbrain infarct, suggestive of AOP infarct [Figure 2a-c]. The patient gradually improved in sensorium and was discharged after 10 days. At 3 months of follow-up, the patient was obeying with partial ptosis in both eyes.

Discussion

AOP is a rare variant of perforator arising from the posterior cerebral artery (P1 segment).^[5] It is an unpaired perforator arising from either side of the P1 segment, on average 8 mm lateral to basilar artery bifurcation, and supplying both paramedian thalamus and rostral midbrain. The mean diameter was 2.1 mm, and it traverses on an average of 1.5 cm before entering the brain.^[6] Four patterns

of infarct are commonly seen along with the midbrain “V” sign. The infarct patterns are bilateral paramedian thalamus involvement with or without rostral midbrain involvement and bilateral paramedian and anterior thalamus with or without midbrain involvement.^[3,7] The occurrence of AOP infarct after pituitary surgery is rare. The infraction of the AOP seen in primary pituitary adenoma, re-exploration cases of pituitary adenoma, and postradiotherapy.^[2,3,5] The cause of infarction could be the mechanical injury of the AOP, which was attached to the cisternal surface of tumor capsule. The AOP usually is small in diameter. Therefore, it seems that the amount of bleeding from it is not so much and controlled by itself. This event could be met in the pituitary surgery with aggressive manipulation, especially by curettage. The other probable cause of infraction could be vasospasm due to subarachnoid hemorrhage (SAH) following surgery. The rare probability is hypotension

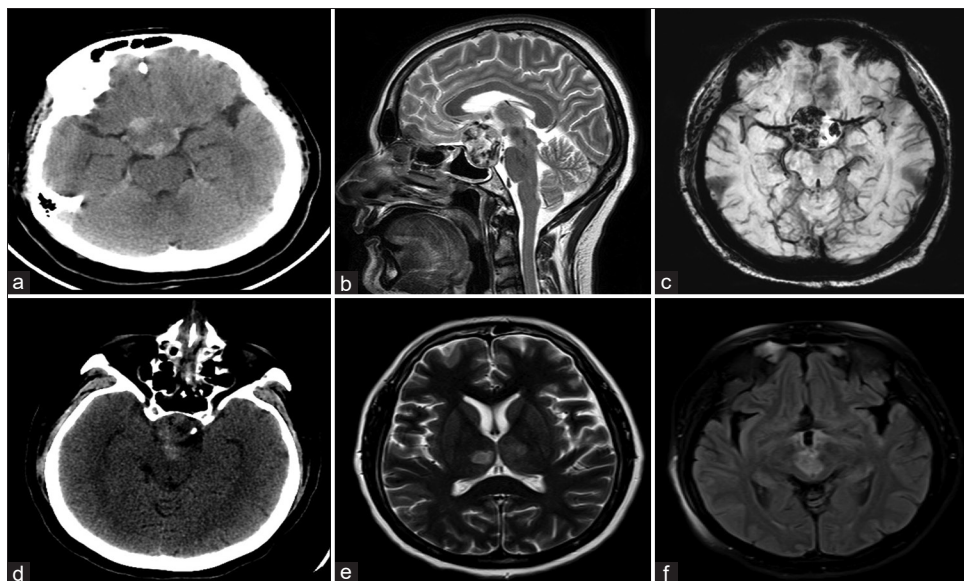


Figure 1: (a) Computed tomography (axial) showing mixed density suprasellar lesion. (b) Magnetic resonance imaging (T2W, sagittal) showing seller-suprasellar solitary lesion with multiple hyperintensity inside the tumor. (c) Magnetic resonance imaging (SWI, axial) showing areas of blooming inside the tumor suggestive of bleed. (d) Postoperative CT (axial) showing blood in interpeduncular cistern. (e) Postoperative magnetic resonance imaging (axial) showing hyperintensity in bilateral paramedian thalamus. (f) Postoperative magnetic resonance imaging (fluid-attenuated inversion recovery) showing rostral midbrain signal changes. CT: Computed tomography, MRI: Magnetic resonance imaging

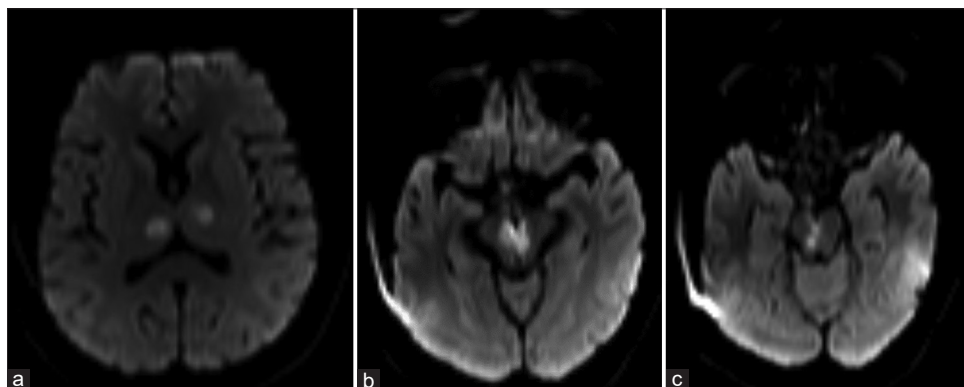


Figure 2: (a-c) Magnetic resonance imaging (diffusion-weighted imaging) showing diffuse restriction involving bilateral paramedian thalamus and rostral midbrain suggestive of artery of Percheron infarct. MRI: Magnetic resonance imaging

during the surgery, and it can happen due to hypopituitarism following apoplexy or hypercortisolism.^[2] Meningitis in the postoperative period can also cause infarction of major vessels as well as small perforators.^[8]

Typical clinical features of the AOP infarct are unconsciousness after surgery with or without cranial nerve involvement. MRI with diffusion-weighted imaging is the investigation of choice and shows bilateral thalamus with paramedian midbrain infarct. In our case, the probable cause was a breach of the posterior capsule, resulting in SAH. The SAH leads to the vasospasm of the AOP. The underlying pituitary apoplexy caused the tumor to firmer, as presented late. The acute blood may be converted into clot followed by early fibrosis. Aryan *et al.*^[9] reported a case AOP infarct following endoscopic transsphenoidal surgery for a re-exploration case of pituitary adenoma. Intraoperatively, CSF leak was noted. Postoperative CT scan showed diffuse SAH and MR showed AOP infarct though managed with nimodipine infusion. Patients recovered well with residual hemiparesis and ptosis. On the contrary, our patient presented with apoplexy and underwent endoscopic transnasal surgery for a primary tumor. We did not notice the CSF leak during surgery. In the postoperative period, nimodipine was added and the patient slowly improved in sensorium. The pattern of an infarction involving bilateral medial thalamus and rostral midbrain was suggestive of the AOP infarction. The pattern of infarction is typical for AOP infarction. Hence, if the postoperative images show the specific infarction pattern, medical treatment should be initiated as early as possible. Preoperative diagnosis of AOP is challenging as it is a small vessel, especially if a large adenoma distorting the surrounding anatomy. However, MRI angiogram may help detect suspected cases of the presence of AOP.

Management of this rare type of infarct is conservation.^[3] Initial ventilator support if required followed by neurorehabilitation is the policy. If the patient develops panhypopituitarism, then endocrinological support is mandatory. The role of nimodipine to prevent vasospasm is not proven. The prognosis depends on the pattern of infarct and the quality of supportive care.

Inform consent

Informed consent was taken from patient.

Declaration of patient consent

The authors certify that they have obtained all appropriate patient consent forms. In the form, the patient has given her consent for her images and other clinical information to be reported in the journal. The patient understand that name and initial will not be published and due efforts will be made to conceal identity, but anonymity cannot be guaranteed.

Financial support and sponsorship

Nil.

Conflicts of interest

There are no conflicts of interest.

References

1. Albani A, Ferraù F, Angileri FF, Esposito F, Granata F, Ferreri F, *et al.* Multidisciplinary management of pituitary apoplexy. *Int J Endocrinol* 2016;2016:7951536.
2. Sankar T, Souster J, Steinke DE. Bilateral thalamic infarction following transsphenoidal surgery. *Can J Neurol Sci* 2008;35:522-5.
3. Arauz A, Patiño-Rodríguez HM, Vargas-González JC, Arguelles-Morales N, Silos H, Ruiz-Franco A, *et al.* Clinical spectrum of artery of Percheron infarct: Clinical-radiological correlations. *J Stroke Cerebrovasc Dis* 2014;23:1083-8.
4. Pereira MR, Hernández FM, Cortés CA. Artery of percheron and endoscopic endonasal surgery: Case report and review of the literature. *Asian J Neurosurg* 2020;15:777-80.
5. Shukla D. Neuroendoscopic view of artery of percheron. *Br J Neurosurg* 2017;31:630.
6. Griessenauer CJ, Loukas M, Tubbs RS, Cohen-Gadol AA. The artery of Percheron: An anatomic study with potential neurosurgical and neuroendovascular importance. *Br J Neurosurg* 2014;28:81-5.
7. Lazzaro NA, Wright B, Castillo M, Fischbein NJ, Glastonbury CM, Hildenbrand PG, *et al.* Artery of percheron infarction: Imaging patterns and clinical spectrum. *AJNR Am J Neuroradiol* 2010;31:1283-9.
8. Rao KV, Gangadharan JL, Vazhayil V, Somanna S. Arterial infarct following surgery for pituitary adenoma. *J Neurosci Rural Pract* 2014;5:434-6.
9. Aryan S, Thakar S, Hegde AS. Artery of Percheron infarction after endoscopic pituitary surgery. *Acta Neurochir (Wien)* 2016;158:1973-5.