

Retrospective Study and Outcome Predictor after Microsurgical Resection of Cerebral Arteriovenous Malformations in Nepal

Abstract

Objective: The purpose of this study is to assess demographic, clinical, and morphological characteristics of patients with brain arteriovenous malformations (bAVMs). The relation of outcome using modified Rankin Scale (mRS) at time of discharge, early and last follow ups with respect to various factors. **Materials and Methods:** Demographic data, arteriovenous malformation characteristics, and treatment outcomes were evaluated in 43 bAVMs treated with microsurgery between 2009 and 2019. For this series, 43 patients were retrospectively reviewed. A subgroup analysis for Spetzler-Martin grades (SMG) I/II, III, IV/V and III–V were performed. The mRS was used to assess functional outcomes. **Results:** Overall, mean age at diagnosis was 33 years (standard deviation = 19). Transient deficit, mRS deterioration and impaired functional outcome occurred less frequently in SMG I–II patients compared with Grade III–V patients combined (29% vs. 32% respectively, $P = 0.00$). All patients with SMG Grade I, Supplemented SMG Grade 2, 3, 4 and 6 had a mRS score of 2 or less at the last follow-up. Age was the only significant predictor of overall outcome after bAVM surgery on Chi-square test ($P = 0.046$), i.e: all patients <20 years had mRS score of 2 or less on last follow-up. Unfavorable outcome (mRS score of 3 or more than 3) level increased with higher grades in SMG on long term follow-up. **Conclusion:** The results of our case series of bAVM with SMG Grade I and Supplemented Grade 2, 3, 4 and even higher grade i.e., 6 can have excellent overall outcome after microsurgical resection. Association of factors which increases the grading system of bAVM like eloquence, deep venous drainage and increasing sizes did not correlate with the predicted unfavorable outcomes, whereas age of patients was a predictor of overall outcome. Although the small sample size of this study is a limitation, age of patient plays important role on the overall outcome.

Keywords: Arteriovenous malformations, brain arteriovenous malformation, functional outcome, microsurgery, Spetzler-Martin grades

Introduction

Brain arteriovenous malformations (bAVMs) are rare cerebrovascular lesions characterised by an abnormal mass of dilated arteries and veins and direct arteriovenous shunting.^[1] They can be incidental or present with headaches, seizures, or most commonly intracranial hemorrhage associated with significant mortality and morbidity.^[2] Because of advanced medical imaging in developed countries, the majority of patient harboring arteriovenous malformation (AVM) lesions are typically asymptomatic when they are detected or investigated unlike in our part of the world where majority of patient come with haemorrhage.^[3] When the rupture occurs, it is documented as a significant cause of neurological deficit for the reason that it is the origin of intracranial hemorrhage

or seizure. AVM generally presents about 1/100,000 of all population.^[4] Given the risk for hemorrhagic stroke, resection remains the gold standard for treating brain AVMs. Compared to the other modalities available, surgery averages 95.9% complete obliteration versus 22.1% for endovascular treatment and 67.4% for radiosurgery.^[5] This present study represents the authors' experiences with 43 Nepalese cerebral AVM patients with microsurgical treatment to retrospectively evaluate outcome score by modified Rankin Score (mRS) during 2009–2019.

Materials and Methods

This was a retrospective study conducted in our institutes (Bir, Dhirgayu, Mediciti Hospitals) in Kathmandu, Nepal from 2009 to 2019 including 43 patients who

This is an open access journal, and articles are distributed under the terms of the Creative Commons Attribution-NonCommercial-ShareAlike 4.0 License, which allows others to remix, tweak, and build upon the work non-commercially, as long as appropriate credit is given and the new creations are licensed under the identical terms.

For reprints contact: WKHLRPMedknow_reprints@wolterskluwer.com

How to cite this article: Karki P, Sharma GR, Joshi S, Paudel P, Shah DB. Retrospective study and outcome predictor after microsurgical resection of cerebral arteriovenous malformations in Nepal. Asian J Neurosurg 2021;16:355-62.

Submitted: 26-Nov-2020 Revised: 01-Feb-2021
Accepted: 03-Feb-2021 Published: 28-May-2021

**Prasanna Karki,
Gopal Raman
Sharma,
Sumit Joshi,
Prakash Paudel,
Damber Bikram
Shah**

Department of Neurosciences,
Division of Neurosurgery, Nepal
Mediciti Hospital, Lalitpur,
Kathmandu, Nepal

Address for correspondence:

Dr. Prasanna Karki,
Department of Neurosciences,
Division of Neurosurgery, Nepal
Mediciti Hospital, Sainbu,
Lalitpur, Kathmandu, Nepal.
E-mail: prasannakarki7@gmail.com

Access this article online

Website: www.asianjns.org

DOI: 10.4103/ajns.AJNS_509_20

Quick Response Code:



underwent microsurgical resection of brain AVM. This study was approved by Nepal Health Research Council following an authorization from the Institutional review committee (IRC); IRC-RP-2011/009 and was conducted in accordance with the institutional ethics guidelines. The Nepal Medciti Hospital brain AVM study group database is a prospectively collected database containing demographics, clinical and radiological information. We also had hard copies of patient profiles and follow-ups in brain AVM Performa collection. To identify patients with brain AVMs treated by microsurgical resection at our institute between 2009 and 2019, the profoma was used. All patients with intracerebral AVM and treated with microsurgery were included in the study. Brain AVM was categorized by Spetzler-Martin Grading system (SMG) and supplemented SMG. Diagnosis and surgical planning in all patients were based on brain magnetic resonance imaging (MRI), computed tomography (CT) angiography and for large and complex AVM, digital subtraction angiogram (DSA). Intraoperative ICG, Doppler and neurophysiological monitoring were routinely used in all cases. Clinical follow-up was performed at 1 week, 1, 3–6 months posthospital discharge and at annual intervals thereafter. Postoperative cerebral angiogram after 1 week prior to discharge was routinely performed and follow-up CT angiogram whenever required or necessary. Exclusion criteria included evidence of operated for other vascular malformations like cavernoma, venous angioma, body AVM or any treatment without microsurgical resection of AVM. All AVM cases were diagnosed based on MRI, CT angiogram and DSA in complex large cases. The relation of different variables like age, major complications and mRS was analyzed with Spetzler Martine Grade (SMG) grouped into Grade I–II, Grade III, Grade IV–V and Grade III–V. The association of the baseline characteristics of the patient was studied and was analyzed with dichotomized modified Ranklin Scale (mRS) favorable mRS (0–2) and nonfavorable mRS (>2) to find out the outcome at time of discharge, at 6 months follow-up and at last follow-up (minimum being 1 year) with mean follow-up of 3.35 years.

Statistical analysis

IBM SPSS Statistics 20 was used for statistical analysis. Independent-samples *t*-test was used to test significance of association. A subgroup analysis was performed by grade (i.e., Grades I/II, III, IV/V and III–V). Grade I/II patients were compared with Grade III to V patients. Statistical significance was defined as a value of $P < 0.05$. For age, follow-up, mRS and complications (persistent and transient), a two-sided *t*-test was used to compare groups belonging to different SM grades. We used Chi-square to assess differences between groups for categorical characteristics in univariate analyses of factors affecting postoperative mRS.

Results

From 2009 to 2019, 43 bAVMs patients were treated with microsurgical resection. Baseline demographics, clinical presentation, and AVM characteristics are presented in Table 1. The mean age at presentation was 33 years, there were 13 females (30%) and 30 males (70%). The most common presentations were hemorrhage (77%), symptomatic seizure (14%), hemorrhage with seizure (5%), asymptomatic/incidental radiological findings (2%) and dizziness (2%). The most AVM were in eloquent location i.e., 54%, 35% of AVM had deep venous drainage, associated aneurysm was in 21%, deep perforators in 35% and calcification in 16%. Most of the AVM were 4–6 cm (63%), 26% were more than 6 cm and 12% were <3 cm. 65% of brain AVM underwent elective surgery whereas 35% had emergent surgical resection. SM grading was distributed accordingly: 1 Grade 1 (2%), 20 Grade 2 (47%), 13 Grade 3 (30%), 7 Grade 4 (16%) and 2 Grade 5 bAVMs (5%). Supplemented SM grading was also distributed as: 1 Grade 2 (2%), 5 Grade 3 (12%), 11 Grade 4 (26%), 14 Grade 5 (33%), 4 Grade 6 (9%), 6 Grade 7 (14%) and 2 Grade 8 (5%). On admission 28% of patient has mRS of 2 and another 28% had 4. On discharge, 42% had mRS of 0, after 6 months of follow-up 65% had mRS of 0 and on last follow up (minimum follow-up period is 1 year) 79% had mRS of 0. The minimum follow-up period was 1 year. Overall outcome by SM grades after microsurgical resection are listed in Table 2. In our series, there was one mortality.

The patient's major complications were categorized into persistent, transient deficit and death. Persistent neurological deficit after surgery were found in 16% of overall patients, 19% of Grade I–II, 15% of Grade III and 11% of Grade IV/V. Transient deficit occurred in 30% of overall patients (29% in Grade I–II, 38% in Grade III and 22% in Grade IV–V). Compared with grade III to V patient, fewer Grade I–II patients had transient neurological deficit (29% vs. 32%: $P = 0.00$). Compared with SM grade III–V patients, fewer SM Grade I–II patients had major complications, i.e., neurological deficit (48% vs. 50%; $P = 0.00$). When mRS of 0–2 is used to define good outcome whereas mRS score more than 2 as impaired outcome, 12% of patients (10% Grade II and II, 7% Grade III, 22% Grade IV and V) had impaired outcome. Therefore, in comparison to Grade III–V, i.e., 14% with impaired outcome, Grade I–II had only 10% of impaired outcome.

Detailed distribution of the patient characteristics and the AVM related factors were connected to the outcomes in Table 3 (mRS of 0–2 is used to define good outcome whereas mRS score more than 2 as impaired outcome) and their *P* value in Table 4. Chi square test in Table 4 identified age ($P < 0.046$) as a significant predictor for the good overall outcome for younger population.

Table 1: Baseline characteristics of brain arteriovenous malformation patients

Patient characteristics	n (%)
<i>n</i>	43
Age (years), mean (SD)	33 (19)
Female, <i>n</i> (%)	13 (30)
Female age (years), mean (SD)	28 (20)
Male, <i>n</i> (%)	30 (70)
Male age (years), mean (SD)	34 (19)
Clinical presentation, <i>n</i> (%)	
Asymptomatic	1 (2)
Dizziness	1 (2)
Hemorrhage	33 (77)
Hemorrhage+seizure	2 (5)
Seizure	6 (14)
Eloquent location, <i>n</i> (%)	23 (54)
Deep venous drainage, <i>n</i> (%)	15 (35)
Aneurysm, <i>n</i> (%)	9 (21)
Perforators, <i>n</i> (%)	15 (35)
AVM size (cm), <i>n</i> (%)	
<3	5 (12)
3-6	27 (63)
>6	11 (26)
Calcified, <i>n</i> (%)	7 (16)
Timing, <i>n</i> (%)	
Elective	28 (65)
Emergent	15 (35)
SMG, <i>n</i> (%)	
I	1 (2)
II	20 (47)
III	13 (30)
IV	7 (16)
V	2 (5)
Supplemented SMG, <i>n</i> (%)	
2	1 (2)
3	5 (12)
4	11 (26)
5	14 (33)
6	4 (9)
7	6 (14)
8	2 (5)
GCS, <i>n</i> (%)	
7	2 (5)
8	1 (2)
10	3 (7)
12	6 (14)
13	6 (14)
14	7 (16)
15	18 (42)
On admission mRS, <i>n</i> (%)	
0	1 (2)
1	8 (19)
2	12 (28)
3	3 (7)
4	12 (28)

Contd..

Table 1: Contd..

Patient characteristics	n (%)
5	7 (16)
On discharge mRS, <i>n</i> (%)	
0	18 (42)
1	1 (2)
2	4 (9)
3	11 (26)
4	4 (9)
5	5 (12)
6 months mRS, <i>n</i> (%)	
0	28 (65)
1	2 (5)
2	5 (12)
3	5 (12)
4	2 (5)
6	1 (2)
Last follow-up mRS, <i>n</i> (%)	
0	34 (79)
1	1 (2)
2	3 (7)
3	4 (9)
6	1 (2)

GCS-Glasgow Coma Scale; mRS-Modified Rankin Scale; SD-Standard deviation; AVM-Arteriovenous malformation; SMG-Spetzler-Martin grade

AVM size of <3 cm had 100% favorable outcomes on discharge and consecutive follow-ups, size of 3–6 cm had 85.2% favorable outcome on last follow-up when compared to 77.8% on discharge and size >6 cm had 90.9% favorable outcome on last follow-up when compared to 81.8% on discharge. Presence of perforators and deep venous drainage was borderline significant ($P = 0.069$) for overall outcome. Interestingly, presence of perforators and deep venous drainage did not show worse outcome in our case series. 88.6% of patient with hemorrhagic presentation had favorable outcome on last follow-up compared to 54.3% at discharge. Unfavorable outcome level increased with higher grades in both SM grade and supplemented SM grade even at long term outcome but interestingly, even with Supplemented SM grade 6 patients had 100% favorable outcome, higher SM grade i. e. IV had 85.7% favorable outcome at last follow-up and overall highest AVM grade did not have favorable outcome <50%. Some of the example cases are illustrated in Figures 1-3 of left frontal AVM, infratentorial AVM and Left temporal AVM respectively. All three illustrated cases had mRS score of 0 on 6 months follow-up.

Discussion

Microsurgical resection has been reported to have a low risk of complications for in SMG I and II brain AVMs (e.g., small malformations in noneloquent areas) and result is immediate cure, however, no treatment is required for Grade IV–V and

Table 2: Major complications and clinical outcomes

	Overall	Grades I and II	Grade III	Grade IV and V	Grades III-V	Significance
<i>n</i> (%)	43	21 (49)	13 (30)	9 (21)	22 (51)	
Age (year), mean (SD)	33 (19)	37 (20)	27 (17)	30 (18)	28 (17)	0.00
Follow-up mRS						
Follow-up, mean (SD)	0.6 (1)	0.5 (1)	0.4 (1)	1 (2.1)	0.6 (1.5)	0.00
Last mRS score ≥ 2 , <i>n</i> (%)	8 (19)	4 (19)	2 (15)	2 (22)	4 (18)	0.52
Last mRS score ≥ 3 , <i>n</i> (%)	5 (12)	2 (10)	1 (7)	2 (22)	3 (14)	0.75
Major complication, <i>n</i> (%)	21 (49)	10 (48)	7 (54)	4 (44)	11 (50)	0.00
Persistent deficit	7 (16)	4 (19)	2 (15)	1 (11)	3 (14)	0.14
Transient deficit	13 (30)	6 (29)	5 (38)	2 (22)	7 (32)	0.00
Death	1 (2)	0	0	1 (11)	1 (5)	

SD-Standard deviation; mRS-Modified Rankin Scale

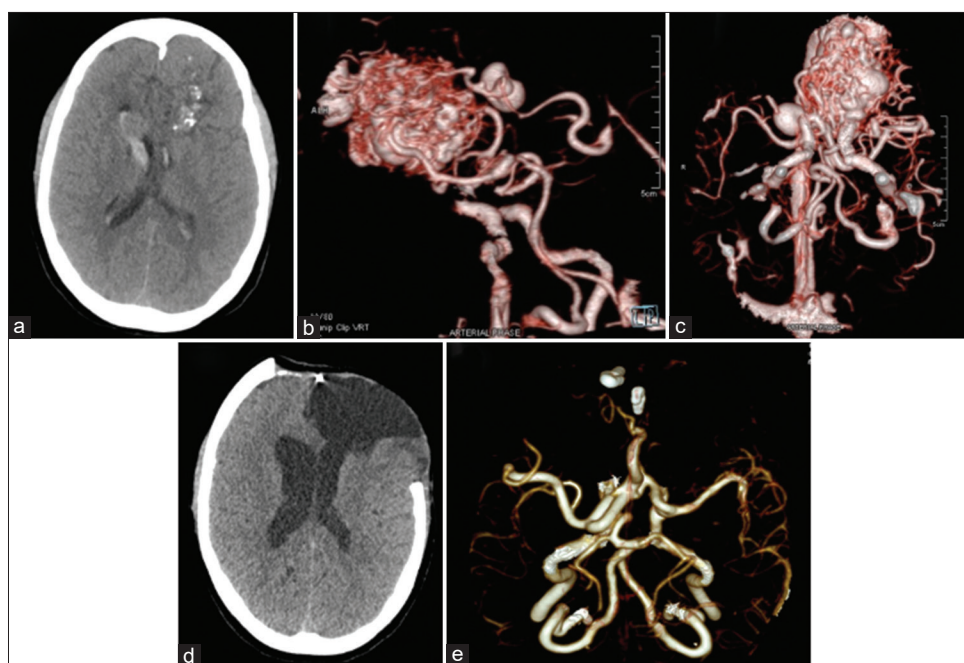


Figure 1: Left frontal arteriovenous malformation of SMG V and supplemented SMG 7. (a) Plain computed tomography scan showing evidence of calcified lesion on left frontal lobe with hyper-density in ventricle showing intraventricular hemorrhage. (b) Three-dimensional reconstruction of computed tomography angiogram sagittal view with intravenous contrast showing large left frontal arteriovenous malformation with feeders from left Middle cerebral artery, anterior cerebral artery, internal carotid artery and draining into vein of Galen to straight sinus. (c) Three-dimensional reconstruction of computed tomography angiogram axial view with intravenous contrast showing larger left frontal arteriovenous malformation. (d) Postoperative plain computed tomography scan showing complete excision of left frontal arteriovenous malformation with cranial defect over left fronto-temporal and part of right frontal bone. (e) Postoperative three-dimensional reconstruction of computed tomography angiogram axial view with intravenous contrast showing complete excision of arteriovenous malformation with normal cerebral vessels and two aneurysm clips in anterior circulation

multimodal treatment is often recommended i.e., embolization, radiosurgery and microsurgery or combination of modalities. Stereotactic radiosurgery, focused irradiation, can be effective for malformations that are smaller than 3.5 cm, but complete obliteration requires approximately 1–3 years after treatment and cure is not always obtained. Delayed complications such as hemorrhage in the latency period and radiation edema or necrosis can occur as late complications. Embolization as an adjuvant therapy can be done for large AVM (SM Grade IV–V) or to obliterate small AVMs.^[6,7]

Ponce and Spetzler introduced 3-tier system by modifying the Spetzler-Martin grading scale in 2011, were SM Grade I and II became Class A was recommended for microsurgical

resection, Grade III became Class B was recommended for multimodal approach and Grade IV and V became Class C was recommended for multimodal approach or observation.^[8] Furthermore, ARUBA trial (A randomized trial of unruptured bAVMs) suggested superiority of conservative management over intervention for the prevention of the primary outcome, death resulting from any cause, or symptomatic stroke at follow-up.^[9,10] Though, Ponce and Spetzler show surgical resection only for Class A and ARUBA trial show medical treatment superior for all types of brain AVMs, the outcomes of patients in our study where all SM grades were treated microsurgically goes against the reported literatures.

Table 3: Factors and neurological outcomes associated with Spetzler-Martin grade and Supplemented Spetzler-Martin grade

	Outcome (on discharge)		Outcome (6 months)		Outcome (last follow-up)		Total (n)
	Favourable, n (%)	Unfavourable, n (%)	Favourable, n (%)	Unfavourable, n (%)	Favourable, n (%)	Unfavourable, n (%)	
Sex							
Female	7 (53.8)	6 (46.2)	10 (76.9)	3 (23.1)	11 (84.6)	2 (15.4)	13
Male	16 (53.3)	14 (46.7)	25 (83.3)	5 (16.7)	27 (90.0)	3 (10.0)	30
Age group							
<20	11 (73.3)	4 (26.7)	13 (86.7)	2 (13.3)	15 (100.0)	0	15
20-40	8 (57.1)	6 (42.9)	13 (92.9)	1 (7.1)	13 (92.9)	1 (7.1)	14
>40	4 (28.6)	10 (71.4)	9 (64.3)	5 (35.7)	10 (71.4)	4 (28.6)	14
Caste/ethnicity							
Aryan	12 (48.0)	13 (52.0)	19 (76.0)	6 (24.0)	21 (84.0)	4 (16.0)	25
Mongoloid	11 (61.1)	7 (38.9)	16 (88.9)	2 (11.1)	17 (94.4)	1 (5.6)	18
AVM size (cm)							
<3	5 (100)	0	5 (100.0)	0	5 (100.0)	0	5
3-6	21 (77.8)	6 (22.2)	21 (77.8)	6 (22.2)	23 (85.2)	4 (14.8)	27
>6	9 (81.8)	2 (18.2)	9 (81.8)	2 (18.2)	10 (90.9)	1 (9.1)	11
Eloquence location							
No	12 (60.0)	8 (40.0)	18 (90.0)	2 (10.0)	19 (95.0)	1 (5.0)	20
Yes	11 (47.8)	12 (52.2)	17 (73.9)	6 (26.1)	19 (82.6)	4 (17.4)	23
Perforators							
No	15 (53.6)	13 (46.4)	25 (89.3)	3 (10.7)	26 (92.9)	2 (7.1)	28
Yes	8 (53.3)	7 (46.7)	10 (66.7)	5 (33.3)	12 (80.0)	3 (20.0)	15
Deep veins							
No	15 (53.6)	13 (46.4)	25 (89.3)	3 (10.7)	26 (92.9)	2 (7.1)	28
Yes	8 (53.3)	7 (46.7)	10 (66.7)	5 (33.3)	12 (80.0)	3 (20.0)	15
Haemorrhage							
Yes	19 (54.3)	16 (45.7)	28 (80.0)	7 (20.0)	31 (88.6)	4 (11.4)	35
No	4 (50.0)	4 (50.0)	7 (87.5)	1 (12.5)	7 (87.5)	1 (12.5)	8
Aneurysm							
No	19 (55.9)	15 (44.1)	28 (82.4)	6 (17.6)	31 (91.2)	3 (8.8)	34
Yes	4 (44.4)	5 (55.6)	7 (77.8)	2 (22.2)	7 (77.8)	2 (22.2)	9
SMG							
I	1 (100.0)	0	1 (100.0)	0	1 (100.0)	0	1
II	11 (55.0)	9 (45.0)	16 (80.0)	4 (20.0)	18 (90.0)	2 (10.0)	20
III	7 (53.8)	6 (46.2)	11 (84.6)	2 (15.4)	12 (92.3)	1 (7.7)	13
IV	4 (57.1)	3 (42.9)	6 (85.7)	1 (14.3)	6 (85.7)	1 (14.3)	7
V	0	2 (100.0)	1 (50.0)	1 (50.0)	1 (50.0)	1 (50.0)	2
Supplemented SMG							
2	1 (100.0)	0	1 (100.0)	0	1 (100.0)	0	1
3	4 (80.0)	1 (20.0)	4 (80.0)	1 (20.0)	5 (100.0)	0	5
4	6 (54.5)	5 (45.5)	10 (90.9)	1 (9.1)	11 (100.0)	0	11
5	8 (57.1)	6 (42.9)	11 (78.6)	3 (21.4)	12 (85.7)	2 (14.3)	14
6	3 (75.0)	1 (25.0)	4 (100.0)	0	4 (100.0)	0	4
7	1 (16.7)	5 (83.3)	4 (66.7)	2 (33.3)	4 (66.7)	2 (33.3)	6
8	0	2 (100.0)	1 (50.0)	1 (50.0)	1 (50.0)	1 (50.0)	2

AVM-Arteriovenous malformation; SMG-Spetzler-Martin grade

In our case series, all the patients were treated microsurgically irrespective of SM grading system or supplemented SM grading system, interestingly, even with higher grade, we have favorable outcomes on follow-ups. Furthermore, the supplemented SM grade has 9 different grades (2–10) where, Grade 6 is considered the cutoff

point for acceptable surgical risk.^[11] In our study, even with supplemented SM Grade 6 or higher have favorable outcome. As reported, the proportion of patients in whom complete obliteration was obtained after treatment was high after microsurgery when compared to other modality of treatment. The hemorrhage rate over time in other

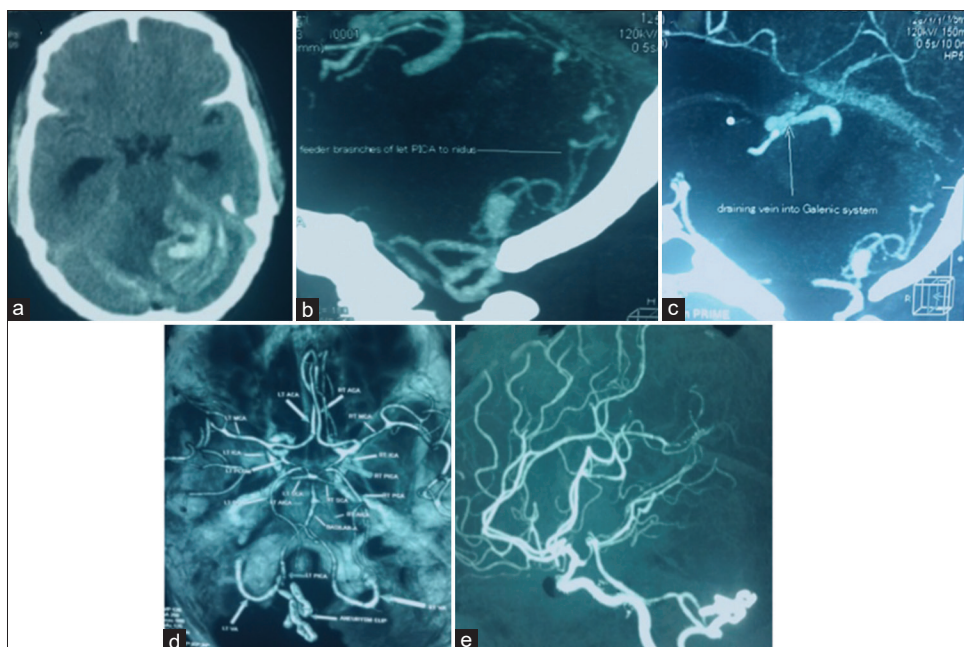


Figure 2: Infratentorial arteriovenous malformation of SMG II and supplemented SMG 6. (a) Plain computed tomography scan showing evidence of cerebellar hematoma. (b) Computed tomography angiogram sagittal view with intravenous contrast showing arteriovenous malformation with feeder from left posterior inferior cerebellar artery. (c) Computed tomography angiogram sagittal view with intravenous contrast showing arteriovenous malformation draining into vein of Galen. (d) Postoperative computed tomography angiogram axial view with intravenous contrast showing complete excision of arteriovenous malformation with normal cerebral vessels and two aneurysm clips in posterior circulation. (e) Postoperative computed tomography angiogram sagittal view with intravenous contrast showing complete excision of arteriovenous malformation with normal cerebral vessels and two aneurysm clips in posterior circulation

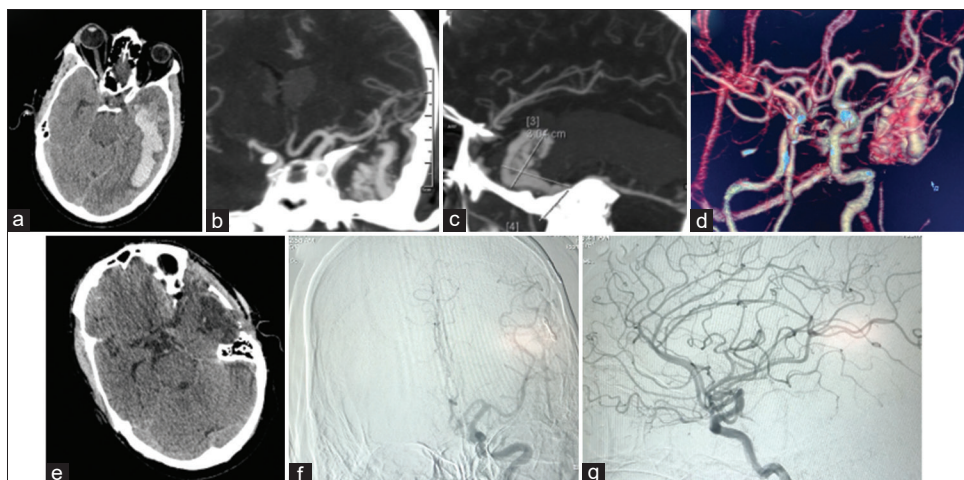


Figure 3: Left temporal arteriovenous malformation of SMG IV and supplemented SMG 7. (a) Plain computed tomography scan axial showing evidence of left temporal hematoma. (b) Computed tomography angiogram coronal view with intravenous contrast showing arteriovenous malformation with feeder from left middle cerebral artery. (c) Computed tomography angiogram sagittal view with intravenous contrast showing arteriovenous malformation with feeder from left middle cerebral artery. (d) Three-dimensional computed tomography angiogram coronal view with intravenous contrast showing arteriovenous malformation with feeder from left middle cerebral artery. (e) Postoperative plain computed tomography scan showing complete excision of left temporal arteriovenous malformation. (f) Postoperative digital subtraction angiography coronal showing normal left cerebral vasculature and no evidence of abnormal vessels. (g) Postoperative digital subtraction angiography sagittal showing normal left cerebral vasculature and no evidence of abnormal vessels

treatment modalities except for microsurgery is due to low obliteration rate.^[12]

However, our analyses regarding brain AVM size and obliteration yielded contradictory findings, possibly due to the small number of cases that reported size.

Some authors reported about trail of conservative management at initial consultation. However, after

experiencing the cumulative neurologic deficits associated with repeated hemorrhages, the balance of risk fell in favor of surgery for many of the patients although the risk of surgery in patients with Spetzler-Martin grade 3–5 AVMs in eloquent cortex may be as high as 41%.^[13] Therefore, microsurgery could be the most reliable modality for complete obliteration of AVM and prevention of long-term complication related to conservative management done in

Table 4: Chi-square test of variables associated with overall outcomes

	Associated with discharge time, <i>P</i> ^a	Associated with 6 months after discharge, <i>P</i> ^a	Associated with last follow-up, <i>P</i> ^a
Sex	0.975	0.620	0.613
Age group	0.051	0.123	0.046
Caste/ethnicity	0.395	0.284	0.292
AVM size (cm)	0.252	0.502	0.608
Eloquent location	0.425	0.176	0.206
Perforators	0.988	0.069	0.210
Deep veins	0.988	0.069	0.210
Hemorrhage	0.826	0.623	0.932
Aneurysm	0.541	0.754	0.265
SMG	0.521	0.785	0.510
Supplemented SMG	0.193	0.671	0.205

^a*P* values are derived from a Chi-square test. SMG-Spetzler-Martin grade; AVM-Arteriovenous malformation

high grade brain AVM. On the other hand, considering other literature, case fatality after microsurgery may be higher than other treatment modalities due to selection bias because in patients who present with hemorrhage, surgery is more often performed in the acute phase.^[14] All the cases in our series were treated microsurgically irrespective of grading system due to its feasibility, cost-effectiveness, lack of national insurance policy in our country, lack of availability of interventionist and absence of radiosurgical facility. Furthermore, we intervened all bAVMs even with SM Grade IV–V as most cases presented with hemorrhage and low Glasgow Coma Scale, therefore, we had no choice then to do craniotomy and removal of hematoma along with AVM resection at same setting.

In this study, the rate by grouping according to SM grading were as follows: 49% of Grade I–II patients, 30% of Grade III patients, 21% of Grade IV–V patients and 51% of Grade III–V patients. In our study, using outcome measure, the Rankin scale and the SM grading system, Grade IV–V had lower persistent deficit than grade I–II which could not confirm the low complication rates in Grade 1–3 proposed in the work on which the progression in the rate of complication from Grade 1 through 5 that other reports have shown.^[15] The functional outcome reported at last follow-up and compared with the SM grading system. The outcomes of patients, in particular Grade IV–V patients, highlights that microsurgical treatment alone may be justified in this subset of patients as well. The finding of Grade IV–V patients, regardless of grading system, have better clinical outcome which is a new finding. The overall small volume of complications in our studies maybe the cause of prediction failure by SM grading system about the relevant disabling complications. Furthermore, the result also highlights the need of prospective, multicentric data to better identify patients who may benefit most from microsurgical treatment alone.

In particular, AVM patients diagnosed at a higher age seem to bear a higher proportion of AVM hemorrhage and are

more likely to show additional risk factors (i.e., concurrent arterial aneurysms and small AVM size). Therefore, according to literature, older age was associated with higher case fatality than younger population.^[16,17] Whereas, young patients who score 1–3 in the supplementary SM grading system and as children are more likely to have hemorrhage as presentation which had null score in supplementary SM grade explained the better outcome. Authors have also postulated the theory of neural plasticity that may augment surgical tolerance and recovery in children leading to better outcome.^[18] Similar to previously reported literature, our series too showed favorable outcome post microsurgical resection of AVM in age group <20 years.

As reported, a morbidity of natural-course AVM hemorrhage lower than that from intracranial bleeding from other causes.^[19] Even though majority of our patients i.e., 77% had hemorrhage on presentation, the last follow-up outcome seems to be favorable in more than 88%. Surgical risk has been reported to be associated with increasing size, eloquent location, and presence of deep venous drainage.^[20] The presence of deep perforating arterial supply is also associated with an increased risk of surgical morbidity in high grade AVMs.^[21] The deep perforating artery supply is also more common in large, complex AVMs which by themselves are associated with higher risk of surgery. Presence of deep perforating arterial supply and deep venous drainage in our series did not have significance on outcome even though we have higher percentage of Grade III–V patients i.e., 51%. The possible explanation of this finding in our series is that, all the surgeries were performed by well trained and experienced surgeon (G.R.S).

Limitation of the study

Limitations of this study included that it was a retrospective design and sample size was small so results of comparative analysis of subgroups should be considered cautiously and may not be appropriate to generalize in clinical practice. Further clinical studies with large cohorts are needed to support our findings.

Conclusion

The results of our case series of bAVM with SMG Grade I and Supplemented Grade 2, 3, 4 and even higher grade i.e., 6 can have excellent overall outcome after microsurgical resection. Association of factors which increases the grading system of bAVM like eloquence, presence of perforating artery, deep venous drainage and increasing sizes did not correlate with the predicted unfavorable outcomes, whereas age of patients was a predictor of overall outcome. Although the small sample size of this study is a limitation, age of patient plays important role on the overall outcome. Overall, our data suggests good outcome postsurgery but there is a need of prospective, multicentric data to better identify patients who may benefit most from microsurgical treatment alone.

Part of this work as in abstract is being used in WFNS/ACNS Webinar.

Part of this work as in abstract will be used for presentation in AANS 2020, Vancouver.

Financial support and sponsorship

Nil.

Conflicts of interest

There are no conflicts of interest.

References

- Solomon RA, Connolly ES. Arteriovenous malformations of the brain. *N Engl J Med* 2017;376:1859-66.
- Brown RD Jr., Wiebers DO, Torner JC, O'Fallon WM. Frequency of intracranial hemorrhage as a presenting symptom and subtype analysis: A population-based study of intracranial vascular malformations in Olmsted Country, Minnesota. *J Neurosurg* 1996;85:29-32.
- Friedlander RM. Clinical practice. Arteriovenous malformations of the brain. *N Engl J Med* 2007;356:2704-12.
- Al-Shahi R, Warlow C. A systematic review of the frequency and prognosis of arteriovenous malformations of the brain in adults. *Brain* 2001;124:1900-26.
- Burkhardt JK, Lasker GF, Winkler EA, Kim H, Lawton MT. Microsurgical resection of brain arteriovenous malformations in the elderly: Outcomes analysis and risk stratification. *J Neurosurg* 2018;129:1107-13.
- Ogilvy CS, Stieg PE, Awad I, Brown RD Jr, Kondziolka D, Rosenwasser R *et al.* Special Writing Group of the Stroke Council, American Stroke Association. AHA Scientific Statement: Recommendations for the management of intracranial arteriovenous malformations: A statement for healthcare professionals from a special writing group of the Stroke Council, American Stroke Association. *Stroke* 2001;32:1458-71.
- Starke RM, Komotar RJ, Hwang BY, Fischer LE, Garrett MC, Otten ML, *et al.* Treatment guidelines for cerebral arteriovenous malformation microsurgery. *Br J Neurosurg* 2009;23:376-86.
- Ponce FA, Spetzler RF. Arteriovenous malformations: Classification to cure. *Clin Neurosurg* 2011;58:10-2.
- Mohr JP, Parides MK, Stapf C, Moquete E, Moy CS, Overbey JR, *et al.* Medical management with or without interventional therapy for unruptured brain arteriovenous malformations (ARUBA): A multicentre, non-blinded, randomised trial. *Lancet* 2014;383:614-21.
- Mohr JP, Overbey JR, Hartmann A, Kummer RV, Al-Shahi Salman R, Kim H, *et al.* Medical management with interventional therapy versus medical management alone for unruptured brain arteriovenous malformations (ARUBA): Final follow-up of a multicentre, non-blinded, randomised controlled trial. *Lancet Neurol* 2020;19:573-81.
- Abla AA, Rutledge WC, Seymour ZA, Guo D, Kim H, Gupta N, *et al.* A treatment paradigm for high-grade brain arteriovenous malformations: Volume-staged radiosurgical downgrading followed by microsurgical resection. *J Neurosurg* 2015;122:419-32.
- Pollock BE, Flickinger JC. Modification of the radiosurgery-based arteriovenous malformation grading system. *Neurosurgery* 2008;63:239-43.
- Davidson AS, Morgan MK. How safe is arteriovenous malformation surgery? A prospective, observational study of surgery as first-line treatment for brain arteriovenous malformations. *Neurosurgery* 2010;66:498-504.
- Kuhmonen J, Piippo A, Väärt K, Karatas A, Ishii K, Winkler P, *et al.* Early surgery for ruptured cerebral arteriovenous malformations. *Acta Neurochir Suppl* 2005;94:111-4.
- Pikus HJ, Beach ML, Harbaugh RE. Microsurgical treatment of arteriovenous malformations: Analysis and comparison with stereotactic radio- surgery. *J Neurosurg* 1998;88:641-6.
- Stapf C, Khaw AV, Sciacca RR, Hofmeister C, Schumacher HC, Pile-Spellman J, *et al.* Effect of age on clinical and morphological characteristics in patients with brain arteriovenous malformation. *Stroke* 2003;34:2664-9.
- van Beijnum J, van der Worp HB, Buis DR, Al-Shahi Salman R, Kappelle LJ, Rinkel GJ, *et al.* Treatment of brain arteriovenous malformations: A systematic review and meta-analysis. *JAMA* 2011;306:2011-9.
- Sanchez-Mejia RO, Chennupati SK, Gupta N, Fullerton H, Young WL, Lawton MT. Superior outcomes in children compared with adults after microsurgical resection of brain arteriovenous malformations. *J Neurosurg* 2006;105:82-7.
- Hartmann A, Mast H, Mohr JP, Koennecke HC, Osipov A, Pile-Spellman J, *et al.* Morbidity of intracranial hemorrhage in patients with cerebral arteriovenous malformation. *Stroke* 1998;29:931-4.
- Spetzler RF, Martin NA. A proposed grading system for arteriovenous malformations. *J Neurosurg* 1986;65:476-83.
- Ferch RD, Morgan MK. High-grade arteriovenous malformations and their management. *J Clin Neurosci* 2002;9:37-40.