

## Case Report

# Facial Nerve Paralysis Occurring 4 Days following Stereotactic Radiosurgery for a Vestibular Schwannoma

## Abstract

Stereotactic radiosurgery (SRS) is commonly used for the treatment of vestibular schwannomas given its high rate of tumor control and low rate of complications. Facial nerve palsy has been reported several months after treatment as a rare late complication of SRS. Here, we report a case of facial weakness occurring only 4 days after treatment and discuss potential etiology and management considerations.

**Keywords:** Facial palsy, stereotactic radiosurgery, vestibular schwannoma

## Introduction

Vestibular schwannomas (VS) are slow-growing brain tumors that can be managed through observation, microsurgical resection, fractionated radiation therapy, stereotactic radiosurgery (SRS), or a combination thereof.<sup>[1]</sup> The management of VS is typically individualized following a discussion between the patient and provider of the risks and benefits of the various treatment modalities. SRS has become an increasingly utilized treatment for VS given that it is noninvasive and has demonstrated high rates of tumor control.<sup>[2-4]</sup> Nonacoustic complications of SRS are fairly rare but include trigeminal nerve dysfunction and facial nerve palsy.<sup>[5]</sup>

Facial nerve dysfunction occurs from 0 to 6% of patients treated with SRS in modern studies with marginal doses of 13 Gy or less.<sup>[6,7]</sup> Although transient posttreatment hemifacial spasm occurs in up to 2% of patients, no permanent facial weakness has been seen with hypofractionated SRS consisting of 18 Gy in three fractions or 25 Gy in five fractions.<sup>[2,8]</sup> When facial weakness occurs, it is often noted as a late complication occurring over 4 months following SRS.<sup>[7]</sup> Here, we present a case of a patient with a vestibular schwannoma who was treated with single fraction SRS and developed facial weakness 4 days after his treatment.

This is an open access journal, and articles are distributed under the terms of the Creative Commons Attribution-NonCommercial-ShareAlike 4.0 License, which allows others to remix, tweak, and build upon the work non-commercially, as long as appropriate credit is given and the new creations are licensed under the identical terms.

For reprints contact: reprints@medknow.com

## Case Report

Following institutional review board approval for a retrospective review of this patient's outcomes, data were collected. The patient initially presented as a review of this case is covered by a Stanford IRB-approved protocol with a history of hypertension, hyperlipidemia, type 2 diabetes mellitus, T-cell lymphoma in remission status postchemotherapy approximately 4 years prior, and left nasal ala basal cell carcinoma status post radiation therapy 3 years prior, who presented with left-sided progressive hearing loss and tinnitus. He had slight gait unsteadiness, but denied vertigo, facial pain, facial weakness, facial numbness, or diplopia. Initial audiometry revealed a speech reception threshold of 50 dB on the left versus 25 dB on the right, and word recognition of 0% at 90 dB on the left versus 100% at 65 dB on the right. An magnetic resonance imaging (MRI) demonstrated a 13 mm × 6 mm vestibular schwannoma in the left internal auditory canal. Following 18 months of observation, serial imaging demonstrated interval growth of the tumor to 16 mm × 9 mm.

On physical examination, the patient had no hearing on the left side. His facial nerve function was fully intact bilaterally. He had a steady gait and was able to tandem walk without difficulty. Our institutional standard is to hypofractionate SRS (18 Gy in 3 fractions) for large schwannomas and those with serviceable hearing. Given

**How to cite this article:** Chow KK, Ajlan A, Ho AL, Li G, Soltys SG. Facial nerve paralysis occurring 4 days following stereotactic radiosurgery for a vestibular schwannoma. *Asian J Neurosurg* 2019;14:262-5.

**Kevin Kwong-Hon Chow<sup>1</sup>,**  
**Abdulrazag Ajlan<sup>1,2</sup>,**  
**Allen Lin Ho<sup>1</sup>,**  
**Gordon Li<sup>1,2</sup>,**  
**Scott Gerard Soltys<sup>2,3</sup>**

Departments of <sup>1</sup>Neurosurgery and <sup>3</sup>Radiation Oncology, Stanford University, <sup>2</sup>Stanford Cancer Institute, Stanford University, California, USA

**Address for correspondence:**  
Dr. Kevin Kwong-Hon Chow,  
Department of Neurosurgery,  
Stanford Hospital and Clinics,  
300 Pasteur Drive, R200/MC:  
5327, Stanford, CA 94305, USA.  
E-mail: khchow@stanford.edu

### Access this article online

Website: [www.asianjns.org](http://www.asianjns.org)

DOI: 10.4103/ajns.AJNS\_53\_17

### Quick Response Code:



his absence of hearing, he received 14 Gy in a single fraction to the 80% isodose line covering the 0.508 cm<sup>3</sup> tumor (conformity index  $\times 1.24$ ). He tolerated the procedure well, with no unanticipated adverse events.

Four days after radiosurgery, the patient noted left lip numbness and a sensation of left eye swelling. The following day, he woke up with a left facial droop and inability to close his left eye. An MRI displayed a slight increase in size of the Cerebellopontine angle (CPA) portion of the vestibular schwannoma to 10 mm  $\times$  8 mm compared to 9 mm  $\times$  6 mm pre-SRS with central hypo-intensity along with increased enhancement of the left facial nerve [Figure 1]. He had House–Brackmann (HB) 5/6 left facial weakness, unable to close his eyes, with decreased facial tone and obvious asymmetry. He denied facial numbness. He was started on dexamethasone 4 mg twice a day and valacyclovir for possible radiation-induced viral reactivation.

At 1-month follow-up, his facial droop improved slightly to HB 4/6 with improved, but still incomplete, eye closure, and facial asymmetry. Dexamethasone and valacyclovir were discontinued. At 6 months follow-up, his facial weakness improved to HB 3/6, able to close his eye and with much-improved tone and symmetry. Repeat MRI displayed stable size of the tumor and stable mild asymmetric enhancement of the facial nerve, with a more homogeneous enhancement of the schwannoma as is typically seen following SRS. At 1-year follow-up, his facial weakness continued to improve to HB 2/6 with signs of facial synkinesis manifest as difficulty relaxing his lip without closing his eyes. MRI showed stable size of the vestibular schwannoma and stable asymmetric facial nerve enhancement. At 2 years of follow-up, his left face gradually improved. He had HB 2/6 with largely resolved facial nerve synkinesis. MRI again showed a stable left CPA mass and stable asymmetric enhancement of the facial nerve.

## Discussion

SRS is a noninvasive standard of care for the treatment of VS, providing high rates of local control with low rates of complication. While facial weakness is a rare complication of SRS, generally occurring in 0%–6% of patients treated with single fraction SRS,<sup>[6,7]</sup> it typically occurs late in the treatment course. We present a case of acute facial weakness occurring days following SRS. This patient developed HB 5/6 facial weakness which improved over several months to HB 2/6. MRI obtained at the first follow-up visit showed slight enlargement of the tumor and enhancement of the facial nerve.

In general, the mechanism of SRS-associated facial weakness is unknown. Similarly, the time frame during which toxicity is seen is not well reported. Although the etiology in this case is uncertain, tumor expansion

following SRS may have caused direct compression of the facial nerve resulting in transient paresis. Although tumor swelling and the characteristic imaging changes of central loss of enhancement followed by a return of more homogeneous enhancement pattern are common following SRS,<sup>[9]</sup> the time point at which these changes are seen is unknown, as we normally obtain the first MRI no sooner than 6 months following treatment. One may hypothesize that the post-SRS swelling is rarely symptomatic due to its development over months. In our patient, it developed within 4 days, with less time for potential compensation of this swelling and resultant facial weakness. Dexamethasone was started in an attempt to relieve any mass effect on the facial nerve.

Alternatively, one may hypothesize that irradiation of the facial nerve may have caused a viral reactivation leading to a Bell's palsy, similar to reactivation of hepatitis B after radiotherapy for hepatobiliary malignancies.<sup>[10]</sup> Valacyclovir was therefore initiated.

Multiple risk factors for facial nerve toxicity following SRS have been identified, including patient factors such as tumor size  $>1.5$  cm<sup>3</sup>,<sup>[6]</sup> age  $>60$ ,<sup>[6]</sup> prior surgical resection,<sup>[11]</sup> and dosimetric factors such as brainstem dose,<sup>[11]</sup> prescription dose,<sup>[3,6,11]</sup> and fractionation of the treatments.<sup>[2,12-14]</sup> Length of cranial nerve irradiated may also increase risk for toxicity as shown in studies of SRS for trigeminal neuralgia.<sup>[15]</sup> Although the length of nerve irradiation in our patients was short and the tumor volume was small, risk factors for facial nerve toxicity included his age, a slightly higher marginal dose (14 Gy) than what is conventionally prescribed at our institution for single fraction treatments (typically 13 Gy) and, arguably, the use of a single fraction rather than a hypofractionated treatment course. In our series of 383 patients treated with 18 Gy in three fractions, no facial weakness was seen.<sup>[2]</sup>

## Conclusion

Although facial nerve toxicity following single fraction SRS is typically considered a late side effect, acute toxicity can occur. To the best of our knowledge, the facial weakness seen 4 days following treatment is the earliest reported facial palsy for vestibular schwannoma SRS. Marginal doses of 13 Gy or less in 1 fraction and, potentially, hypofractionation of treatment may decrease the risk of facial nerve toxicity. To minimize cranial nerve toxicity, our practice is to treat the majority of patients with 18 Gy in 3 consecutive days; those with small tumors without serviceable hearing may be treated with 12–13 Gy in a single fraction.

## Financial support and sponsorship

Nil.

## Conflicts of interest

There are no conflicts of interest

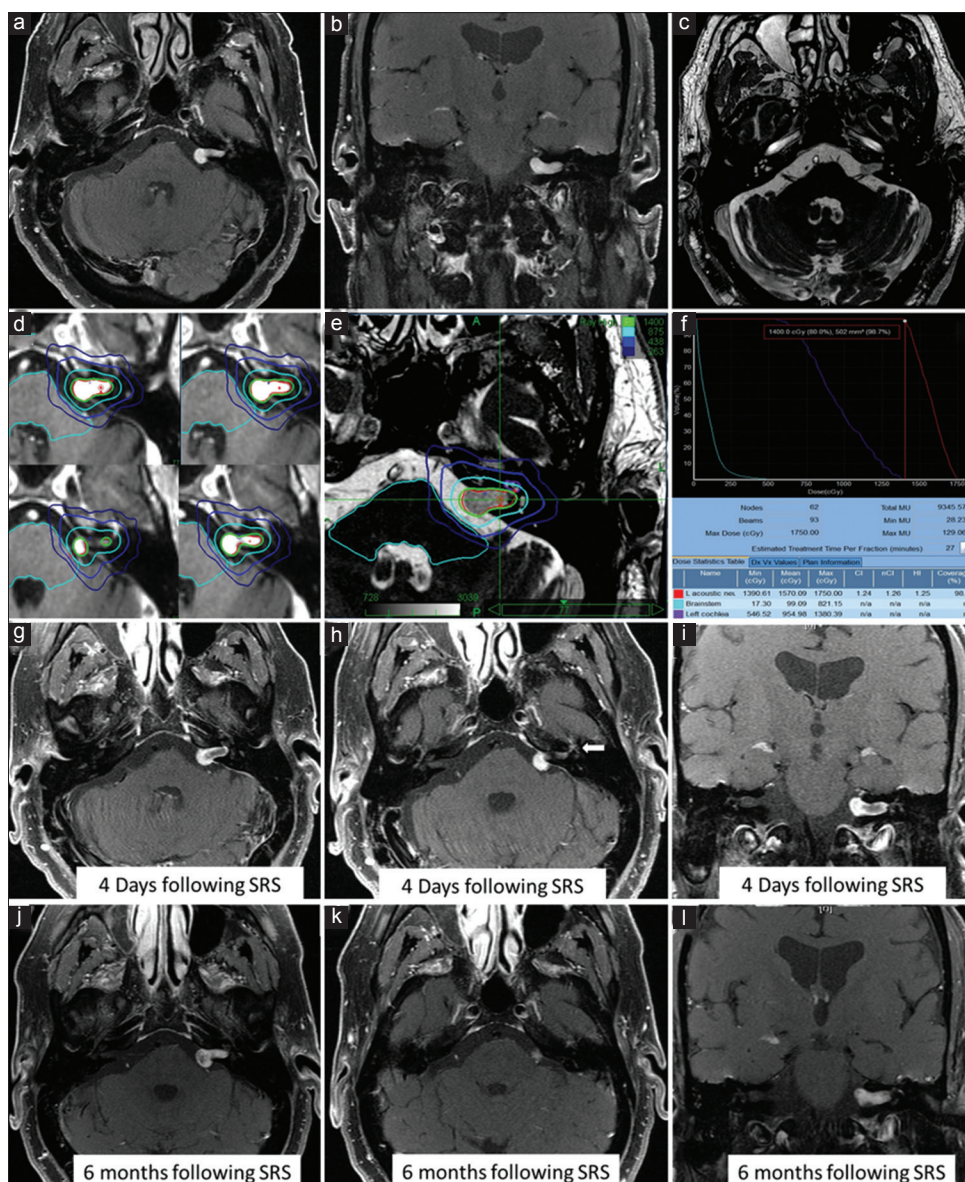


Figure 1: (a-c) Postcontrast and Fast Imaging Employing Steady-state Acquisition magnetic resonance imaging showing vestibular schwannoma in the left intrasellar arachnoid cyst (d-f) Treatment plan: Axial postcontrast and fast imaging employing steady-state acquisition magnetic resonance imaging showing targeted lesion in red, covered by the 14 Gy green prescription isodose line of 80%. Facial nerve received 4.4 Gy (light blue line). The red point represents maximum dose of 17.5 Gy (g-i) 4-day follow-up post-contrast magnetic resonance imaging's at the time of the acute facial weakness. The facial nerve tympanic segment and geniculate ganglion showed increased enhancement (arrow) (j-l) Postcontrast magnetic resonance imaging 6 months following stereotactic radiosurgery with overall stable size of the tumor

## References

- Kondziolka D, Mousavi SH, Kano H, Flickinger JC, Lunsford LD. The newly diagnosed vestibular schwannoma: Radiosurgery, resection, or observation? *Neurosurg Focus* 2012;33:E8.
- Hansasuta A, Choi CY, Gibbs IC, Soltys SG, Tse VC, Lieberon RE, et al. Multisession stereotactic radiosurgery for vestibular schwannomas: Single-institution experience with 383 cases. *Neurosurgery* 2011;69:1200-9.
- Hasegawa T, Kida Y, Kato T, Iizuka H, Kuramitsu S, Yamamoto T, et al. Long-term safety and efficacy of stereotactic radiosurgery for vestibular schwannomas: Evaluation of 440 patients more than 10 years after treatment with gamma knife surgery. *J Neurosurg* 2013;118:557-65.
- Lunsford LD, Niranjan A, Flickinger JC, Maitz A, Kondziolka D. Radiosurgery of vestibular schwannomas: Summary of experience in 829 cases. *J Neurosurg* 2005;Suppl 102:195-9.
- Sughrue ME, Yang I, Han SJ, Aranda D, Kane AJ, Amols M, et al. Non-audiofacial morbidity after gamma knife surgery for vestibular schwannoma. *Neurosurg Focus* 2009;27:E4.
- Yang I, Sughrue ME, Han SJ, Fang S, Aranda D, Cheung SW, et al. Facial nerve preservation after vestibular schwannoma gamma knife radiosurgery. *J Neurooncol* 2009;93:41-8.
- Badakhshi H, Graf R, Böhmer D, Synowitz M, Wiener E, Budach V, et al. Results for local control and functional outcome after linac-based image-guided stereotactic radiosurgery in 190 patients with vestibular schwannoma. *J Radiat Res* 2014;55:288-92.
- Karam SD, Tai A, Strohl A, Steehler MK, Rashid A, Gagnon G,

- et al.* Frameless fractionated stereotactic radiosurgery for vestibular schwannomas: A single-institution experience. *Front Oncol* 2013;3:121.
9. Link MJ, Driscoll CL, Foote RL, Pollock BE. Radiation therapy and radiosurgery for vestibular schwannomas: Indications, techniques, and results. *Otolaryngol Clin North Am* 2012;45:353-66, viii-ix.
  10. Chou CH, Chen PJ, Lee PH, Cheng AL, Hsu HC, Cheng JC, *et al.* Radiation-induced hepatitis B virus reactivation in liver mediated by the bystander effect from irradiated endothelial cells. *Clin Cancer Res* 2007;13:851-7.
  11. Foote KD, Friedman WA, Buatti JM, Meeks SL, Bova FJ, Kubilis PS, *et al.* Analysis of risk factors associated with radiosurgery for vestibular schwannoma. *J Neurosurg* 2001;95:440-9.
  12. Collen C, Ampe B, Gevaert T, Moens M, Linthout N, De Ridder M, *et al.* Single fraction versus fractionated linac-based stereotactic radiotherapy for vestibular schwannoma: A single-institution experience. *Int J Radiat Oncol Biol Phys* 2011;81:e503-9.
  13. Choy W, Spasic M, Pezeshkian P, Fong BM, Nagasawa DT, Trang A, *et al.* Outcomes of stereotactic radiosurgery and stereotactic radiotherapy for the treatment of vestibular schwannoma. *Neurosurgery* 2013;60 Suppl 1:120-5.
  14. Combs SE, Welzel T, Schulz-Ertner D, Huber PE, Debus J. Differences in clinical results after LINAC-based single-dose radiosurgery versus fractionated stereotactic radiotherapy for patients with vestibular schwannomas. *Int J Radiat Oncol Biol Phys* 2010;76:193-200.
  15. Flickinger JC, Pollock BE, Kondziolka D, Phuong LK, Foote RL, Stafford SL, *et al.* Does increased nerve length within the treatment volume improve trigeminal neuralgia radiosurgery? A prospective double-blind, randomized study. *Int J Radiat Oncol Biol Phys* 2001;51:449-54.