

## Endoscopic Third Ventriculostomy in Normal Pressure Hydrocephalus and Symptomatic Long-standing Overt Ventriculomegaly

### Abstract

**Objectives:** The aim of this study is to define the role and effectiveness for an endoscopic third ventriculostomy (ETV) in patients with seconder normal pressure hydrocephalus(SNPH), idiopathic normal pressure hydrocephalus (INPH) and symptomatic longstanding overt ventriculomegaly (SLOVA). **Materials and Methods:** 3 patients with SLOVA, 3 patients with INPH and 3 patients with SNPH underwent ETV were studied retrospectively. The patients had a follow-up of 1-6 years. Preoperative CT or/and MRI of the brain was done in all cases. Tap test was done in all cases. Clinical examination finding were classified according to the by Japanese Committee for Scientific Research (JCSS) on intractable Hydrocephalus. Patients were studied to evaluate of the patency of ventriculosthomy and aqueductus slyvius by a Cine PC MR and CSF\_DRIVE T2 Sequence MRI after 1-6 years. **Results:** Headache, gait disturbance and pollakiuria improved in three patients with SNPH underwent ETV, but dementia didn't improve in one patient. Pollakiuria and headache improved in three patients with INPH underwent ETV but preoperative gait disturbance grade three remained unchanged in one patient. Headache improved in three patients with SLOVA underwent ETV. Preoperative gait disturbance grade 3 remained unchanged in one patient, but improved pollakiuria. We confirmed the patency of a third ventriculostomy and decreasing degrees of CSF flow into the aqueductus sylvius. **Conclusions:** In properly selected patients with SNPH, SLOVA and INPH who had headache ,slight gait disturbance and pollakiuria , mainly those with a short duration of symptoms, ETV may provide good results.

**Keywords:** Endoscopic third ventriculostomy, hydrocephalus, idiopathic normal pressure hydrocephalus, long-standing overt ventriculomegaly

### Introduction

The term normal pressure hydrocephalus (NPH) was coined by Hakim in 1964;<sup>[25]</sup> later, Adams *et al.*<sup>[1]</sup> in 1965 used this term to define a clinical syndrome of progressive mental deterioration, gait disturbance, and urinary incontinence associated with hydrocephalus in the setting of normal cerebrospinal fluid (CSF) pressure. In the cases of idiopathic NPH (INPH), no inciting event is identified. However, secondary NPH (SNPH) may develop after subarachnoid hemorrhage, brain injury, and meningitis which probably interfere with CSF absorption.<sup>[27,41]</sup> Symptomatic long-standing overt ventriculomegaly in adults (SLOVA) can present with signs and symptoms associated with NPH.<sup>[18,34,45]</sup> The pathophysiological basis of long-standing overt ventriculomegaly (LOVA) is thought to be decreased intracranial compliance associated with relatively high intracranial

pressure (ICP) dynamics.<sup>[45]</sup> The aqueductal stenosis in LOVA is thought to arise congenitally, leading to the associated feature of macrocephaly and expanded or obliterated sella turcica.<sup>[34,38,45]</sup> It remains uncertain why the hydrocephalic entity manifests in late adulthood. Patients with LOVA can decompensate at any time in their adult life with acute symptoms, which are generally well controlled with endoscopic third ventriculostomy (ETV).<sup>[2]</sup> Late-onset idiopathic aqueductal stenosis (LIAS) in contrast is thought to be acquired.<sup>[15,44]</sup> Differentiating LIAS from LOVA can be attempted based on the absence of macrocephaly and absence of expanded or obliterated sella turcica in LIAS as well as thorough medical history to determine a cause for acquired aqueductal stenosis.<sup>[34]</sup> It has been reported that LIAS patients can present 10–20 years younger than the patients with INPH.<sup>[3,34,35]</sup>

The traditional treatment for communicating hydrocephalus is shunt placement, but

### Mustafa Balevi

Department of Neurosurgery,  
Konya Numune Hospital,  
Konya, Turkey

#### Address for correspondence:

Dr. Mustafa Balevi,  
Department of Neurosurgery,  
Konya Numune Hospital,  
Turgut Özal Cd,  
Yazır Mh, 42100 Konya, Turkey.  
E-mail: mbalevi@gmail.com

#### Access this article online

Website: [www.asianjns.org](http://www.asianjns.org)

DOI: 10.4103/ajns.AJNS\_54\_15

#### Quick Response Code:



**How to cite this article:** Balevi M. Endoscopic third ventriculostomy in normal pressure hydrocephalus and symptomatic long-standing overt ventriculomegaly. *Asian J Neurosurg* 2017;12:605-12.

This is an open access article distributed under the terms of the Creative Commons Attribution-NonCommercial-ShareAlike 3.0 License, which allows others to remix, tweak, and build upon the work non-commercially, as long as the author is credited and the new creations are licensed under the identical terms.

For reprints contact: [reprints@medknow.com](mailto:reprints@medknow.com)

high failure rates and numerous complications with this therapy have been reported.<sup>[27,39,47,48,55]</sup> Endoscopic aqueductoplasty (EAP) is an option of the treatment of obstructive hydrocephalus caused by aqueductal stenosis.<sup>[10]</sup> ETV has become the preferred method to treat obstructive hydrocephalus because of its minimally invasive nature.<sup>[7,8,28,35,36,39,42,54,63]</sup> However, its utility in the treatment of patients with communicating hydrocephalus has not proven conclusively. Many authors suggest ETV for the treatment of NPH initially.<sup>[18,20,26,33,40,42,43]</sup> ETV reduces the increased systolic pressure in the brain by venting ventricular CSF through the stroma.<sup>[26]</sup>

Phase-contrast magnetic resonance imaging (PC MRI) flow study (Cine PC MR imaging) and CSF\_DRIVE pulse to the T2-weighted 3D TSE sequence MRI (CSF\_DRIVE T2 secans MRI) are a reliable technique for detecting the patency of a third ventriculostomy<sup>[60]</sup> and aqueduct of Sylvius.<sup>[22,61]</sup>

**Materials and Methods**

Three patients with SLOVA, three patients with INPH, and three patients with SNPH underwent ETV at our institution were studied retrospectively. The patients had a follow-up of 1–6 years. Preoperative computed tomography (CT) or/and MRI of the brain was done in all cases [Figures 1-3]. All patients were assessed with walking and psychometric tests before tap test assessments. Tap test was done in all cases because it is the standard test used in these cases. The tap test was regarded as positive if two or more of three different test items improved after CSF removal. Walking and psychometric tests used to assess patients postoperatively.

ETV was performed with a freehand standard method using a rigid endoscope in all nine patients. Outcome was evaluated according to the data collected at the last follow-up visit. Clinical examination findings on intractable hydrocephalus were classified according to the Japanese

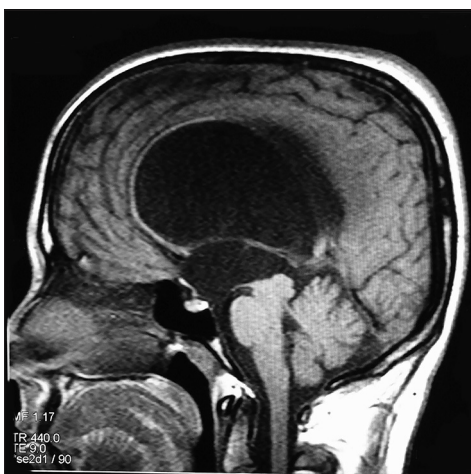Committee for Scientific Research's (JCSR) grading score [Table 1]. The cumulative score of the triad of symptoms was used for determining the severity of the clinical syndrome (total grade: 0–12).

We used a risk ratio (RR) scale tolerated postoperative improvement to the preoperative status:  $RR = (\text{preoperative} - \text{postoperative JCSR score} / \text{preoperative JCSR score} \times 100)$ .

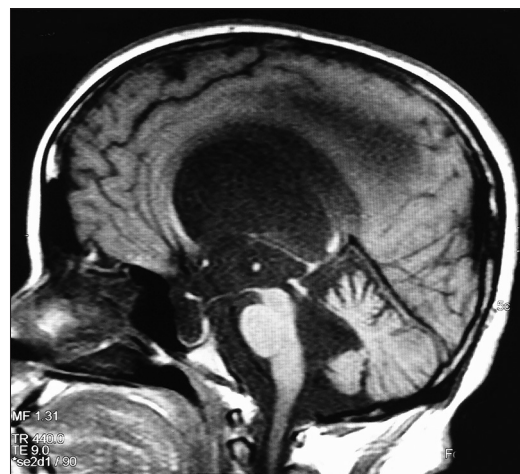Clinical outcome was defined as excellent (RR: 75–100 points), good (RR: 50–75 points), satisfactory (RR: 25–50 points), and poor (RR  $\leq$ 25points). Any patient who died as a result of the ETV procedure or had to

**Table 1: Japanese Committee for Scientific Research's (JCSR) grading score on intractable hydrocephalus**

<b>Gait disturbance</b>	
0	Normal
1	Unstable but independent gait
2	Walking with one cane
3	Walking with two canes or a walker frame
4	Walking not possible
<b>Dementia</b>	
0	Within normal range
1	No apperent dementia but apathic
2	Socially dependent but independent at home
3	Partially dependent at home
4	Totally dependent
<b>Urinary incontinence</b>	
0	Absent
1	Absent but with pollakiuria or urinary urgency
2	Sometimes only at night
3	Sometimes even during the day
4	Frequent



**Figure 1: Preoperative T1 sagittal magnetic resonance imaging scan demonstrating an inferiorly bowed floor of the third ventricle**



**Figure 2: Preoperative T1 sagittal magnetic resonance imaging scan demonstrating an inferiorly bowed floor of the third ventricle and open cerebral aqueduct**

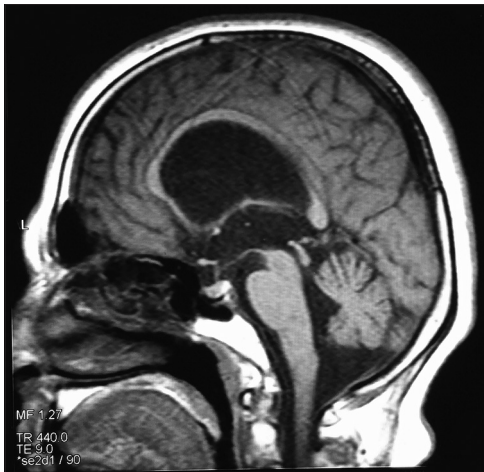

Figure 3: Preoperative T1 sagittal magnetic resonance imaging scan demonstrating an inferiorly bowed floor of the third ventricle

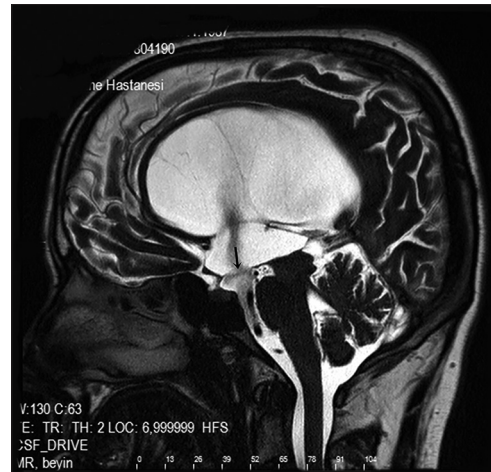


Figure 4: Postoperative sagittal CSF\_DRIVE T2 secans magnetic resonance imaging demonstrating a third ventriculostomy patency (black arrow). Continuous (patent) cerebrospinal fluid flow is observed from the foramen of Monro to the prepontine cistern. Superior to inferior flow is shown in black

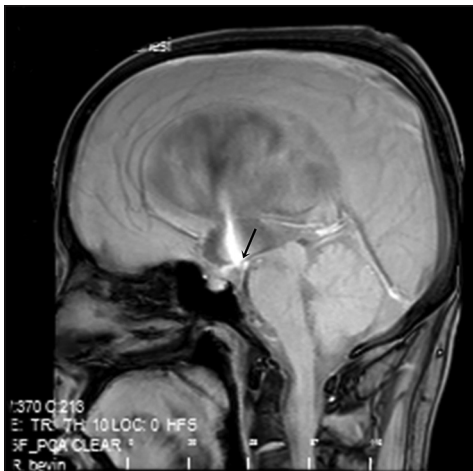

Figure 5: Sagittal cine phase-contrast magnetic resonance imaging after 6 years. Continuous (patent) cerebrospinal fluid flow is observed from the foramen of Monro to the prepontine cistern. Superior to inferior flow is shown in white

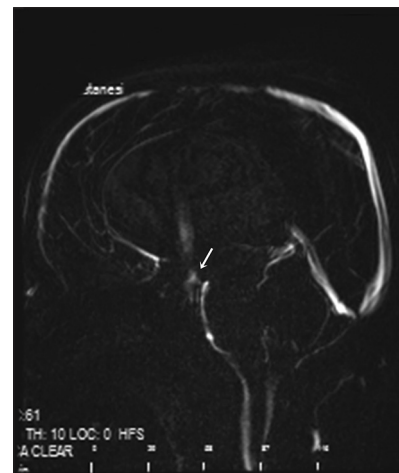


Figure 6: Continuous (patent) cerebrospinal fluid flow is observed from the foramen of Monro to the prepontine cistern (white arrow), but aqueductal flow is not observed

undergo shunt placement after ETV was described as having a poor outcome [Table 3]. Postoperative evaluation was made by clinical controls at 1 month, 6 months, 2 years, and 6 years. MRI or CT examination was performed in all patients after operation. Cine PC MR and CSF\_DRIVE T2 sequence MRI were performed only in six patients after an average of 5.5 years [Figures 4-9].

Postoperative CT or/and MRI was done in all cases. Six patients were studied to evaluate of the patency of ventriculostomy and aqueduct of Sylvius by a Cine PC MR and CSF\_DRIVE T2 sequence MRI after 1–6 years.

## Results

The range of positive response to a spinal tap test was 90% in nine patients. There were no major intraoperative complications. No deaths related to surgery or permanent neurological deficits occurred. All patients had no

confirmed occlusion of the stroma after 1–6 years. There were no confirmed infections.

The cause of communicating hydrocephalus in the three patients with SNPH was determined to be hypertensive intracerebral hemorrhage (HIH) in two and combined with hypertension and cerebral infarction in one. The patients ranged in age from 51 to 65 years old (mean 60 years old). The actual follow-up ranged from 1 to 5 years. The Japanese Cosmetic Science Society (JCSS) scores of two patients were 2. JCSS score of one patient with dementia was 3 [Tables 2 and 3]. Three patients with SNPH presented gait instability and pollakiuria at the time of surgery; in all of them, gait disorder and pollakiuria resolved completely. Dementia as reported by one patient, but this patient remained stable.

Three patients with INPH underwent ETV ranged in age from 31 to 51 years old (average 40 years old). Follow-up period was 5 years. JCSS scores of two patients were

2 points. JCSS score of one patient was 4. Among the group of INPH (three patients), all patients showed

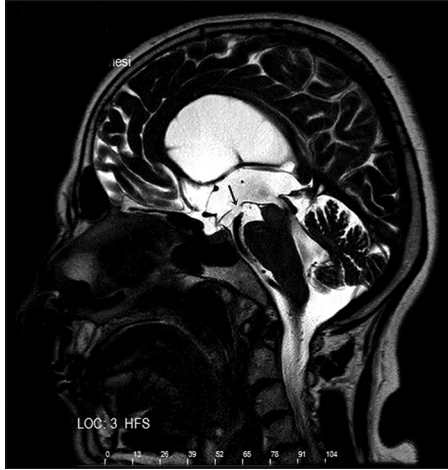


Figure 7: Postoperative sagittal CSF\_DRIVE T2 secans magnetic resonance imaging demonstrating a third ventriculostomy patency (black arrow)

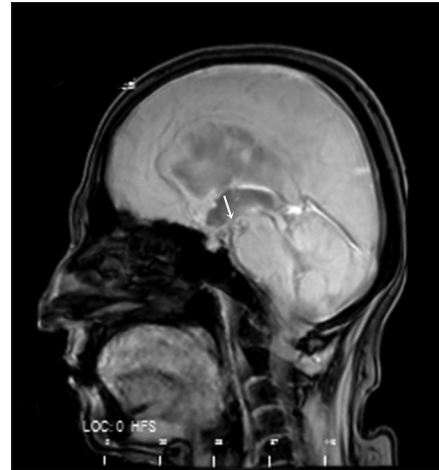

Figure 8: Sagittal cine phase-contrast magnetic resonance imaging after 5 years. Continuous (patent) cerebrospinal fluid flow is observed from the foramen of Monro to the prepontine cistern. Superior to inferior flow is shown in black (black arrow)

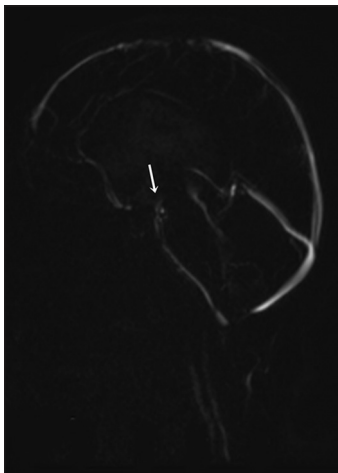


Figure 9: Sagittal cine phase-contrast magnetic resonance imaging after 5 years. Continuous (patent) cerebrospinal fluid flow from the foramen of Monro to the prepontine cistern (white arrow) and aqueductal flow are observed

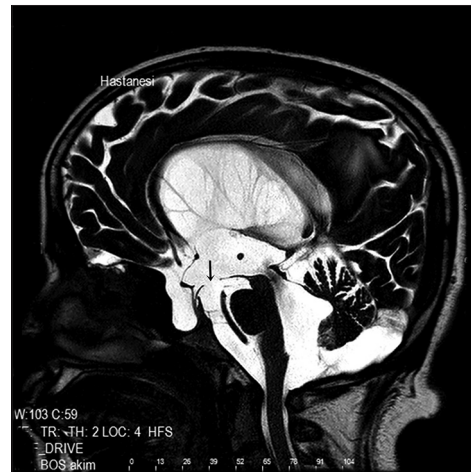


Figure 10: Postoperative sagittal CSF\_DRIVE T2 secans magnetic resonance imaging demonstrating a third ventriculostomy patency (black arrow) after 6 years

Table 2: .JCSS's grading scores of the patients

	Age	Sex	FU period year	Commorbidity	JCSS Grading score	
					Preoperative	Postoperative
SNPH	51	M	1	HIH	2	0
	64	M	1	HIH	2	0
	65	F	5	LE + DM + HP	3	1
SLOVA	28	F	6	HI	2	0
	32	M	6	HI	2	0
	31	F	6	None	4	3
INPH	31	M	5	None	4	3
	38	F	5	None	2	0
	51	F	5	None	2	0

HIH – Hypertensive intracranial hemorrhage, LE – Lacunar enfact, HI – Head injury

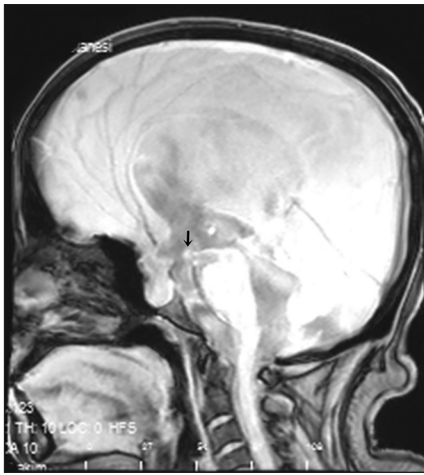

Figure 11: Sagittal cine phase-contrast magnetic resonance imaging after 6 years. Continuous (patent) cerebrospinal fluid flow is observed from the foramen of Monro to the prepontine cistern. Superior to inferior flow is shown in black (black arrow)

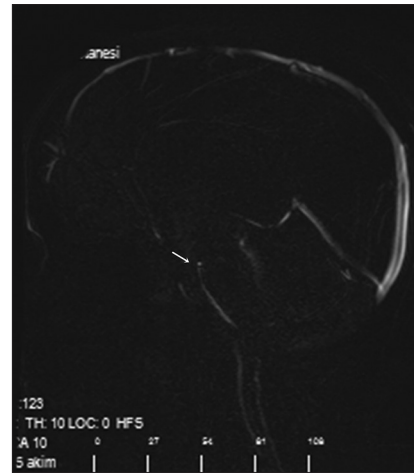


Figure 12: Sagittal cine phase-contrast magnetic resonance imaging after 6 years. Continuous (patent) cerebrospinal fluid flow from the foramen of Monro to the prepontine cistern (white arrow) and aqueductal flow are observed

**Table 3: Comparison of outcomes according to RR scale after ETV between the INPH, SLOVA and SNPH groups**

Outcome	SNPH	SLOVA	INPH	Total
Excellent	2	2	2	6
Good	1	0	0	1
Satisfactory	0	1	1	2

improvement in headache and gait; two patients revealed complete resolution of walking disorders while one patient with 4 score remained stable. Pollakiuria was recorded in three patients; this disorder improved in all of them [Tables 2 and 3]. The patency of a third ventriculostomy of these patients was confirmed by Cine PC MR imaging and CSF\_DRIVE T2 secans MRI [Figures 10-12] 5 years later.

Three patients with SLOVA ranged in age from 28 to 32 years old (mean 30.3 years old). Mean head circumference of patients was 61 cm. Follow-up period was 6 years. The causes of decompensation of two patients with SLOVA cases were head injury (HI) (in one patient, this was traumatic intracerebral hemorrhage operated by craniectomy, and in one patient, this was chronic subdural hematoma operated by burr-hole drainage and dysfunction of ventriculoperitoneal [VP] shunting). JCSS scores of two patients were 2. JCSS score of one patient was 4 [Tables 2 and 3]. Among the group of SLOVA (three patients), all patients showed improvement in headache and pollakiuria. Three patients presented gait instability at the time of surgery; in two of them, gait disorder resolved completely while one patient with 4 score remained stable [Tables 2 and 3]. We confirmed the patency of a third ventriculostomy and decreasing degrees of CSF flow into the aqueduct of Sylvius by Cine PC MR imaging and CSF\_DRIVE T2 secans MRI 6 years after ETV [Figures 2, 4-6, and 10-12].

### Discussion

The precise underlying mechanisms of communicating hydrocephalus remain unknown. Communicating hydrocephalus is caused by decreased compliance, increasing the systolic pressure transmission into the brain.<sup>[20,26,34]</sup> The systolic force compresses the brain, including the intracranial capacitance, cerebral veins, and capillaries. If the CSF pressure exceeds the venous pressure, the cerebral ventricles enlarge progressively. Although the ventricular enlargement may normalize the ICP, the systolic pulsations continue to chronically damage the brain parenchyma, which does not absorb them because of its increased elastance. This series of events results in a decrease of cerebral blood flow, insufficient cerebral perfusion pressure, and increased in ICP. The patent aqueduct in communicating hydrocephalus is too narrow to vent the ventricular CSF sufficiently.<sup>[23,24]</sup> Rekte explored the sites of obstruction to the flow of CSF that causes hydrocephalus.<sup>[49]</sup> These sites include not only the aqueduct and outlet foramina of the fourth ventricle but also the basal cisterns blocking the CSF a flow. The obstructive hydrocephalus would be called intraventricular and extraventricular. The intraventricular hydrocephalus includes both obstruction of the aqueduct and occlusion of the outlet foramina of the fourth ventricle. The extraventricular hydrocephalus includes the compression of CSF pathways by mass, i.e., tumors or hematomas. It is common belief that there is some extent of adhesive obstruction in the basal cisterns of communicating hydrocephalus caused by traumatic injury, HIH, and tubercular meningitis. Reasons that revealed symptoms in three patients with SNPH and two patients with LOVA were head injury (HI), HIH, meningitis, and lacunar infarct. No reason has been found in one LOVA case.

Both the lumbar infusion test<sup>[42,59,62]</sup> and the tap test<sup>[11,26,60]</sup> can predict a positive outcome of shunt operations in patient with suspected NPH. CSF tap test was done all patients by us. Clinical improvement after the lumbar puncture (which may be sustained for several days or weeks) indicates that the patient is likely to benefit from shunting; however, the tap test is not completely reliable.<sup>[26]</sup> The range of positive response to a spinal tap test was 90% in nine patients.

The traditional treatment for communicating hydrocephalus is shunt placement, but high failure rates and numerous complications with this therapy have been reported.<sup>[27,39,47,50]</sup> Torsnes *et al.* reviewed 430 articles about outcome of the patients with INPH after shunt treatment. Approximately 40% of the studies were prospective. The overall success rate from surgical treatment varied from 30% to 90%.<sup>[59]</sup> We observed 66.6% excellent success rate, and 33.3% satisfactory success rate in nine patients underwent ETV.

ETV is a safe and minimally invasive procedure that has been used since 1993 in the treatment of many types of hydrocephalus. The most common indications include primary aqueductal stenosis and triventricular hydrocephalus resulting from external aqueductal compression<sup>[6-8,13,28,31,35,36,39,42,52,54,63,64]</sup> and tetra-ventricular obstructive hydrocephalus<sup>[18,32]</sup> although this technique is also useful in NPH.<sup>[18,20,26,33,40,42,43]</sup>

ETV results in a slight decrease of the CSF pressure within the ventricular system, with a consequent increase of the cerebral blood flow and cerebral perfusion pressure and abolition of transependymal resorption.<sup>[26]</sup> The rapid transmission of the pressure wave through the ventriculostomy toward the basal cisterns could restore the normal CSF dynamics. Cerebral aqueductoplasty is an effective and successful treatment for membranous and/or short-segment stenosis of the sylvian aqueduct. EAP candidates must be selected very carefully, but longer follow-up periods are necessary to evaluate long-term aqueductal patency after aqueductoplasty.<sup>[10]</sup> The reclosure rate of aqueducts after EAP is higher than the reclosure rate of the ventriculostomy after ETV.<sup>[57]</sup> Aqueductoplasty with stenting is the procedure of choice for the treatment of isolated fourth ventricle.<sup>[51]</sup> Membranous and tumor-related aqueductal stenosis should be treated by ETV.<sup>[14,38]</sup>

Patients with LOVA can decompensate at any time in their adult life with acute symptoms. The cause of decompensation in two patients with SLOVA was long-segment aqueductal stenosis occurred after HI. There is no factor that decompensated in one patient with SLOVA. We performed ETV in three patients with SLOVA.<sup>[2,56]</sup> However, Kiefer *et al.* proposed that gravitational shunts may be considered an equivalent alternative to the third ventriculostomy for the treatment of SLOVA.<sup>[34]</sup> After ETV, we have observed excellent results in these patients. One patient has Grade 3 gait disturbance, Grade 1 urinary incontinence, and headache. After ETV, gait disturbance grade did not change, but headache and urinary urgency improved in 3 months.

We observed 66.6% excellent success rate and 33.3% satisfactory success rate in patient with SLOVA underwent ETV. Some authors reported 66%–89% rate of success in patients with SLOVA.<sup>[2,56]</sup>

Since ventricular size may change little after fenestration,<sup>[35]</sup> postoperative follow-up may rely primarily on resolution of clinical symptoms. The use of such a change as an arbiter of success in this procedure is questionable as clinically successful cases can have no change in ventricular size.<sup>[8]</sup> All patients had a satisfactory clinical outcome after ETV, but we did not observed a decrease of the ventricular size. Some authors considered that clinical outcome is the most important guide to success or failure as reduction in ventricular size is by no means guaranteed.<sup>[8]</sup> The others reported that a decrease of the ventricular size detected soon after ETV is associated with a satisfactory clinical outcome.<sup>[8,54]</sup> This response continues during the 1<sup>st</sup> few months after surgery. The reduction is more prominent in acute forms of hydrocephalus.<sup>[50,54]</sup>

Since ventricular size may change little after fenestration,<sup>[35]</sup> postoperative follow-up may rely primarily on resolution of clinical symptoms. When a patient presents with residual or recurrent symptoms after a third ventriculostomy, it is important to differentiate fenestration closure from malabsorption since the former may be explored for refenestration while the later requires shunting.

PC MRI flow study (Cine PC MR imaging) and CSF\_DRIVE pulse to the T2-weighted 3D TSE sequence MRI (CSF\_DRIVE T2 secans MRI) are a reliable technique for detecting the patency of a third ventriculostomy<sup>[60]</sup> and aqueduct of Sylvius.<sup>[22,61]</sup>

The overall success rate after ETV was 66% in patients with SNPH, SLOVA, and INPH. Some authors reported 21%–90% success rate for NPH<sup>[20,26,34]</sup> and 80% success rate for obstructive hydrocephalus cases after ETV.<sup>[19]</sup>

We believed that gait disturbance is just a reflection of local alterations in corresponding cortex and blood supply.<sup>[20,24]</sup> The range of clinical history and preoperative clinical score seems to significantly influence postoperative results; patients with a more recent onset of clinical symptoms and less severe preoperative neurological involvement fare significantly better. However, mental state reflects the preserved grade of whole-brain compliance and the extent of massive parenchymal damage.<sup>[20,24]</sup>

Complications occur in 7%–38% of the patients who undergo ETV.<sup>[20,27,29,53,59]</sup> Twenty-two percent of the patients require additional surgery, and 6% experienced permanent neurological deficit or death after shunting for INPH.<sup>[27,59]</sup> These mainly include hemorrhages related to the surgical procedure at the level of the choroid plexus, ventricular walls, ventriculostomy, or interpeduncular cistern, whereas intraparenchymal or subdural bleeding, transient neurological deficits, CSF leak, and infections are exceptional.<sup>[20]</sup> In our

series, we observed only one epidural frontal hematoma not requiring surgical evacuation (10%), but we did not observe postoperative subdural hematoma, subdural effusion, CSF leak, and infection. We did not observe to the reclosure of the ventriculostomy in all cases after 5.5 years.

Complication rate of all patients underwent ETV was lower than those treated with VP shunt in all NPH patients.<sup>[5,58]</sup>

We advise performing ETV in patients with less JCSS score and a clinical evolution of no more than 6 months before diagnosis.

## Conclusions

In properly selected patients with SNPH, SLOVA, and INPH who had headache, slight gait disturbance, and pollakiuria, mainly those with a short duration of symptoms, ETV provides good results.

## Financial support and sponsorship

Nil.

## Conflicts of interest

There are no conflicts of interest.

## References

- Adams RD, Fisher CM, Hakim S, Ojemann RG, Sweet WH. Symptomatic occult hydrocephalus with "normal" cerebrospinal-fluid pressure. A treatable syndrome. *N Engl J Med* 1965;273:117-26.
- Al-Jumaily M, Jones B, Hayhurst C, Jenkinson MD, Murphy P, Buxton N, *et al.* Long term neuropsychological outcome and management of 'decompensated' longstanding overt ventriculomegaly in adults. *Br J Neurosurg* 2012;26:717-21.
- Bergstrand G, Bergström M, Nordell B, Ståhlberg F, Ericsson A, Hemmingsson A, *et al.* Cardiac gated MR imaging of cerebrospinal fluid flow. *J Comput Assist Tomogr* 1985;9:1003-6.
- Bergsneider M, Miller C. Surgical management of adult hydrocephalus. *Neurosurgery* 2008;62:643-59.
- Bradley WG Jr., Kortman KE, Burgoyne B. Flowing cerebrospinal fluid in normal and hydrocephalic states: Appearance on MR images. *Radiology* 1986;159:611-6.
- Brockmeyer D, Abtin K, Carey L, Walker ML. Endoscopic third ventriculostomy: An outcome analysis. *Pediatr Neurosurg* 1998;28:236-40.
- Buxton N, Ho KJ, Macarthur D, Vloeberghs M, Punt J, Robertson I. Neuroendoscopic third ventriculostomy for hydrocephalus in adults: Report of a single unit's experience with 63 cases. *Surg Neurol* 2001;55:74-8.
- Buxton N, Turner B, Ramli N, Vloeberghs M. Changes in third ventricular size with neuroendoscopic third ventriculostomy: A blinded study. *J Neurol Neurosurg Psychiatry* 2002;72:385-7.
- Cinalli G, Sainte-Rose C, Chumas P, Zerah M, Brunelle F, Lot G, *et al.* Failure of third ventriculostomy in the treatment of aqueductal stenosis in children. *Neurosurg Focus* 1999;6:e3.
- da Silva LR, Cavalheiro S, Zymberg ST. Endoscopic aqueductoplasty in the treatment of aqueductal stenosis. *Childs Nerv Syst* 2007;23:1263-8.
- Shprecher D, Schwalb J, Kurlan R. Normal pressure hydrocephalus: Diagnosis and treatment. *Curr Neurol Neurosci Rep* 2008;8:371-6.
- Dixon GR, Friedman JA, Luetmer PH, Quast LM, McClelland RL, Petersen RC, *et al.* Use of cerebrospinal fluid flow rates measured by phase-contrast MR to predict outcome of ventriculoperitoneal shunting for idiopathic normal-pressure hydrocephalus. *Mayo Clin Proc* 2002;77:509-14.
- Egnor M, Zheng L, Rosiello A, Gutman F, Davis R. A model of pulsations in communicating hydrocephalus. *Pediatr Neurosurg* 2002;36:281-303.
- Fritsch MJ, Schroeder HW. Endoscopic aqueductoplasty and stenting. *World Neurosurg* 2013;79 2 Suppl: S20.e15-8.
- Fukuhara T, Luciano MG. Clinical features of late-onset idiopathic aqueductal stenosis. *Surg Neurol* 2001;55:132-6.
- Gallo P, Szathmari A, Simon E, Ricci-Franchi AC, Rousselle C, Hermier M, *et al.* The endoscopic trans-fourth ventricle aqueductoplasty and stent placement for the treatment of trapped fourth ventricle: Long-term results in a series of 18 consecutive patients. *Neurol India* 2012;60:271-7.
- Gangemi M, Donati P, Maiuri F, Longatti P, Godano U, Mascari C. Endoscopic third ventriculostomy for hydrocephalus. *Minim Invasive Neurosurg* 1999;42:128-32.
- Gangemi M, Maiuri F, Buonamassa S, Colella G, de Divitiis E. Endoscopic third ventriculostomy in idiopathic normal pressure hydrocephalus. *Neurosurgery* 2004;55:129-34.
- Gangemi M, Maiuri F, Colella G, Magro F, Seneca V, de Divitiis E. Is endoscopic third ventriculostomy an internal shunt alone? *Minim Invasive Neurosurg* 2007;50:47-50.
- Gangemi M, Maiuri F, Naddeo M, Godano U, Mascari C, Broggi G, *et al.* Endoscopic third ventriculostomy in idiopathic normal pressure hydrocephalus: An Italian multicenter study. *Neurosurgery* 2008;63:62-7.
- Goumnerova LC, Frim DM. Treatment of hydrocephalus with third ventriculocisternostomy: Outcome and CSF flow patterns. *Pediatr Neurosurg* 1997;27:149-52.
- Gorucu Y, Albayram S, Balci B, Hasiloglu ZI, Yenigul K, Yargic F, *et al.* Cerebrospinal fluid flow dynamics in patients with multiple sclerosis: A phase contrast magnetic resonance study. *Funct Neurol* 2011;26:215-22.
- Greitz D. Reprint of: Radiological assessment of hydrocephalus: New theories and implications for therapy. *Neuroradiol J* 2006;19:475-95.
- Greitz D. Paradigm shift in hydrocephalus research in legacy of Dandy's pioneering work: Rationale for third ventriculostomy in communicating hydrocephalus. *Childs Nerv Syst* 2007;23:487-9.
- Hakim S. Algunas Observaciones Sobre Lapresion del LCR Sindrome Hidrocefalico en Adulto con 'Presion Normal' del LCR, (Dissertation). Bogota: Universidad Javeriana; 1964. p. 2.
- Hailong F, Guangfu H, Haibin T, Hong P, Yong C, Weidong L, *et al.* Endoscopic third ventriculostomy in the management of communicating hydrocephalus: A preliminary study. *J Neurosurg* 2008;109:923-30.
- Hebb AO, Cusimano MD. Idiopathic normal pressure hydrocephalus: A systematic review of diagnosis and outcome. *Neurosurgery* 2001;49:1166-84.
- Hopf NJ, Grunert P, Fries G, Resch KD, Perneczky A. Endoscopic third ventriculostomy: Outcome analysis of 100 consecutive procedures. *Neurosurgery* 1999;44:795-804.
- Jones RF, Kwok BC, Stening WA, Vonau M. The current status of endoscopic third ventriculostomy in the management of non-communicating hydrocephalus. *Minim Invasive Neurosurg* 1994;37:28-36.

30. Jones RF, Kwok BC, Stening WA, Vonau M. The current status of endoscopic third ventriculostomy in the management of non-communicating hydrocephalus. *Minim Invasive Neurosurg* 1994;37:28-36.
31. Jones RF, Stening WA, Brydon M. Endoscopic third ventriculostomy. *Neurosurgery* 1990;26:86-91.
32. Jack CR Jr., Kelly PJ. Stereotactic third ventriculostomy: Assessment of patency with MR imaging. *AJNR Am J Neuroradiol* 1989;10:515-22.
33. Kandasamy J, Yousaf J, Mallucci C. Third ventriculostomy in normal pressure hydrocephalus. *World Neurosurg* 2013;79 2 Suppl: S22.e1-7.
34. Kiefer M, Eymann R, Steudel WI. LOVA hydrocephalus – A new entity of chronic hydrocephalus. *Nervenarzt* 2002;73:972-81.
35. Kelly PJ. Stereotactic third ventriculostomy in patients with nontumoral adolescent/adult onset aqueductal stenosis and symptomatic hydrocephalus. *J Neurosurg* 1991;75:865-73.
36. Krauss JK, Regel JP, Vach W, Jüngling FD, Droste DW, Wakhloo AK. Flow void of cerebrospinal fluid in idiopathic normal pressure hydrocephalus of the elderly: Can it predict outcome after shunting? *Neurosurgery* 1997;40:67-73.
37. Lev S, Bhadelia RA, Estin D, Heilman CB, Wolpert SM. Functional analysis of third ventriculostomy patency with phase-contrast MRI velocity measurements. *Neuroradiology* 1997;39:175-9.
38. Matsuda M, Shibuya S, Oikawa T, Murakami K, Mochizuki H. A case of late-onset aqueductal membranous occlusion and a successful treatment with neuro-endoscopic surgery. *Rinsho Shinkeigaku* 2011;51:590-4.
39. McGirt MJ, Leveque JC, Wellons JC 3<sup>rd</sup>, Villavicencio AT, Hopkins JS, Fuchs HE, *et al.* Cerebrospinal fluid shunt survival and etiology of failures: A seven-year institutional experience. *Pediatr Neurosurg* 2002;36:248-55.
40. Meier U. Shunt operation versus endoscopic ventriculostomy in normal pressure hydrocephalus: Diagnostics and outcome. *Zentralbl Neurochir* 2003;64:19-23.
41. Meier U, Zeilinger FS, Kintzel D. Signs, symptoms and course of normal pressure hydrocephalus in comparison with cerebral atrophy. *Acta Neurochir (Wien)* 1999;141:1039-48.
42. Meier U, Zeilinger FS, Schönherr B. Endoscopic ventriculostomy versus shunt operation in normal pressure hydrocephalus: Diagnostics and indication. *Minim Invasive Neurosurg* 2000;43:87-90.
43. Mitchell P, Mathew B. Third ventriculostomy in normal pressure hydrocephalus. *Br J Neurosurg* 1999;13:382-5.
44. Oi S. Hydrocephalus chronology in adults: Confused state of the terminology. *Crit Rev Neurosurg* 1998;8:346-56.
45. Oi S, Shimoda M, Shibata M, Honda Y, Togo K, Shinoda M, *et al.* Pathophysiology of long-standing overt ventriculomegaly in adults. *J Neurosurg* 2000;92:933-40.
46. Oka K, Yamamoto M, Ikeda K, Tomonaga M. Flexible endoneurosurgical therapy for aqueductal stenosis. *Neurosurgery* 1993;33:236-42.
47. Piatt JH Jr., Carlson CV. A search for determinants of cerebrospinal fluid shunt survival: Retrospective analysis of a 14-year institutional experience. *Pediatr Neurosurg* 1993;19:233-41.
48. Pudenz RH, Foltz EL. Hydrocephalus: Overdrainage by ventricular shunts. A review and recommendations. *Surg Neurol* 1991;35:200-12.
49. Rekatte HL. Comments on the article by D. Greitz “Paradigm shift in hydrocephalus research in legacy of Dandy’s pioneering work: Rationale for third ventriculostomy in communicating hydrocephalus”. *Childs Nerv Syst* 2007;23:1227-8.
50. Santamarta D, Martin-Vallejo J, Diaz-Alvarez A, Maillou A. Changes in ventricular size after endoscopic third ventriculostomy. *Acta Neurochir (Wien)* 2008;150:119-27.
51. Schroth G, Klose U. Cerebrospinal fluid flow. III. Pathological cerebrospinal fluid pulsations. *Neuroradiology* 1992;35:16-24.
52. Teo C, Jones R. Management of hydrocephalus by endoscopic third ventriculostomy in patients with myelomeningocele. *Pediatr Neurosurg* 1996;25:57-63.
53. Teo C, Rahman S, Boop FA, Cherny B. Complications of endoscopic neurosurgery. *Childs Nerv Syst* 1996;12:248-53.
54. Tisell M, Edsbacke M, Stephensen H, Czosnyka M, Wikkelsø C. Elastance correlates with outcome after endoscopic third ventriculostomy in adults with hydrocephalus caused by primary aqueductal stenosis. *Neurosurgery* 2002;50:70-7.
55. Rekatte HL. Comments on the article by D. Greitz “Paradigm shift in hydrocephalus research in legacy of Dandy’s pioneering work: Rationale for third ventriculostomy in communicating hydrocephalus”. *Childs Nerv Syst* 2007;23:1227-8.
56. Rekatte HL. Longstanding overt ventriculomegaly in adults: Pitfalls in treatment with endoscopic third ventriculostomy. *Neurosurg Focus* 2007;22:E6.
57. Schroeder C, Fleck S, Gaab MR, Schweim KH, Schroeder HW. Why does endoscopic aqueductoplasty fail so frequently? Analysis of cerebrospinal fluid flow after endoscopic third ventriculostomy and aqueductoplasty using cine phase-contrast magnetic resonance imaging. *J Neurosurg* 2012;117:141-9.
58. Schroeder HW, Schweim C, Schweim KH, Gaab MR. Analysis of aqueductal cerebrospinal fluid flow after endoscopic aqueductoplasty by using cine phase-contrast magnetic resonance imaging. *J Neurosurg* 2000;93:237-44.
59. Torsnes L, Blåfjelldal V, Poulsen FR. Treatment and clinical outcome in patients with idiopathic normal pressure hydrocephalus – A systematic review. *Dan Med J* 2014;61:A4911.
60. Fukuhara T, Vorster SJ, Ruggieri P, Luciano MG. Third ventriculostomy patency: Comparison of findings at cine phase-contrast MR imaging and at direct exploration. *AJNR Am J Neuroradiol* 1999;20:1560-6.
61. Unal O, Kartum A, Avcu S, Etlik O, Arslan H, Bora A. Cine phase-contrast MRI evaluation of normal aqueductal cerebrospinal fluid flow according to sex and age. *Diagn Interv Radiol* 2009;15:227-31.
62. Virhammar J, Cesarini KG, Laurell K. The CSF tap test in normal pressure hydrocephalus: Evaluation time, reliability and the influence of pain. *Eur J Neurol* 2012;19:271-6.
63. Wagshul ME, McAllister JP, Rashid S, Li J, Egnor MR, Walker ML, *et al.* Ventricular dilation and elevated aqueductal pulsations in a new experimental model of communicating hydrocephalus. *Exp Neurol* 2009;218:33-40.
64. Yamamoto M, Oka K, Ikeda K, Tomonaga M. Percutaneous flexible neuroendoscopic ventriculostomy in patients with shunt malfunction as an alternative procedure to shunt revision. *Surg Neurol* 1994;42:218-23.