

# Patient Satisfaction with Implant Removal after Stabilization Using Percutaneous Pedicle Screws for Traumatic Thoracolumbar Fracture

## Abstract

**Context:** There are no reports of patient satisfaction with implant removal after stabilization using percutaneous pedicle screws (PPS) for traumatic thoracolumbar fracture (TTF). **Aims:** The aim of this study was to investigate patient satisfaction with implant removal after stabilization using PPS for TTF. **Settings and Design:** A retrospective study. **Subjects and Methods:** The present study included data from 24 patients who underwent posterior stabilization using PPS for single-level TTF following implant removal. The degree of patient satisfaction was evaluated using a questionnaire. We investigated residuary back pain, using the numerical rating scale (NRS) and Oswestry disability index (ODI), and types of occupation. Patients were divided into groups of those with residuary back pain (Group P) and those without (Group N). We evaluated local kyphosis and disc degeneration after implant removal. We investigated whether residuary back pain or types of occupation affect patient satisfaction. **Statistical Analysis Used:** All statistical analyses were conducted using IBM SPSS statistics. **Results:** Patients were “extremely satisfied” in 13 cases (54%), “moderately satisfied” in eight cases (33%), and “neither” in three cases (13%). No patients answered “moderately dissatisfied” or “extremely dissatisfied.” The mean scores on the NRS and ODI in Group P were  $1.8 \pm 0.9$  and  $13.2 \pm 9.3$ , respectively. Patient satisfaction, disc degeneration, and local kyphosis were not significantly different between Group P and Group N. Patient satisfaction was not significantly different between the hard and light workgroups. **Conclusions:** Patient satisfaction with implant removal was high regardless of whether persistent back pain existed and did not depend on the type of occupation.

**Keywords:** Implant removal, patient satisfaction, percutaneous pedicle screw, thoracolumbar fracture

**Takeshi Sasagawa,  
Yasutaka Takagi<sup>1</sup>,  
Hiroyuki Hayashi<sup>1</sup>,  
Kazuhiro Nanpo<sup>1</sup>**

*Department of Orthopedic Surgery, Toyama Prefectural Central Hospital, <sup>1</sup>Department of Orthopedic Surgery, Tonami General Hospital, Toyama, Japan*

## Introduction

A percutaneous approach using percutaneous pedicle screws (PPS) for traumatic thoracolumbar fracture (TTF) is less invasive compared with open surgery.<sup>[1]</sup> After bony fusion is achieved, implant removal after traditional open surgery remains optional because the benefit is controversial.<sup>[2-5]</sup> To date, there have been few reports of clinical outcomes of implant removal following surgery using PPS.<sup>[6,7]</sup> Furthermore, to our knowledge, there are no reports of patient satisfaction with implant removal after stabilization using PPS. Therefore, the aim of this study was to investigate patient satisfaction with implant removal after stabilization using PPS for TTF.

## Subjects and Methods

This study was approved by the medical ethics committee of our hospital. Informed consent to use all patient data was obtained from all patients. Patients who underwent posterior stabilization using PPS for single-level TTF without neurological deficit following implant removal after bony fusion was achieved were included in this study. Inclusion criteria included patients who were 20–65 years old on the day of injury and followed for 3 months to 5 years after implant removal. Exclusion criteria included surgery for multiple vertebral fractures, mental disease, an additional anterior approach surgery, and osteoporotic fracture. Implant removal was performed for all patients who signed an informed consent for implant removal surgery after bony fusion was achieved.

### Address for correspondence:

*Dr. Takeshi Sasagawa,  
2-2-78 Nishinagae,  
Toyama City, Toyama  
Prefecture, 930-8550, Japan.  
E-mail: sasagawawagasasa@  
yahoo.co.jp*

This is an open access journal, and articles are distributed under the terms of the Creative Commons Attribution-NonCommercial-ShareAlike 4.0 License, which allows others to remix, tweak, and build upon the work non-commercially, as long as appropriate credit is given and the new creations are licensed under the identical terms.

For reprints contact: WKHLRPMedknow\_reprints@wolterskluwer.com

**How to cite this article:** Sasagawa T, Takagi Y, Hayashi H, Nanpo K. Patient satisfaction with implant removal after stabilization using percutaneous pedicle screws for traumatic thoracolumbar fracture. *Asian J Neurosurg* 2021;16:765-9.

**Submitted:** 28-Dec-2020 **Revised:** 02-May-2021  
**Accepted:** 30-May-2021 **Published:** 18-Dec-2021

### Access this article online

**Website:** [www.asianjns.org](http://www.asianjns.org)

**DOI:** 10.4103/ajns.AJNS\_559\_20

### Quick Response Code:



The degree of patient satisfaction was evaluated using the following original questionnaire.

Q1: Please rate your satisfaction with implant removal.

The choices of answers are as follows: (1) Extremely satisfied, (2) moderately satisfied, (3) neither satisfied nor dissatisfied, (4) moderately dissatisfied, (5) extremely dissatisfied.

Q2: Please tell me the reason for the answer of Q1 (multiple answers allowed).

Q3: Would you recommend implant removal to someone? The choices of answers are as follows: (1) Strongly recommend, (2) moderately recommend, (3) neither, (4) moderately not recommend, (5) strongly not recommend.

We investigated residuary back pain, on a numerical rating scale (NRS) and Oswestry disability index (ODI). Residuary back pain was defined as persisting back pain which did not exist before injury. We evaluated local kyphosis and disc degeneration on lateral X-rays or in the sagittal plane from computed tomography after implant removal. We measured local kyphosis using the Cobb angle, from the superior endplate of the adjacent cranial vertebral body to the inferior endplate of the adjacent caudal body.<sup>[8]</sup> In this study, a degenerated disc was defined by the height of an injured disc that was 30% less than the average of both the adjacent cranial and caudal normal discs.<sup>[9]</sup> Patients were divided into groups of those with residuary back pain (Group P) and those without (Group N). Chi-square tests, Fisher's exact tests, and Mann-Whitney U tests were used to compare gender, age, level, satisfaction, disc degeneration, and local kyphosis between the two groups. Furthermore, we investigated whether types of occupation affect patient satisfaction with metal removal. Patients were divided into groups of hard work and light work. Chi-square tests, Fisher's exact tests, and Mann-Whitney U tests were used to compare gender, age, return to work, and satisfaction between the two groups. A  $P < 0.05$  was considered statistically significant. All statistical analyses were conducted using IBM SPSS Statistics for Windows version 22 (IBM Corp, Armonk, NY).

## Results

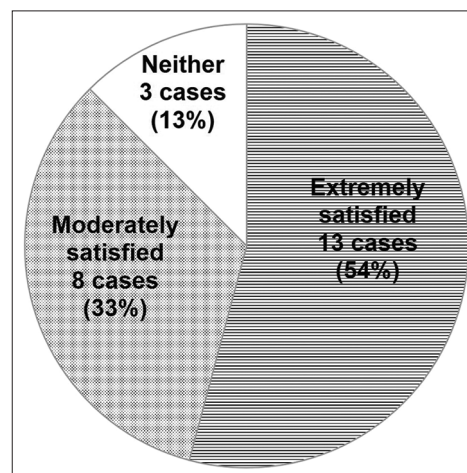
Twenty-five patients who meet inclusion and exclusion criteria were followed until bony fusion was achieved. Only one patient did not sign an informed consent for implant removal surgery. Therefore, twenty-four patients (20 men and 4 women) with a mean age of  $43.9 \pm 12.3$  years (range 25–64 years) were included in this study after implant removal. Fracture sites included T12 in 1 case (4%), L1 in twelve cases (50%), L2 in six cases (25%), L3 in two cases (8%), and L4 in three cases (13%). The mean time between primary surgery and implant removal surgery was  $14.4 \pm 4.9$  months (range 5–27 months). The mean follow-up duration after implant removal was  $29.1 \pm 17.3$  months (range 3–59 months).

The results from the questionnaire were:

**Table 1: Comparison between groups with (Group P) or without (Group N) pain following implant removal**

	Group N (n=12)	Group P (n=12)	P-value
Gender			
Male	11	9	NS*
Female	1	3	
Age (years)	42.6±11.0	45.3±13.3	NS*
Level	L1: 6 L2: 3 L3: 1 L4: 2	T12: 1 L1: 6 L2: 3 L3: 1 L4: 1	NS*
NRS	0	1.8±0.9	
ODI	0	13.2±9.3	
Satisfaction (Q1)	1:8 2:3 3:1 4:0 5:0	1:5 2:5 3:2 4:0 5:0	NS*
Disc degeneration			
Yes	7	9	NS*
No	5	3	
Local kyphosis (°)	7.3±9.2	11.8±9.5	NS*

\*NS ( $P > 0.05$ ). NRS – Numerical Rating Scale; ODI – Oswestry disability index



**Figure 1: Responses to Q1 related to patient satisfaction**

Q1: (1) Extremely satisfied in 13 cases (54%), (2) Moderately satisfied in eight cases (33%), (3) Neither in three cases (13%). No cases answered (4) moderately dissatisfied or (5) extremely dissatisfied [Figure 1].

Q2: In 21 patients who answered 1 (Extremely satisfied) or 2 (Moderately satisfied) on Q1, the reasons for satisfaction of implant removal were decreased back pain or discomfort in 12 cases, improvement of range of motion in four cases, and no complaint either before or after implant removal in six cases (multiple answers in one case). In all three cases who answered 3 (neither), residuary back pain or discomfort of the

back (pain in two cases, discomfort in one case) were given as the reason for the answer to Q1.

Q3: (1) Strongly recommend in 19 cases (79%), (2) moderately recommend in three cases (13%), (3) neither in two cases (8%). no cases answered (4) moderately not recommend or (5) Strongly not recommend [Figure 2].

There were 12 patients in Group P and 12 in Group N. The mean scores of NRS and ODI in Group P were  $1.8 \pm 0.9$  and  $13.2 \pm 9.3$ , respectively. In Group N, 11 of 12 cases (92%) answered extremely satisfied or moderately satisfied on Q1. In these 11 cases, the reasons for satisfaction with implant removal were decreased back pain or discomfort in four cases, improvement of range of motion in one case, and no complaint either before or after implant removal in six cases. In Group P, 10 of 12 cases (83%) answered extremely satisfied or moderately satisfied on Q1. In these 10 cases, the reasons for satisfaction with implant removal were decreased back pain or discomfort in eight cases, and improved range of motion in three cases (multiple answers in one case). There was no difference in gender, age, injured level, or satisfaction between the groups [Table 1]. Disc degeneration was more frequent and local kyphosis was greater in Group P, than in Group N, but there was no significant difference between the two groups ( $P = 0.33$ , and  $P = 0.18$ , respectively) [Table 1].

All 24 cases were employed before injury. There were 13 patients in hard workgroup and 11 in light workgroup. Eleven of 13 cases (85%) in the hard workgroup and 10 of 11 cases (91%) in the light workgroup answered extremely satisfied or moderately satisfied on Q1. There was no difference in gender, age, return to work, or satisfaction between the groups [Table 2].

### Discussion

The literature about implant removal after stabilization using PPS for TTF has reported only radiological or clinical outcomes,<sup>[6,7]</sup> but has not reported patient satisfaction. In this study, we investigated patient satisfaction with implant removal after stabilization using PPS for TTF. Patient satisfaction or pain is subjective evaluations. Patients with mental disease were excluded from this study because chronic back pain is related to psychosocial factors.<sup>[10]</sup> As a result, 87% of patients answered that they were “extremely satisfied” or “moderately satisfied” with implant removal. Thus, patient satisfaction with implant removal after stabilization using PPS for TTF was high. The most common reason for satisfaction with implant removal was decreased back pain or discomfort compared with the patient’s experience before implant removal. Previous studies reported that implant removal after traditional open surgery decreased back pain.<sup>[2-4]</sup> This study showed implant removal after stabilization using PPS also results in decreased back pain. Notably, even in the group of patients with residuary back pain, 10 of 12 patients were “extremely

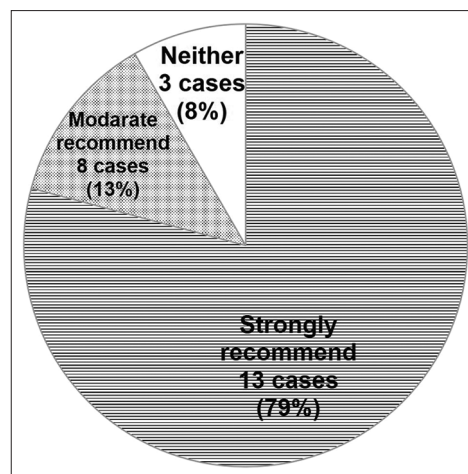


Figure 2: Responses to Q3 related to recommendations to others

Table 2: Comparison between types of occupation

Occupation	Hard work (n=13)	Light work (n=11)	P-value
Gender			
Male	12	9	NS*
Female	1	2	
Age	47.5±12.0	39.7±11.3	NS*
Return to work after injury			
Original occupation	8	10	NS*
Lighter duties	4	1	
No return to work	1	0	
Satisfaction (Q1)	1: 7 2: 4 3: 2 4: 0 5: 0	1: 6 2: 4 3: 1 4: 0 5: 0	NS*

\*NS ( $P > 0.05$ ).

satisfied” or “moderately satisfied” after implant removal. Furthermore, 8 of these 10 patients indicated that implant removal decreased back pain or discomfort compared with the pain they suffered before implant removal. The degree of residuary back pain in those patients was mild (NRS  $1.8 \pm 0.9$ , ODI  $13.2 \pm 9.3$ ) and likely limited activities of daily living minimally. Patient satisfaction with implant removal was high regardless of whether back pain was residual or not. The most common reason for satisfaction with implant removal other than decreased back pain or discomfort was improvement in the range of motion. Some previous studies reported that implant removal after traditional open surgery improved the range of motion.<sup>[11]</sup> This study showed that implant removal after stabilization using PPS also improves range of motion, increasing patient satisfaction.

One problem with implant removal is the recurrence of local kyphosis.<sup>[12-14]</sup> The percutaneous approach results in less frequent recurrence of local kyphosis after implant removal compared with open surgery.<sup>[1]</sup> Using magnetic

resonance imaging, in patients with thoracolumbar fracture, percutaneous instrumentation decreases muscle atrophy and fat infiltration not only at the fracture level but also at adjacent cranial and caudal levels compared with open surgery after implant removal.<sup>[15]</sup> In addition, the meta-analysis by Sun *et al.* reported that the correction loss using the percutaneous approach is smaller than that using the open approach, and concluded that the correction loss is mainly caused by muscle atrophy.<sup>[1]</sup> Whether local kyphosis is related to back pain or not is controversial.<sup>[16,17]</sup> The present study found that local kyphosis was greater in a group of patients with residuary back pain than in a group without residuary back pain, but there was no significant difference between the two groups. Although in both groups in this study local kyphosis recurred occurred as often as previously reported,<sup>[12-14]</sup> patient satisfaction with implant removal was high. The results of this study and past literature<sup>[3]</sup> suggest that implant removal decreases back pain or discomfort compared with the pain suffered before implant removal, regardless of surgical approach. It is likely that back pain or discomfort is not due to local kyphosis, but limitation of motion and/or foreign-body sensation of instrumentation.

There is a possibility that recurrence of local kyphosis after implant removal results in poor posture as well. However, no patient in this study was dissatisfied with the procedure due to poor posture. Previous studies reported that intervertebral disc degeneration due to injury is inevitable and occurs with high frequency.<sup>[18-21]</sup> Although disc degeneration occurred in 66% of patients in this study, patient satisfaction with implant removal was high. Thus, this study indicated that patient satisfaction with implant removal after stabilization using PPS for TTF was high regardless of whether local kyphosis recurred or disc degeneration occurred. The concept of stabilization using PPS for TTF is temporary fixation until bony fusion is achieved. Considering the concept of this operative procedure and the results of this study, implant removal is recommended. However, a previous study reported severe local kyphosis ( $>30^\circ$ ) after thoracolumbar fracture can result in impairment of activities of daily living.<sup>[13]</sup> Because patients with severe local kyphosis ( $>30^\circ$ ) were not included in this study, the results of this study of patient satisfaction may not apply to patients with severe local kyphosis. Patients in this study were younger,  $<65$  years old, consistent with previous studies.<sup>[2,4,5,12-14]</sup> Other studies that used an open approach and included older patients reported good patient satisfaction after implant removal.<sup>[3]</sup> The condition of the spine is different in younger and older patients. For example, the spine of older patients can be osteoporotic or may have deformity due to aging. On the other hand, younger age is a risk factor for the loss of correction.<sup>[12,14]</sup> Therefore, it is possible that patient satisfaction after implant removal is different in younger and older patients.

It has been thought that the occupation of the patient, the inherent load-bearing nature of the patient's job, and social factors play major roles in patient satisfaction after implant removal. However, there are no reports about the relationship between patient satisfaction after implant removal and types of occupation. Therefore, we investigated whether types of occupation affect patient satisfaction after implant removal. In this study patient satisfaction was high in both groups. There are no differences between the hard and light workgroups in gender, age, or return to work parameters.

There are some limitations to this study. In this study, almost all patients had implants removed after bony fusion was achieved. Thus, the selection bias is small. However, surgery is an invasive treatment. Therefore, to understand whether implant removal has merits that justify the surgical invasiveness, further studies comparing implant removal and retention are needed. In this study, there were no patients who were dissatisfied following implant removal. Therefore, we cannot consider risk factors of dissatisfaction after implant removal. Further study with a larger sample that includes dissatisfied patients is needed to investigate factors related to patient dissatisfaction. Furthermore, patients were followed only up to 5 years after implant removal to exclude potential effects of aging. Further study is necessary to understand the long-term results of patient satisfaction with implant removal after stabilization using PPS for TTF.

## Conclusion

Patient satisfaction with implant removal was high regardless of whether persistent back pain existed or the types of occupation.

## Financial support and sponsorship

Nil.

## Conflicts of interest

There are no conflicts of interest.

## References

1. Sun XY, Zhang XN, Hai Y. Percutaneous versus traditional and paraspinal posterior open approaches for treatment of thoracolumbar fractures without neurologic deficit: A meta-analysis. *Eur Spine J* 2017;26:1418-31.
2. Ko S, Jung S, Song S, Kim JY, Kwon J. Long-term follow-up results in patients with thoracolumbar unstable burst fracture treated with temporary posterior instrumentation without fusion and implant removal surgery: Follow-up results for at least 10 years. *Medicine (Baltimore)* 2020;99:e19780.
3. Smits AJ, den Ouden L, Jonkergouw A, Deunk J, Bloemers FW. Posterior implant removal in patients with thoracolumbar spine fractures: Long-term results. *Eur Spine J* 2017;26:1525-34.
4. Lee HD, Jeon CH, Chung NS, Seo YW. Cost-utility analysis of pedicle screw removal after successful posterior instrumented fusion in thoracolumbar burst fractures. *Spine (Phila Pa 1976)* 2017;42:E926-32.

5. Chou PH, Ma HL, Liu CL, Wang ST, Lee OK, Chang MC, *et al.* Is removal of the implants needed after fixation of burst fractures of the thoracolumbar and lumbar spine without fusion? A retrospective evaluation of radiological and functional outcomes. *Bone Joint J* 2016;98-B:109-16.
6. Oh HS, Seo HY. Percutaneous pedicle screw fixation in thoracolumbar fractures: Comparison of results according to implant removal time. *Clin Orthop Surg* 2019;11:291-6.
7. XIX CONGRESSO NAZIONALE S.I.C.O.O.P. SOCIETA' ITALIANA CHIRURGHI ORTOPEDICI DELL'OSPEDALITA' PRIVATA ACCREDITATA; Proietti L, Perna A, Schirò GR, Noia G, Fumo C, *et al.* Residual mobility after removal of instrumentation in patient, with type a2-a3 vertebral fractures, treated with percutaneous pedicle screw fixation. *J Biol Regul Homeost Agents* 2019;33:133-9.
8. Sadiqi S, Verlaan JJ, Lehr AM, Chapman JR, Dvorak MF, Kandziora F, *et al.* Measurement of kyphosis and vertebral body height loss in traumatic spine fractures: An international study. *Eur Spine J* 2017;26:1483-91.
9. Benneker LM, Heini PF, Anderson SE, Alini M, Ito K. Correlation of radiographic and MRI parameters to morphological and biochemical assessment of intervertebral disc degeneration. *Eur Spine J* 2005;14:27-35.
10. Ramond A, Bouton C, Richard I, Roquelaure Y, Baufreton C, Legrand E, *et al.* Psychosocial risk factors for chronic low back pain in primary care – A systematic review. *Fam Pract* 2011;28:12-21.
11. Axelsson P, Strömquist B. Can implant removal restore mobility after fracture of the thoracolumbar segment? *Acta Orthop* 2016;87:511-5.
12. Chen JX, Xu DL, Sheng SR, Goswami A, Xuan J, Jin HM, *et al.* Risk factors of kyphosis recurrence after implant removal in thoracolumbar burst fractures following posterior short-segment fixation. *Int Orthop* 2016;40:1253-60.
13. Aono H, Ishii K, Takenaka S, Tobimatsu H, Nagamoto Y, Horii C, *et al.* Risk factors for a kyphosis recurrence after short-segment temporary posterior fixation for thoracolumbar burst fractures. *J Clin Neurosci* 2019;66:138-43.
14. Hoppe S, Aghayev E, Ahmad S, Keel MJ, Ecker TM, Deml M, *et al.* Short posterior stabilization in combination with cement augmentation for the treatment of thoracolumbar fractures and the effects of implant removal. *Global Spine J* 2017;7:317-24.
15. Ntilikina Y, Bahlau D, Garnon J, Schuller S, Walter A, Schaeffer M, *et al.* Open versus percutaneous instrumentation in thoracolumbar fractures: Magnetic resonance imaging comparison of paravertebral muscles after implant removal. *J Neurosurg Spine* 2017;27:235-41.
16. Li S, Li Z, Hua W, Wang K, Li S, Zhang Y, *et al.* Clinical outcome and surgical strategies for late post-traumatic kyphosis after failed thoracolumbar fracture operation: Case report and literature review. *Medicine (Baltimore)* 2017;96:e8770.
17. Wood KB, Li W, Lebl DR, Ploumis A. Management of thoracolumbar spine fractures. *Spine J* 2014;14:145-64.
18. Fürderer S, Wenda K, Thiem N, Hachenberger R, Eysel P. Traumatic intervertebral disc lesion – Magnetic resonance imaging as a criterion for or against intervertebral fusion. *Eur Spine J* 2001;10:154-63.
19. Aono H, Ishii K, Tobimatsu H, Nagamoto Y, Takenaka S, Furuya M, *et al.* Temporary short-segment pedicle screw fixation for thoracolumbar burst fractures: Comparative study with or without vertebroplasty. *Spine J* 2017;17:1113-9.
20. Wang J, Zhou Y, Zhang ZF, Li CQ, Zheng WJ, Liu J. Radiological study on disc degeneration of thoracolumbar burst fractures treated by percutaneous pedicle screw fixation. *Eur Spine J* 2013;22:489-94.
21. Kerttula LI, Serlo WS, Tervonen OA, Pääkkö EL, Vanharanta HV. Post-traumatic findings of the spine after earlier vertebral fracture in young patients: Clinical and MRI study. *Spine (Phila Pa 1976)* 2000;25:1104-8.