

Horner's Syndrome due to Cervical Sympathetic Chain Schwannoma: A Rare Presentation and Review of Literature

Abstract

Cervical sympathetic chain schwannoma (CSCS) is an extremely rare benign tumor, and it is a diagnostic challenge. We report a case of 45-year-old female who presented with a solitary right cervical swelling with clinical features of Horner's syndrome (HS). She was evaluated with computed tomography, magnetic resonance imaging, and angiography. Surgical excision of the lesion was performed, and the histological examination revealed the diagnosis of schwannoma. Herein, we review the presentation, imaging characteristics, and operative considerations of a patient with a large CSCS, presenting with HS.

Keywords: Horner's syndrome, schwannoma, sympathetic chain

Harshad Patil, Shrikant Rege

Department of Neurosurgery, Sri Aurobindo Medical College and PG Institute, Indore, Madhya Pradesh, India

Introduction

Schwannomas, neurilemmomas, or neuroinomas are benign nerve sheath tumors derived from Schwann cells. The tumor arises from any peripheral, cranial, or autonomic nerves. The incidence of extracranial schwannomas that occur in the head-and-neck region is about 25%–45%.^[1]

Schwannomas, originating from the cervical sympathetic chain, are a rare subgroup of nerve sheath tumors, and fewer than 60 cases have been reported in the literature. The existence of Horner's syndrome (HS) before surgery is uncommon, and only 11 cases have been reported in the literature.^[2]

We report a huge cervical sympathetic chain schwannoma (CSCS), which is presented with HS. We review the presentation, imaging characteristics, and operative considerations.

Case Report

A 45-year-old female presented to our outpatient department with complaints of a painless right-sided neck mass with drooping of the right eyelid for the past 3 years and difficulty in swallowing for 1 year. On physical examination, a nonpulsatile, nontender mass was present just below the angle of mandible on the

right side of the neck. The patient had ptosis and enophthalmos in the right eye and right-sided miosis.

A magnetic resonance imaging (MRI) scan was obtained, which showed a large heterogeneously enhancing oval sharply margined soft-tissue lesion in the prevertebral region of the right side of the neck. The mass was causing marked indentation on nasopharynx and oropharynx measuring about 7.0 cm × 5.4 cm × 3.0 cm. It appeared heterogeneously hyperintense on T2-weighted (T2W) and hypointense on T1-weighted (T1W) MRI images. No intralesional hemorrhage was present. The mass was extending from 1.5 cm below the base of the skull up to 2 cm superior to carotid bifurcation. No intraspinal extension was present [Figure 1].

Computed tomography (CT) neck with angiography was performed to assess the vascular status of the tumor and its relation to major vessels. It revealed a well-circumscribed mass measuring about 7.0 cm × 5.4 cm × 3.0 cm displacing internal carotid artery (ICA) and internal jugular vein (IJV) anterolaterally with flakes of central calcification. The mass did not invade the vascular structures [Figures 2 and 3].

Based on clinical and radiological findings, diagnosis of CSCS or paraganglioma was made.

How to cite this article: Patil H, Rege S. Horner's syndrome due to cervical sympathetic chain schwannoma: A rare presentation and review of literature. *Asian J Neurosurg* 2019;14:1013-6.

This is an open access journal, and articles are distributed under the terms of the Creative Commons Attribution-NonCommercial-ShareAlike 4.0 License, which allows others to remix, tweak, and build upon the work non-commercially, as long as appropriate credit is given and the new creations are licensed under the identical terms.

For reprints contact: reprints@medknow.com

Address for correspondence:
Dr. Harshad Patil,
Department of Neurosurgery,
Sri Aurobindo Medical
College and PG Institute,
Indore - 452 010,
Madhya Pradesh, India.
E-mail: dr.harshadpatil@gmail.com

Access this article online

Website: www.asianjns.org

DOI: 10.4103/ajns.AJNS_58_18

Quick Response Code:



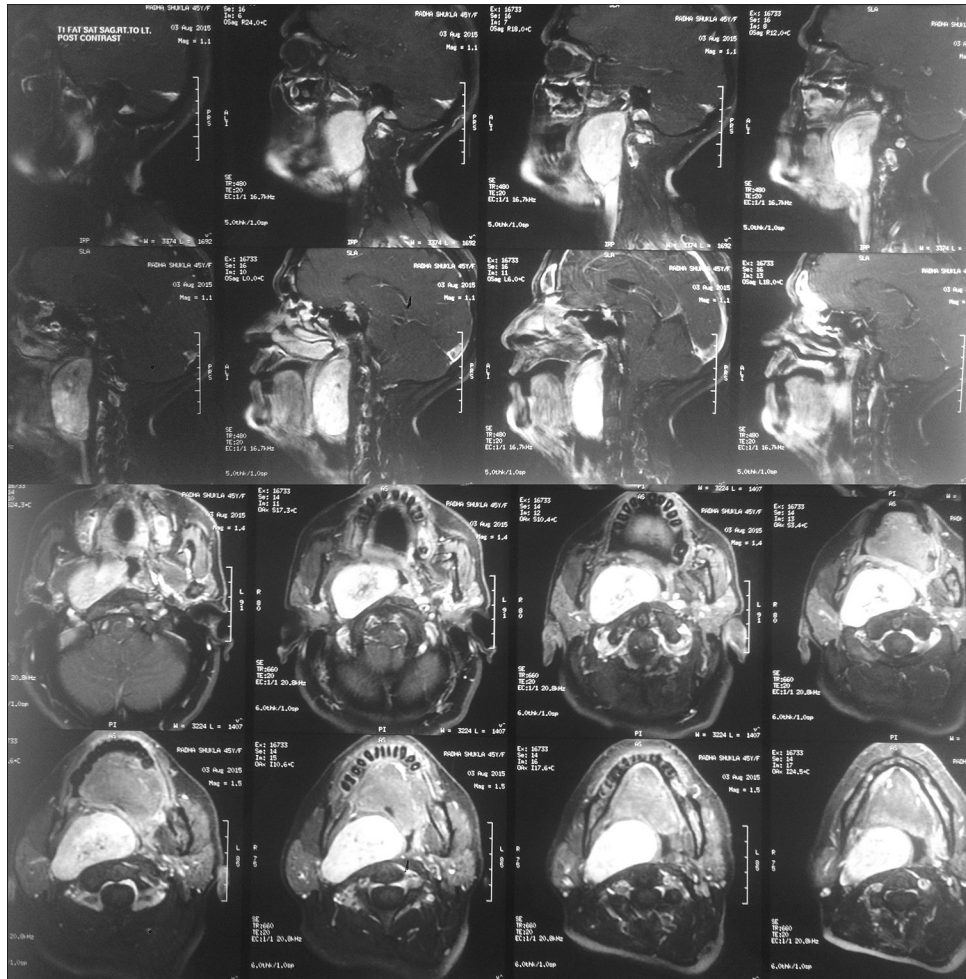


Figure 1: A large heterogeneously enhancing oval sharply marginated soft-tissue lesion in the prevertebral region of the right side of the neck

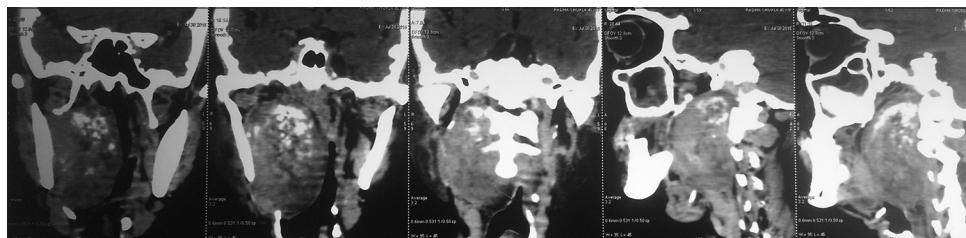


Figure 2: Computed tomography neck showing flakes of central calcification

In view of the symptoms, the patient was taken up for surgery. Transcervical approach was used to explore the mass. The main vascular structures, such as ICA, IJV, and the vagal and accessory nerves, were identified and dissected from the surface of the tumor. The IJV and ICA were displaced anterolaterally. A well-circumscribed oval mass was separated by blunt dissection and was found to be arising from a thin nerve branch of cervical sympathetic chain [Figure 4]. The mass could not be separated from cervical sympathetic chain and base of the skull. Tumor was excised piecemeal along with a part of the nerve [Figure 5]. The excised tissue was sent for histopathological examination and was reported to be a

benign schwannoma. After the surgery, her dysphagia was improved significantly, but signs of HS did not improve.

Discussion

Schwannoma was first described by Verocay in 1908. It is a slow-growing benign, encapsulated tumor arising from the nerve sheath of peripheral, motor, sensory, sympathetic, or cranial nerves within the head, neck, and upper and lower extremities.^[3] They are commonly benign tumors; however, malignant cases also have been reported. Cervical schwannomas typically present between the fourth and sixth decades of life, as in our case, but they may occur at any age.^[4]

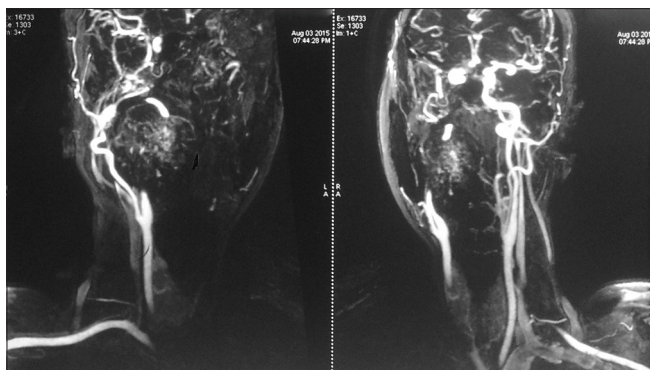


Figure 3: Computed tomography angiogram: Mass was not invading the vascular structures

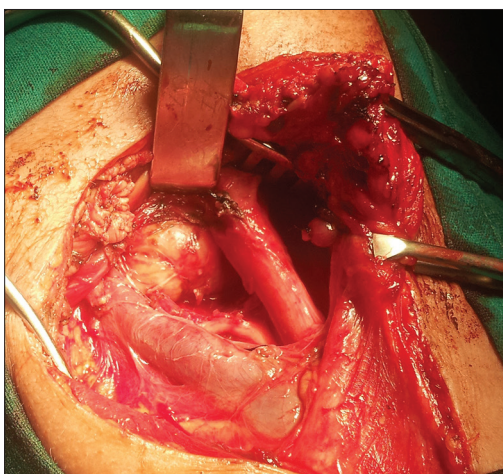


Figure 4: Intraoperative image showing a well-circumscribed oval mass arising from a thin nerve branch of cervical sympathetic chain and displacing the internal jugular vein and internal carotid artery anteriorly

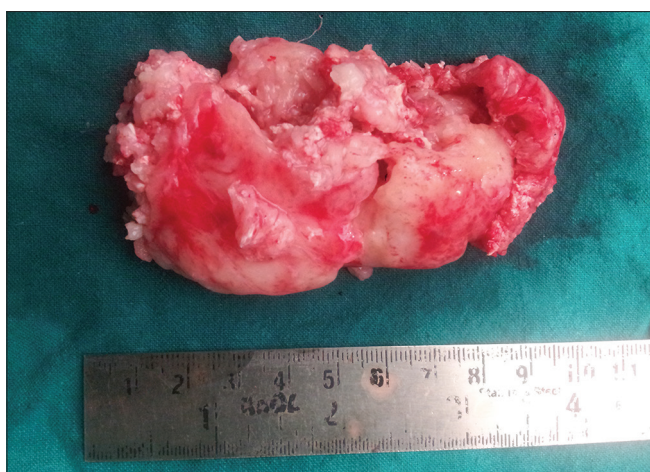

Figure 5: After piecemeal excision

In review of the literature, we encountered only 11 cases of CSCS with HS till date.^[2,4]

The presence of HS before excision is very unusual. HS may develop from lesions at any point along the sympathetic pathway. The classical features of HS are ptosis, anhidrosis, miosis, and enophthalmos, which are also present in our case.^[5]

CSCS usually presents as an asymptomatic, slow-growing neck mass. Other symptoms are dysphagia, change in voice, or cranial nerve deficit due to pressure or mass effect depending on the size of the mass. Pressure symptoms are rare because the structures in the neck are located in loose fascial compartment. In our case, the patient presented with dysphagia which is rare.^[2,5]

Schwannomas may be of variable size, from millimeters to centimeters, but they rarely reach enormous proportions, as in our case, with dimensions of 7.0 cm × 5.4 cm × 3.0 cm. Only one case of giant schwannoma was reported by Kahraman *et al.* in 2009.^[6]

Ultrasonography, CT, MRI, and angiography are useful tools for preoperative diagnosis of any cervical mass. The tumor grows posterior to the common carotid artery (CCA) and the ICA, and any increase in tumor size displaces the vessels anteriorly or laterally. This finding is characteristic for both vagal and cervical sympathetic chain tumors.^[5] This characteristic feature was noted in our case. The vagal schwannoma grows between the IJV and the CCA or the ICA, increasing the distance between the artery and vein. On the other hand, the cervical sympathetic chain schwannoma grows posterior to the CCA or the ICA and the IJV, and no separation can be observed between the IJV and the CCA or the ICA.^[6]

Schwannomas typically have well-delineated margins and commonly show higher attenuation than adjacent muscle on contrast-enhanced CT. They may also present as isodense or hypodense mass on CT scan. On MRI, schwannoma appears to have intermediate signal intensity on T1W images and high signal intensity on T2W images.^[7]

Angiography is an important tool in the evaluation of pulsatile neck mass. Splaying of the ICA and external carotid artery at the level of the bifurcation is called as “lyre sign,” which is a typical sign of carotid body tumors (CBTs); however, this is also found in CSCS.^[8]

Both CBTs and CSCS are neurogenic tumors that occupy the parapharyngeal space. It is difficult to differentiate a CSCS from a CBT preoperatively. The reported incidence of correct diagnoses is 25%–33% of schwannoma and 70% of paraganglioma cases.^[9] Pulsation or thrill is indicative of vascular lesions; however, sometimes, displacement of vascular structures by a nonvascular mass may also produce pulsation.^[10]

HS is rare in the preoperative period, but it is the most common complication postoperatively and is usually permanent. The treatment for CSCS is total excision of the lesion while keeping the nerve intact, if possible. Functional loss can be minimized by opening the capsule of the tumor (internal debulking or enucleation) and keeping the nerve bundles intact.^[11] Reconstruction of the nerve following excision of a schwannoma is recommended to restore nerve function. Since sacrifice of the cervical

sympathetic chain is well tolerated, reconstruction is not usually performed.^[12]

Conclusion

The possibility of a CSCS should be considered in the differential diagnosis while dealing with cervical masses. Among surgical techniques, intracapsular enucleation seems to give better results regarding the preservation of nerve function.

Declaration of patient consent

The authors certify that they have obtained all appropriate patient consent forms. In the form the patient(s) has/have given his/her/their consent for his/her/their images and other clinical information to be reported in the journal. The patients understand that their names and initials will not be published and due efforts will be made to conceal their identity, but anonymity cannot be guaranteed.

Financial support and sponsorship

Nil.

Conflicts of interest

There are no conflicts of interest.

References

1. Colreavy MP, Lacy PD, Hughes J, Bouchier-Hayes D, Brennan P, O'Dwyer AJ, *et al.* Head and neck schwannomas – A 10 year review. *J Laryngol Otol* 2000;114:119-24.
2. Bhagat S, Varshney S, Bist SS, Gupta N. Pediatric cervical sympathetic chain schwannoma with horner syndrome: A rare case presentation. *Ear Nose Throat J* 2014;93:E1-3.
3. Woodruff JM, Louis DN, Scheithauer BW. Schwannoma. Lyon, France: IARC Press; 2000.
4. Pesavento G, Ferlito A, Recher G. Benign solitary schwannoma of the cervical vagus nerve. A case report with a review of the literature. *J Laryngol Otol* 1979;93:307-16.
5. Som PM, Sacher M, Stollman AL, Biller HF, Lawson W. Common tumors of the parapharyngeal space: Refined imaging diagnosis. *Radiology* 1988;169:81-5.
6. Kahraman A, Yildirim I, Kiliç MA, Okur E, Demirpolat G. Horner's syndrome from giant schwannoma of the cervical sympathetic chain: Case report. *B-ENT* 2009;5:111-4.
7. Weissman JL. Nonnodal masses of the neck. In: Som PM, Curtin HD, editors. *Head and Neck Imaging*. 3rd ed. St. Louis, MO: Mosby-Year Book; 1996. p. 794-822.
8. Wang CP, Hsiao JK, Ko JY. Splaying of the carotid bifurcation caused by a cervical sympathetic chain schwannoma. *Ann Otol Rhinol Laryngol* 2004;113:696-9.
9. Benzoni E, Cojutti A, Intini S, Uzzau A, Bresadola F. Schwannoma of the sympathetic cervical chain presenting as a lateral cervical mass. *Tumori* 2003;89:211-2.
10. Aygenç E, Selçuk A, Özdem C. Hypervascular parapharyngeal schwannoma: An unusual case. *Auris Nasus Larynx* 2002;29:215-7.
11. Sheridan MF, Yim DW. Cervical sympathetic schwannoma: A case report and review of the English literature. *Otolaryngol Head Neck Surg* 1997;117:S206-10.
12. Moukarbel RV, Sabri AN. Current management of head and neck schwannomas. *Curr Opin Otolaryngol Head Neck Surg* 2005;13:117-22.