

Dissecting Aneurysm of Vertebral Artery Involving the Origin of Posterior Inferior Cerebellar Artery Treated with Retrograde Stent Placement and Coil Embolization in the Era of Flow Diverter

Abstract

Ruptured vertebral artery (VA) dissecting aneurysm carries high risk of rerupture and mortality if not treated immediately. Dissecting aneurysm of the VA involving the posterior inferior cerebellar artery (PICA) origin is difficult to treat by surgical and endovascular route. With the availability of flow diversion device for reconstructive procedure, endovascular treatment has now become easy to treat difficult aneurysm while maintaining the patency of the PICA. However, instead of using flow diverter (FD) in our case, we successfully treated dissecting VA aneurysm involving the PICA origin with retrograde stent placement from distal right VA to the left PICA to maintain the patency of PICA and occlusion of dissecting aneurysm of VA with detachable coils instead of performing surgical bypass and FD placement.

Keywords: Flow diverter, noncontrast computed tomography, parent vessel occlusion, posterior inferior cerebellar artery, stent, subarachnoid hemorrhage, vertebral artery

Introduction

Dissecting aneurysm of the intradural vertebral artery (VA) is uncommon cause of subarachnoid hemorrhage (SAH) which accounts for 3% of all intracranial aneurysms. It is associated with high risk of rerupture and high mortality if not secured immediately.^[1,2] Surgical treatment of these aneurysms can be curative treatment option which includes surgical trapping of dissected segment with or without extracranial–intracranial bypass; however, it has high risk of brainstem injury and lower cranial nerve palsies associated with surgery.^[3-5] Endovascular treatment is an alternate favorable option for treating the VA dissecting aneurysm which includes proximal occlusion, trapping of diseased segment, stent-supported coil embolization, flow diverter (FD), and overlapping stent reconstruction.^[1] With the advent of FD devices, it became possible to treat the complex dissecting aneurysm of vertebral artery.^[6] However, appropriate endovascular management option depends on the collateral status of opposite VA, posterior communicating arteries, and the involvement of PICA origin.^[7] We present

This is an open access journal, and articles are distributed under the terms of the Creative Commons Attribution-NonCommercial-ShareAlike 4.0 License, which allows others to remix, tweak, and build upon the work non-commercially, as long as appropriate credit is given and the new creations are licensed under the identical terms.

For reprints contact: reprints@medknow.com

a case of dissecting VA aneurysm involving the origin of PICA who was successfully treated with retrograde stent placement from distal right VA to the left PICA to maintain the patency of PICA and occlusion of dissecting aneurysm of VA with detachable coils instead of performing surgical bypass and FD placement.

Case Report

A 45-year-old female, known hypertensive, presented with history of drowsiness followed by loss of consciousness. Noncontrast computed tomography was done which showed acute SAH predominantly in perimedullary cistern [Figure 1a]. We performed cerebral angiography which revealed dissecting aneurysm of the V4 segment of the left VA extending to involve the PICA origin [Figure 1b and c]. Left PICA was dominant. Both the vertebral arteries were codominant. Option of FD placement and retrograde stent placement through the PICA with parent vessel occlusion (PVO) were discussed in view of dominant left PICA that could not be sacrificed. We loaded the patient with aspirin 300 mg and prasugrel 50 mg 3 h before the procedure.

How to cite this article: Mahajan A, Goel G, Das B, Narang KS. Dissecting aneurysm of vertebral artery involving the origin of posterior inferior cerebellar artery treated with retrograde stent placement and coil embolization in the era of flow diverter. *Asian J Neurosurg* 2018;13:910-3.

**Anshu Mahajan,
Gaurav Goel, Biplab
Das, Karanjit Singh
Narang**

Department of Neurosciences,
Medanta - The Medicity,
Gurgaon, Haryana, India

Address for correspondence:

Dr. Gaurav Goel,
Department of Neurosciences,
Medanta - The Medicity,
Gurgaon, Haryana, India.
E-mail: drgauravgoel1@gmail.
com

Access this article online

Website: www.asianjns.org

DOI: 10.4103/ajns.AJNS_59_18

Quick Response Code:



We used bilateral femoral route access. 6 F long sheath was advanced through right transfemoral route and then into the right subclavian artery over the 5 F diagnostic catheter. After that, DAC 057 (Concentric Medical) was parked in V2 segment of right VA through the long sheath. Prowler Select Plus microcatheter (Cordis Neurovascular, Miami Lakes, FL) was then navigated from the right VA into the left PICA using Synchro 14 microwire (Stryker Neurovascular, Fremont, CA, USA) for the stenting [Figure 1d]. We performed retrograde stenting from the right VA into the left PICA using Enterprise stent of size 4.5 mm × 22 mm (Cordis, Miami Lakes, Florida). 5 F short sheath was placed in left femoral artery. 5 F Envoy-guiding catheter (Cordis Neurovascular, Miami Lakes, FL) [Figure 1e] was then advanced through the left transfemoral route and was finally parked in left VA (V2 segment). Using Echelon microcatheter (eV3, Inc., Irvine, CA), the dissected segment of the left VA was occluded by coil embolization [Figure 1f]. Normal opacification of the left PICA is noted and is filling from the retrograde flow from right VA [Figure 1g]. There was no intraprocedural complication. The patient was discharged without significant neurological deficit. Check angiography after 6 months was done which showed completely occluded aneurysm with normal opacification of left PICA with stent *in situ* from left PICA to distal right VA [Figure 1h].

Discussion

Ruptured dissecting VA aneurysm requires immediate recognition, and treatment as it is associated with high mortality.^[1,2] The most common cause of dissecting VA aneurysm is idiopathic, the other causes including trauma, hypertension, fibromuscular dysplasia, polyarteritis nodosa, and syphilis have also been reported in the literature.^[6] The pathogenesis of VA dissection starts with the intimal tear and

then blood enters the media and tracks along the media to form intramural hematoma. Intramural hematoma may extend toward intima or adventitia. Arterial lumen stenosis is caused by subintimal dissection, and aneurysmal dilatation is caused by subadventitial dissection. Dissecting aneurysm of intradural segment of VA commonly presents as SAH due to presence of thin media and adventitia with fewer elastic fibers.^[7] Surgical treatment of dissecting aneurysm of VA includes surgical trapping of dissected segment with or without extracranial–intracranial bypass; however, it has high risk because of deep location of the aneurysm and its close proximity with the lower cranial nerves and brainstem structures.^[8] There are various endovascular treatment option for ruptured dissecting VA aneurysm which include proximal occlusion, trapping of diseased segment, stent-supported coil embolization, overlapping stent reconstruction, and FD placement. However, the selection of the appropriate treatment is decided by the collateral status of opposite VA and the involvement of PICA and anterior spinal artery (ASA) origin.^[6,7]

Treatment depending on the collateral status

If there is ruptured VA dissecting aneurysm with sufficient contralateral VA, PVO should be done. In case of ruptured aneurysm without sufficient contralateral VA, reconstruction procedure should be done with overlapping stent or FD. Coiling of these aneurysms has high risk of perforators infarct. Although PVO is considered as an effective treatment in most of the cases, it may also cause medullary and cerebellar infarction depending on the PICA origin status.^[9]

Treatment depending on the location of aneurysm with respect to posteroinferior cerebellar artery origin

If VA dissecting aneurysm is proximal to the PICA origin, PVO can be safely done. If aneurysm is distal to the PICA

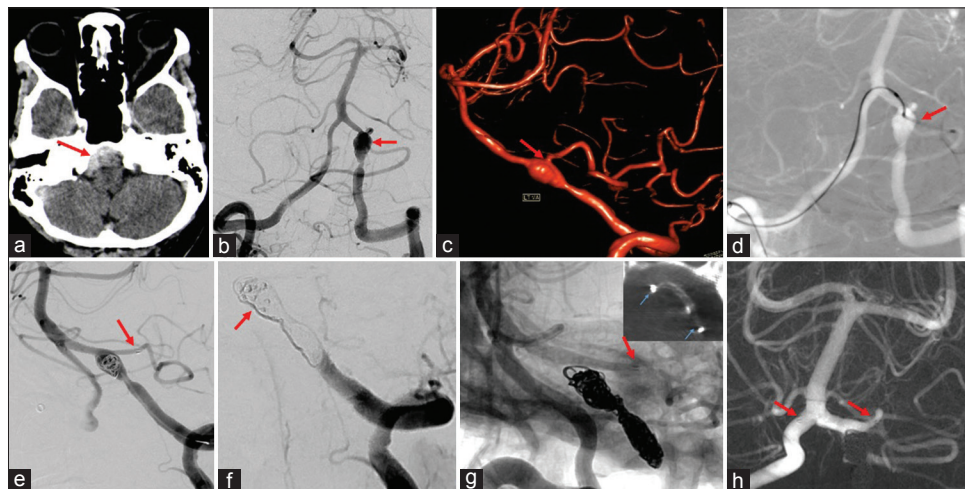


Figure 1: (a) Acute subarachnoid hemorrhage (arrow) on cranial computed tomography. (b and c) Two-dimensional and 3-dimensional rotational angiography respectively showed the vertebral artery dissecting aneurysm extending to the origin of left posteroinferior cerebellar artery (arrow). (d) Microcatheter placement into the left VA from the right VA (arrow). (e) Stent placed (arrow) into the left posteroinferior cerebellar artery. (f) Coil embolization of dissecting aneurysm. (g) Stent (arrow) in left posteroinferior cerebellar artery and well opened stent on Dyna computed tomography in image box. (h) Six-month follow-up angiography revealed occluded aneurysm with normal opacification of left posteroinferior cerebellar artery

origin, PVO of this segment may result in perforators' occlusion as this segment give rise to perforators more frequently. PVO is more effective in preventing the rebleed; however, it may cause lateral medullary syndrome and brainstem infarct. Thus, reconstruction therapy with stent alone, overlapping stent, or FD can be an alternate treatment option.^[7] If the PICA origin is involved in the dissecting segment of VA, endovascular reconstructive treatment is considered as an effective option which include single stent placement, overlapping stent placement, and stent placement into the PICA with PVO of the dissected vessel and FD placement. Reconstructive treatment is also required in patients having anatomic variations such as anterior inferior cerebellar artery origin in the VA and diseased contralateral VA.

Treatment depending on the location of aneurysm with respect to anterior spinal artery origin

ASA is also one of the most important factors in treating the dissecting VA aneurysm. ASA arises from the bilateral VA near the termination in 45.5%. Both ASA joins at a distance from the vertebrobasilar junction. It has multiple small perforating arteries which supply the anterior part of the medulla and anterior two-thirds of the cervical cord; thus, occlusion of the ASA while treating the VA dissecting aneurysm with PVO may lead to infarction of the medulla and cervical cord. There is also the presence of anastomosis among the perforators of basilar artery, VA, PICA, and ASA; thus, occlusion may not always lead to infarction. However, the presence of sufficient anastomosis enough to prevent ischemia cannot be evaluated. Therefore, in cases of VA dissecting aneurysm involving the ASA, proximal occlusion and reconstructive treatment methods are preferred to prevent the infarction of medulla and cord.^[10]

Zenteno *et al.* reported twenty patients with an aneurysm of the posterior circulation, out of which 7 were ruptured VA dissections.^[11] These were treated with the sole-stenting technique, and rebleeding was noted in none of the cases. Successful treatment with complete occlusion achieved with overlapping stent placement has been reported by some authors.^[12,13] Narata *et al.* and Cerejo *et al.* reported safety and good clinical outcome with FD treatment for dissecting aneurysm of VA.^[6,14] Single stent alone, overlapping stent and FD placement although effective treatment option however it does not immediately occlude the aneurysm thus not eliminating the risk of rerupture.^[1,7] Furthermore, they are complication reported by some authors including the device migration, immediate postoperative bleeding due to device stretching, and hemorrhagic complications related to dual antiplatelet therapy.^[15-17] The first case of stent from the distal VA to the PICA for a ruptured VA dissecting aneurysm involving the PICA origin was reported by Wu *et al.* with good midterm results.^[18] Chung *et al.* and Chen *et al.* reported successful VA to PICA stenting from ipsilateral side with VA occlusion of dissected segment to

preserve the patency of PICA in patient with dissecting VA aneurysm involving the PICA origin with one case failure reported by Chen *et al.* which was then treated with overlapping stent.^[19,20] In our case, the PICA origin was more toward the distal aspect of the dissected segment of VA, and angle between the left VA and PICA was acute to make catheterization of PICA from left VA difficult. Hence, we decided to performed retrograde stenting from right VA into the left PICA and occlusion of the dissected VA from the left side. Whatever approach is adopted by the endovascular surgeon, the main aim is to maintain the patency of the PICA and at the same time securing the rupture point by complete occlusion of the dissected segment of the VA.

Conclusions

Retrograde stent reconstruction of the PICA with PVO of dissected VA can be considered as a good alternative option to successfully treat the ruptured dissecting aneurysms of the VA involving the PICA origin and thus providing excellent remodeling of the PICA and complete occlusion of the aneurysm.

Declaration of patient consent

The authors certify that they have obtained all appropriate patient consent forms. In the form the patient(s) has/have given his/her/their consent for his/her/their images and other clinical information to be reported in the journal. The patients understand that their names and initials will not be published and due efforts will be made to conceal their identity, but anonymity cannot be guaranteed.

Financial support and sponsorship

Nil.

Conflicts of interest

There are no conflicts of interest.

References

- Madaelil TP, Wallace AN, Chatterjee AN, Zipfel GJ, Dacey RG Jr., Cross DT 3rd, *et al.* Endovascular parent vessel sacrifice in ruptured dissecting vertebral and posterior inferior cerebellar artery aneurysms: Clinical outcomes and review of the literature. *J Neurointerv Surg* 2016;8:796-801.
- Luo CB, Chang CY, Teng MM, Chang FC. Endovascular treatment of ruptured vertebral dissecting aneurysms with electrodetachable coils. *J Chin Med Assoc* 2005;68:578-84.
- Al-khayat H, Al-Khayat H, Beshay J, Manner D, White J. Vertebral artery-posterior inferior cerebellar artery aneurysms: Clinical and lower cranial nerve outcomes in 52 patients. *Neurosurgery* 2005;56:2-10.
- Starke RM, Ding D, Durst CR, Crowley RW, Liu KC. Combined microsurgical PICA-PICA bypass and endovascular parent artery occlusion for a ruptured dissecting vertebral artery aneurysm. *Neurosurg Focus* 2015;38 VideoSuppl 1:Video3.
- Park W, Ahn JS, Park JC, Kwun BD, Kim CJ. Occipital artery-posterior inferior cerebellar artery bypass for the treatment of aneurysms arising from the vertebral artery and its branches.

- World Neurosurg 2014;82:714-21.
6. Narata AP, Yilmaz H, Schaller K, Lovblad KO, Pereira VM. Flow-diverting stent for ruptured intracranial dissecting aneurysm of vertebral artery. *Neurosurgery* 2012;70:982-8.
 7. Lee JM, Kim TS, Joo SP, Yoon W, Choi HY. Endovascular treatment of ruptured dissecting vertebral artery aneurysms – Long-term follow-up results, benefits of early embolization, and predictors of outcome. *Acta Neurochir (Wien)* 2010;152:1455-65.
 8. Lv X, Jiang C, Li Y, Wu Z. Clinical outcomes of ruptured and unruptured vertebral artery-posterior inferior cerebellar artery complex dissecting aneurysms after endovascular embolization. *AJNR Am J Neuroradiol* 2010;31:1232-5.
 9. Guan J, Li G, Kong X, He C, Long J, Qin H, *et al.* Endovascular treatment for ruptured and unruptured vertebral artery dissecting aneurysms: A meta-analysis. *J Neurointerv Surg* 2017;9:558-63.
 10. Lim SH, Shin HS, Lee SH, Koh JS. Endovascular treatment of vertebral artery dissecting aneurysms that cause subarachnoid hemorrhage: Consideration of therapeutic approaches relevant to the angioarchitecture. *J Korean Neurosurg Soc* 2015;58:175-83.
 11. Zenteno MA, Santos-Franco JA, Freitas-Modenese JM, Gómez C, Murillo-Bonilla L, Aburto-Murrieta Y, *et al.* Use of the sole stenting technique for the management of aneurysms in the posterior circulation in a prospective series of 20 patients. *J Neurosurg* 2008;108:1104-18.
 12. Asai K, Nakamura H, Nishida T, Morris S, Sakaki T. Overlapping stent-assisted coil embolization for a ruptured intracranial vertebral artery dissection. *J Surg Case Rep* 2017;2017:rjx105.
 13. Benndorf G, Herbon U, Sollmann WP, Campi A. Treatment of a ruptured dissecting vertebral artery aneurysm with double stent placement: Case report. *AJNR Am J Neuroradiol* 2001;22:1844-8.
 14. Cerejo R, Bain M, Moore N, Hardman J, Bauer A, Hussain MS, *et al.* Flow diverter treatment of intracranial vertebral artery dissecting pseudoaneurysms. *J Neurointerv Surg* 2017;9:1064-8.
 15. Sönmez Ö, Brinjikji W, Murad MH, Lanzino G. Deconstructive and reconstructive techniques in treatment of vertebrobasilar dissecting aneurysms: A Systematic review and meta-analysis. *AJNR Am J Neuroradiol* 2015;36:1293-8.
 16. McTaggart RA, Santarelli JG, Marcellus ML, Steinberg GK, Dodd RL, Do HM, *et al.* Delayed retraction of the pipeline embolization device and corking failure: Pitfalls of pipeline embolization device placement in the setting of a ruptured aneurysm. *Neurosurgery* 2013;72 2 Suppl Operative: onsE245-50.
 17. Fox B, Humphries WE, Doss VT, Hoit D, Elijovich L, Arthur AS, *et al.* Rupture of giant vertebrobasilar aneurysm following flow diversion: Mechanical stretch as a potential mechanism for early aneurysm rupture. *BMJ Case Rep* 2014;2014. pii: bcr2014011325.
 18. Wu Z, Lv X, Yang X, He H. Ruptured vertebro-inferoposterior cerebellar artery dissecting aneurysm treated with the Neuroform stent deployment and vertebral artery occlusion. *Eur J Radiol Extra* 2009;70:e100-3.
 19. Chung J, Kim BS, Lee D, Kim TH, Shin YS. Vertebral artery occlusion with vertebral artery-to-posterior inferior cerebellar artery stenting for preservation of the PICA in treating ruptured vertebral artery dissection. *Acta Neurochir (Wien)* 2010;152:1489-92.
 20. Chen YA, Qu RB, Bian YS, Zhu W, Zhang KP, Pang Q, *et al.* Stent placement to treat ruptured vertebral dissecting aneurysms. *Interv Neuroradiol* 2013;19:479-82.