

Use of our Protocol of Multimodality Tools to Aid in the Safe Microsurgical Clipping of Unruptured Anterior Circulation Aneurysms

Abstract

Objectives: The aim of this study is to analyze the effectiveness of our protocol of the use of multimodality tools, namely indocyanine green-dual image video angiography, neuroendoscope, neuromonitoring with motor-evoked potential, micro-Doppler in the microsurgical clipping of unruptured anterior circulation aneurysms, operated at our institute from January 2016 to December 2018. **Materials and Methods:** We performed a retrospective analysis of all cases of unruptured anterior circulation aneurysms, operated at Fujita Health University Banbuntane-Hotokukai Hospital, Japan, from January 2016 to December 2018. We assessed outcome at immediate postoperative, at discharge, and at 3 months follow-up by defining permanent morbidity as drop in Modified Rankin Scale (MRS) by 1 at 3 months follow-up and transient morbidity as temporary deficit that improved at discharge or follow-up. Postoperative events, namely seizures, infection that did not affect/change. Preoperative MRS and discharge timing were excluded. We concluded poor outcome as MRS ≥ 3 and good outcome as MRS < 3 (0–2). All patients had a minimum of 3 months follow-up before outcome conclusion. **Results:** In 2016, a total of 98 cases were operated with no mortality or permanent morbidity (i.e., change in preoperative MRS), only transient morbidity was seen in (two cases) 2.04%. In 2017, a total of 119 cases were operated with no mortality or morbidity. In 2018, a total of 130 cases were operated with no mortality or permanent morbidity, only transient morbidity 0.7%. Summarizing from January 2016 to December 2018, a total of 347 cases of anterior circulation aneurysms were operated. Mostly, in the female sex (73.3%), the most common was middle cerebral artery aneurysm (39.1%). The mean size was 5.3 mm with no mortality or permanent morbidity with only transient morbidity in 0.9%. No poor outcome (MRS ≥ 3) was seen in our series. **Conclusion:** In our center for most unruptured anterior circulation aneurysms, microsurgical clipping is the treatment of choice. We believe our protocol of the intra-operative usage of multimodality tools have aided in the safe microsurgical clipping and have consistently resulted in good operative outcomes. Hence, we recommend and continue to use our Fujita-Bantane Protocol in all cases of micro-surgical clipping of aneurysms to consistently achieve good operative outcomes.

Keywords: Anterior circulation aneurysms, dual image video angiography, incidental aneurysms, indo-cyanine green, motor-evoked potentials, neuro-endoscope, neuro-monitoring, safe clipping, surgical outcome, unruptured aneurysms

Introduction

Advances in neuro-imaging and its widespread use for screening has led to an increase in the rate of diagnosis of un-ruptured intracranial aneurysms (UIAs) commonly known as Incidental Aneurysms. Although incidental cerebral aneurysms are common, the management is controversial.^[1,2] As reports from large-scale retrospective and prospective cohort studies have concluded that the risk of rupture associated with small UIAs is extremely low.^[2] These studies included data primarily from the Caucasian populations in North

America and Europe, but the incidence of rupture is higher in Japan and Finland than in other regions.^[3-5] This difference in the rupture risk might be induced by differences in racial or genetic backgrounds.^[5]

The overall prevalence of UIAs in the Japanese population was 3.2%. The prevalence in women was higher than that in men (4.4% vs. 2.5%). The prevalence increased with age in both genders.^[6] Although the prevalence of intracranial aneurysms is low, aneurysmal rupture causing subarachnoid hemorrhage (SAH) can be devastating, with morbidity and mortality rates around 25% and 40%,

This is an open access journal, and articles are distributed under the terms of the Creative Commons Attribution-NonCommercial-ShareAlike 4.0 License, which allows others to remix, tweak, and build upon the work non-commercially, as long as appropriate credit is given and the new creations are licensed under the identical terms.

For reprints contact: reprints@medknow.com

How to cite this article: Kannan S, Yamada Y, Miyatani K, Teranishi T, Marathi AR, Mohan K, et al. Use of our protocol of multimodality tools to aid in the safe microsurgical clipping of unruptured anterior circulation aneurysms. *Asian J Neurosurg* 2019;14:773-9.

Satish Kannan,
Yasuhiro Yamada¹,
Kyosuke Miyatani¹,
Takao Teranishi¹,
Arun Reddy
Marathi²,
Krishna Mohan³,
Tsukasa Kawase¹,
Yoko Kato¹

Department of Neurosurgery, Institute of Neurosciences and Spinal Disorders, MGM Health Care, Chennai, Tamil Nadu, ²Department of Neurosurgery, Prathima Hospitals, Hyderabad, Telangana, ³Department of Neurosurgery, KIMS, Nellore, Andhra Pradesh, India, ¹Department of Neurosurgery, Bantane Hospital, Fujita Health University, Nagoya, Japan

Address for correspondence:

Dr. Satish Kannan,
Institute of Neurosciences
and Spinal Disorders,
MGM Health Care,
Chennai, Tamil Nadu, India.
E-mail: satishkannan2483@
gmail.com

Access this article online

Website: www.asianjns.org

DOI: 10.4103/ajns.AJNS_65_19

Quick Response Code:



respectively.^[3,4,7] The Un-ruptured Cerebral Aneurysm Study (UCAS) showed that the natural course of unruptured cerebral aneurysms varies according to the size, location, and shape of the aneurysm. The risk for rupture was significantly higher for aneurysms that were 7 mm or larger, aneurysms of the anterior communicating artery (A-Com A) and the internal carotid (IC)-posterior communicating artery (P-ComA), aneurysms with a daughter sac as independent factors.^[8] The International Study of UIAs trial and the UCAS stratified the risk of rupture for UIAs according to aneurysm size, with higher risk for aneurysms that were 7 mm or larger.

In this study, we analyze the effectiveness of our protocol of the usage of multimodality tools, namely indo-cyanine green-dual image video angiography (ICG-DIVA), neuroendoscope, neuromonitoring (motor-evoked potential [MEP]), micro-Doppler in the safe micro-surgical clipping of anterior circulation aneurysms, performed at our institute from 2016 to 2018.

Materials and Methods

We performed a retrospective analysis of all cases of unruptured anterior circulation aneurysms operated at Fujita Health University Banbuntane-Hotokukai Hospital, Japan, from January 2016 to December 2018 [Table 1]. Along with the UCAS recommendations, cases that showed aneurysmal growth on serial imaging was taken up for surgical treatment.

Preoperative imaging included two-dimensional and three-dimensional (3D) computed tomography angiography, computational fluid dynamics study demonstrating wall pressure, wall shear stress suggesting impending rupture. Magnetic resonance imaging & 3D digital subtraction angiography if indicated. We classified Permanent Morbidity as drop in Modified Rankin Scale (MRS) by 1 at 3 months follow-up and Transient Morbidity-as temporary deficit that improved at discharge or follow-up. Postoperative events, namely seizures, infection that did not affect/change discharge timing were excluded. We concluded poor outcome as MRS ≥ 3 , good outcome as MRS < 3 (0–2). In our hospital, all neurovascular surgeries are performed with OPMI Pentero Microscope (Carl Zeiss, Oberkochen, Germany) with infrared 800 camera for ICG-VA. The MINIRC-2000K (Mizuho Co., Ltd., Nagoya, Japan) NIR camera mounted on the microscope for DIVA. Right angled rigid endoscope (Machida, Japan) for endoscopic evaluation. Micro-Doppler ultrasound (DVM 4300, Hadeco, Japan). All surgeries were performed under general anesthesia for induction, followed by propofol sedation. No muscle relaxant agents were used after induction to facilitate MEP monitoring.

Intra-operative protocol as depicted in Flowchart 1.

Data analysis

In 2016, a total of 98 cases of anterior circulation aneurysms were operated with majority being females (72.4%). Most common was middle cerebral artery (MCA) aneurysm 41.8%, followed by IC-P-Com aneurysm. Mean size was 4.8 mm with no mortality or permanent morbidity, only transient morbidity was seen in (2 cases) 2.04% [Table 2].

In 2017, a total of 119 cases of anterior circulation aneurysms were operated with majority being females (73.1%). Most common was MCA aneurysm 41.1%, followed by IC-P-Com aneurysm. Mean size was 6 mm approximately with no mortality or morbidity [Table 2].

In 2018, a total of 130 cases of anterior circulation aneurysms were operated with majority being females (74.6%). The most common was MCA aneurysm 34.6%, followed by A-Com aneurysm. The mean size was 5.1 mm approximately with no mortality or permanent morbidity, only transient morbidity 0.7% [Table 2].

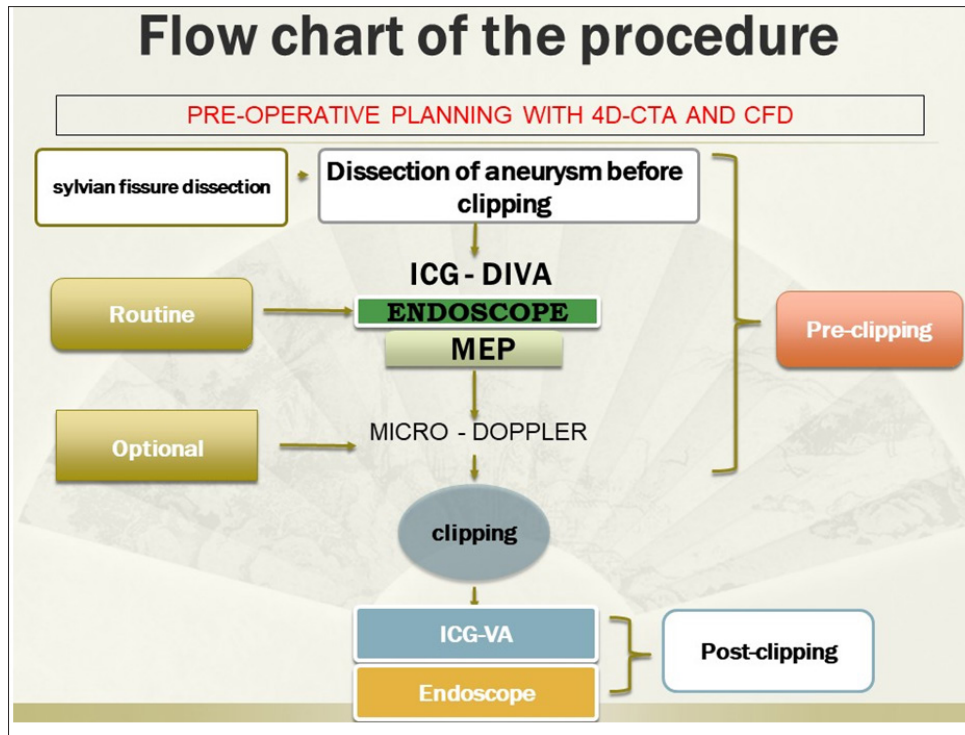
Results

Summarizing from January 2016 to December 2018, a total of 347 cases of anterior circulation aneurysms were operated with majority being females (73.3%), most common was MCA aneurysm 39.1%. The mean size was 5.3 mm with no mortality or permanent morbidity, and transient morbidity in 0.9%. No poor outcome (MRS ≥ 3) was seen in our series [Table 3].

During the initial part of the study, MEP monitoring was done on a selective basis mostly for MCA, IC-P-Com, IC-Acho aneurysms, etc. AS the protocol evolved, we have used it for almost all the cases as mentioned above. Now it has become a routine for all cases. Suture removal was done on the 7th postoperative day, the average in-hospital stay was 12–14 days.

Discussion

Although the estimated 3% prevalence of intracranial aneurysms is low, aneurysm rupture causing SAH can be devastating, with morbidity and mortality rates around 25% and 40%, respectively.^[3,6,7] Despite recent improvements in surgical and medical management of aneurysmal SAH, the overall mortality rate produced by this disease is still high (approximately 40%–50%). The high mortality and morbidity rates are attributed mainly to brain damage caused by a severe initial hemorrhage, early re-bleeding, and delayed cerebral ischemia related to vasospasm.^[9,10] During the last two decades, detection of UIAs has increased because of new and improving diagnostic technology and its routine and increased use in screening. The overall prevalence of UIAs in the Japanese population was 3.2%. The prevalence in women was



Flowchart 1: Fujita-Bantane Protocol

higher than that in men (4.4% vs. 2.5%). Female sex is an independent risk factor for the growth of UIAs in elderly patients.^[6,11,12] The prevalence increased with age in both genders.^[11-13] The size is considered to be an independent risk factor.^[1,2,7,8,12-14] The management of unruptured aneurysms is controversial, currently there are no randomized controlled trials to decide on the management of UIAs. The PHASES score and the UIA treatment score (UIATS) score are currently used in decision making. The PHASES score is a 5-year rupture rate estimation model based on 8283 patients diagnosed with UIAs and 29166 patient years of follow-up and the UIATS score is a consensus-based scoring system.^[15,16] Neither scoring system has been satisfactorily validated on an independent large cohort and there is a conflicting reports about such scoring systems leading to over treatment and questions about their reliability on stable UIAs, growing UIAs.^[17,18]

Hence, the management of UIAs should take into consideration patient characteristics such as age, sex, ethnic background, comorbidities and aneurysm characteristics such as size, shape, location, and aspect ratio.^[3-5,7,11-13,15-20] The management of aneurysms at high volume centers by experienced neurosurgical and endovascular teams has excellent results, most experts agree that micro-surgical clipping should be the first line of treatment.^[7,21]

In our center, micro-surgical clipping is the first line of treatment for most unruptured anterior circulation aneurysms. We have been using the Fujita-Bantane Protocol (FB Protocol) in all our cases. After sylvian dissection and exposure of the aneurysm.

Step 1 involves preclipping ICG-DIVA. Although standard ICG-VA (ICG alone) clearly highlights vascular structures from nonvascular structures as white and black images respectively, other structures cannot be observed.^[22-26] ICG-DIVA provides real-time simultaneous visualization of the aneurysm, vessels and surrounding structures including brain, nerves with far better depth perception thereby facilitating better anatomical correlation. This helps in quicker and more effective decision making during surgery.^[27,28] DIVA images giving better anatomical correlation clearly depicted here in Figure 1.

Step 2 involves preclipping neuro-endoscopic evaluation. The neuro-endoscope, with its better illumination, higher magnification, extended viewing angles can provide real-time assessment about the hidden perforators, key neurovascular structures which are not visible under the dead angles of the microscope.^[29-32] Additional technological advancements have made the neuro-endoscope not only as an diagnostic tool but also capable of assisting angiographic evaluation and guiding clipping procedure as shown in Figure 2.^[33-37]

The Step 1 and Step 2 are repeated as per requirements. Continuous transcranial MEP monitoring is done during the procedure; initially, MEP monitoring was done on a case-to-case basis. Now has become a routine in all cases. Direct (cortical) MEP is sensitive in detecting ischemic stress to descending motor pathways during aneurysm surgery. Recently, increased use of combined trans-cranial and direct MEP monitoring is being practiced with better sensitivity and specificity as a part of multimodality monitoring during

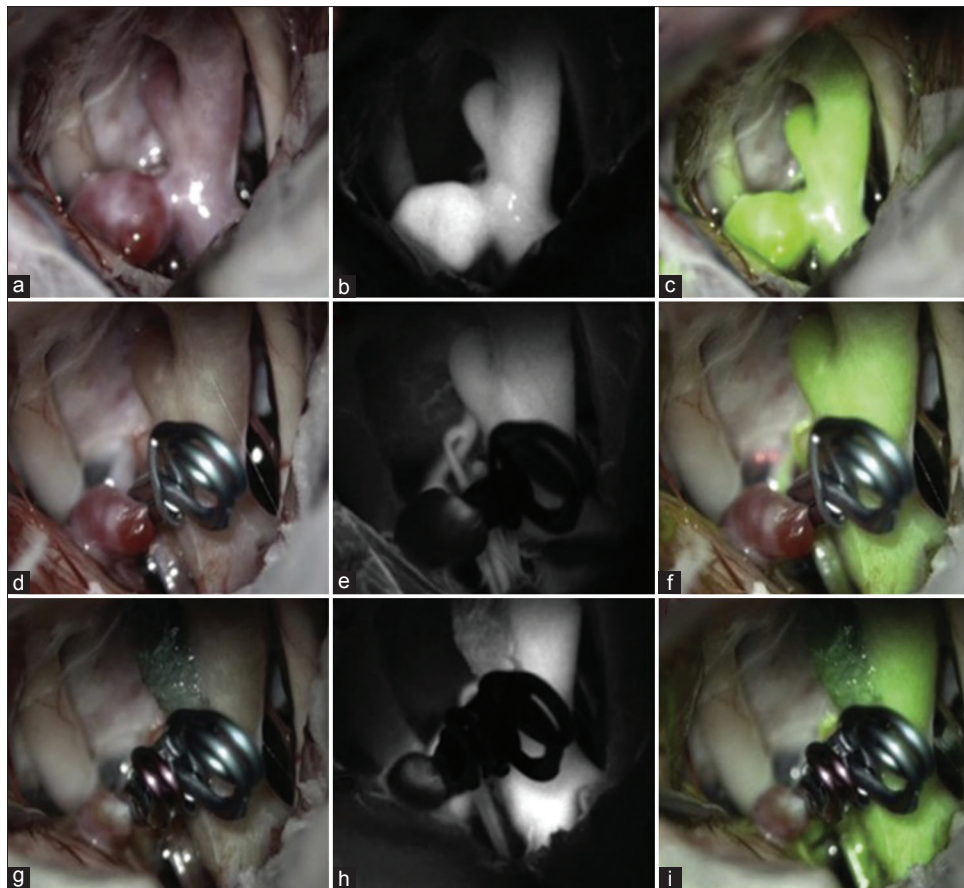


Figure 1: Illustrative case of internal carotid artery aneurysm with (a-c) depicting pre-clipping microscopic, indo-cyanine green, dual image video angiography images respectively. (d-f) Depicting post clipping microscopic, indo-cyanine green, dual image video angiography images respectively. Dual image video angiography images giving better anatomical correlation clearly depicted here. (g-i) Depicting post 2nd-clipping microscopic, indo-cyanine green, dual image video angiography images respectively

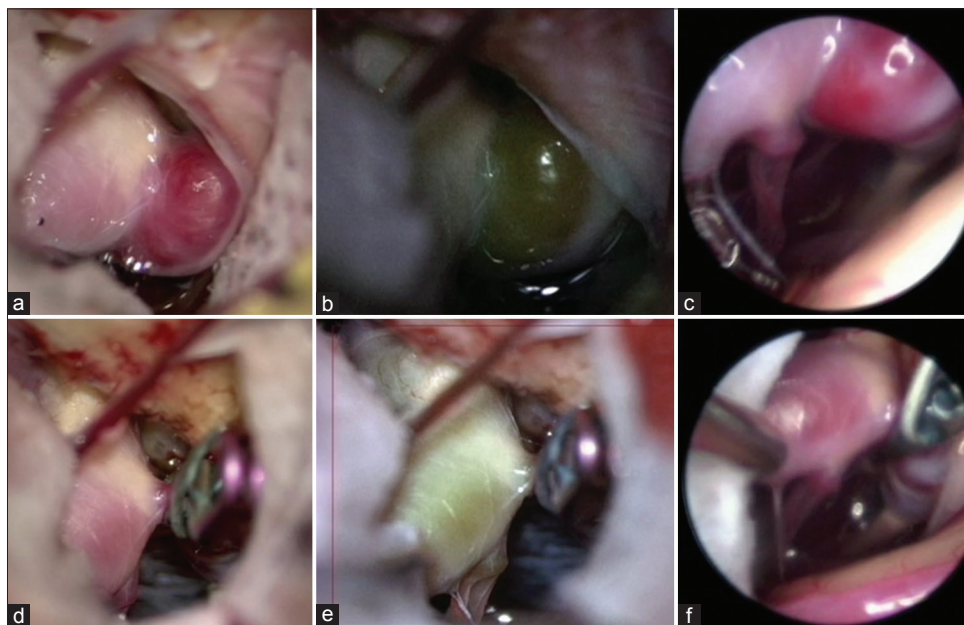


Figure 2: Illustrative case of internal carotid-posterior communicating aneurysm (a and b) depicting preclipping microscopic, dual image video angiography images respectively. (c) Is endoscopic view depicting posterior communicating and perforators, not seen in microscopic view. (d and e) Depicting post-clipping microscopic, dual image video angiography images respectively. (f) Is endoscopic view showing posterior communicating preserved and complete obliteration of the aneurysm

Table 1: Demographic data

Years	Aneurysm								
	ACOM	A2-3/DACA	MCA	IC-PC	IC-OPH	IC-ACHO	IC-TOP	IC-CAVERNOUS	C2-C3
2016	14	3	41	17		8	3		12
2017	20	8	49	22	13	5	2		
2018	24	7	45	22	22	7	2	1	
Total	58	18	135	61	35	20	7	1	12

ACOM – Anterior communicating artery aneurysm; A2-3/DACA – Distal Anterior Cerebral Artery aneurysm; MCA – Middle cerebral artery aneurysm; IC-PC – Internal cerebral artery - posterior communicating artery aneurysm; IC-OPH – Internal cerebral artery - ophthalmic artery aneurysm; IC-ACHO – Internal cerebral artery – anterior choroidal artery aneurysm; IC-TOP – Internal cerebral artery - bifurcation aneurysm; IC-CAVERNOUS – Internal cerebral artery - cavernous segment aneurysm; C2-C3 – Ophthalmic-clinoidal segment

Table 2: Year wise data

Type of aneurysm	Total number	Male	Female	Size (mm) R; M	MEP	Morbidity
2016						
ACOM	14	8	6	2.5-12; 4.5	2	Seizures - 1 case
A2-3/DACA	3	-	3	4-6; 4.7		
MCA	41	10	31	2-9; 4.7	13	Drop in MEP in 1 case - no symptoms
IC-PC	17	6	11	3-10; 4.4	11	Drop in MEP in 1 case-transient hemiparesis transient 3 rd nerve palsy - 1 case
IC-ACHO	8	1	7	3-8; 5	6	
IC-TOP	3		3	4-8; 5.7	3	
C2-C3	12	2	10	3-7; 4.8	2	
Total	98	27	71	4.8		
2017						
ACOM	20	8	12	3-20; 7.8	5	
A2-3/DACA	8	2	6	3-15; 7.3	1	
MCA	49	16	33	3-20; 5.9	24	
IC-PC	22	3	19	2.5-20; 6.6	16	
IC-OPH	13	1	12	2-7; 4.4	2	
IC-ACHO	5	-	5	3-10; 5.2	1	
IC-TOP	2	2	-	3-6; 4.5	1	
Total	119	32	87	6		
2018						
ACOM	24	8	16	2-10; 4.6	23	Seizures - 1
A2-3/DACA	7	4	3	3-6; 4.7	4	
MCA	45	13	32	1.5-10; 5	42	Seizures - 2
IC-PC	22	6	16	2-14; 4.8	17	
IC-OPH	22	-	22	2.5-15; 5.7	14	
IC-ACHO	7	2	5	2-6; 4.1	7	
IC-TOP	2	-	2	3-10; 6.5	2	Transient aphasia - 1
IC-CAVERNOUS	1	-	1			
Total	130	33	97	5.1		

ACOM – Anterior communicating artery aneurysm; A2-3/DACA – Distal Anterior Cerebral Artery aneurysm; MCA – Middle cerebral artery aneurysm; IC-PC – Internal cerebral artery - posterior communicating artery aneurysm; IC-ACHO – Internal cerebral artery - anterior choroidal artery aneurysm; IC-TOP – Internal cerebral artery - bifurcation aneurysm; C2-C3 – Ophthalmic-clinoidal segment; MEP – Motor-evoked potential; IC-OPH – Internal cerebral artery - ophthalmic artery aneurysm; IC-CAVERNOUS – Internal cerebral artery - cavernous segment aneurysm

Table 3: Year wise summary

Years	Number of cases	Transient morbidity (%)	Permanent morbidity	Mortality
2016	98	2.04	Nil	Nil
2017	119	Nil	Nil	Nil
2018	130	0.7	Nil	Nil
Total	347	0.9	0 (nil)	0 (nil)

aneurysm surgery.^[38-41] Micro-Doppler is used as an optional modality on a case-to-case basis, if additional information is required about the patency of the parent vessel or perforators.

The goal of aneurysm surgery is to achieve satisfactory clipping such that there is no residual filling of the aneurysm, distal branch and perforator occlusion, or parent vessel stenosis. As aneurysm remnants have potential for re-growth

and hemorrhage, whereas clip occlusion of a parent artery or small hidden perforators can lead to permanent neurological deficits and is a devastating complication. Thus, preserving blood flow in the branches and perforators of a parent artery is very important for successful surgery.^[42]

We believe our protocol, which has evolved over a short period of time provides all the vital information to the operating surgeon, thereby aiding in quicker and better decision making to make microsurgical clipping safe. Thus, consistently resulting in satisfactory operative outcomes and achieving the goal of aneurysm surgery.

Conclusion

In the current era of neuro-vascular surgery, most randomized controlled trials are nearing a consensus that both open micro surgical clipping and endovascular treatment are equally efficient and viable treatment options in experienced hands.^[43,44] Although open micro surgical clipping is the gold standard treatment in terms of aneurysm obliteration rates and rebleeding rates, it is being constantly challenged by recent technological advancements and continuously evolving endovascular treatment modalities.^[45-49] Most experts agree that management of aneurysms done at high volume centers by experienced neurosurgical and endovascular teams has excellent results. In most centers micro-surgical clipping is the first line of treatment for unruptured aneurysms.^[50,51]

In our center for most unruptured anterior circulation aneurysms micro-surgical clipping is the treatment of choice. We believe our protocol of the intra-operative usage of multimodality tools have aided in the safe micro-surgical clipping and have consistently resulted in good operative outcomes. Hence, we recommend and continue to use our FB Protocol in all cases of micro-surgical clipping of aneurysms to consistently achieve good operative outcomes.

Financial support and sponsorship

Nil.

Conflicts of interest

There are no conflicts of interest.

References

1. International Study of Unruptured Intracranial Aneurysms Investigators. Unruptured intracranial aneurysms – Risk of rupture and risks of surgical intervention. *N Engl J Med* 1998;339:1725-33.
2. Wiebers DO, Whisnant JP, Huston J 3rd, Meissner I, Brown RD Jr., Piepgras DG, *et al.* Unruptured intracranial aneurysms: Natural history, clinical outcome, and risks of surgical and endovascular treatment. *Lancet* 2003;362:103-10.
3. Vlak MH, Algra A, Brandenburg R, Rinkel GJ. Prevalence of unruptured intracranial aneurysms, with emphasis on sex, age, comorbidity, country, and time period: A systematic review and meta-analysis. *Lancet Neurol* 2011;10:626-36.
4. Bederson JB, Awad IA, Wiebers DO, Piepgras D, Haley EC Jr.,

- Brott T, *et al.* Recommendations for the management of patients with unruptured intracranial aneurysms: A statement for healthcare professionals from the stroke council of the American Heart Association. *Stroke* 2000;31:2742-50.
5. Morita A, Fujiwara S, Hashi K, Ohtsu H, Kirino T. Risk of rupture associated with intact cerebral aneurysms in the Japanese population: A systematic review of the literature from Japan. *J Neurosurg* 2005;102:601-6.
6. Harada K, Fukuyama K, Shirouzu T, Ichinose M, Fujimura H, Kakumoto K, *et al.* Prevalence of unruptured intracranial aneurysms in healthy asymptomatic Japanese adults: Differences in gender and age. *Acta Neurochir (Wien)* 2013;155:2037-43.
7. Burkhardt JK, Benet A, Lawton MT. Management of small incidental intracranial aneurysms. *Neurosurg Clin N Am* 2017;28:389-96.
8. UCAS Japan Investigators, Morita A, Kirino T, Hashi K, Aoki N, Fukuhara S, *et al.* The natural course of unruptured cerebral aneurysms in a Japanese cohort. *N Engl J Med* 2012;366:2474-82.
9. Broderick JP, Brott TG, Duldner JE, Tomsick T, Leach A. Initial and recurrent bleeding are the major causes of death following subarachnoid hemorrhage. *Stroke* 1994;25:1342-7.
10. Fogelholm R, Hernesniemi J, Vapalahti M. Impact of early surgery on outcome after aneurysmal subarachnoid hemorrhage. A population-based study. *Stroke* 1993;24:1649-54.
11. Kubo Y, Koji T, Kashimura H, Otawara Y, Ogawa A, Ogasawara K. Female sex as a risk factor for the growth of asymptomatic unruptured cerebral saccular aneurysms in elderly patients. *J Neurosurg* 2014;121:599-604.
12. Wermer MJ, van der Schaaf IC, Algra A, Rinkel GJ. Risk of rupture of unruptured intracranial aneurysms in relation to patient and aneurysm characteristics: An updated meta-analysis. *Stroke* 2007;38:1404-10.
13. Juvela S, Porras M, Poussa K. Natural history of unruptured intracranial aneurysms: Probability of and risk factors for aneurysm rupture. *J Neurosurg* 2000;93:379-87.
14. Ishibashi T, Murayama Y, Urashima M, Saguchi T, Ebara M, Arakawa H, *et al.* Unruptured intracranial aneurysms: Incidence of rupture and risk factors. *Stroke* 2009;40:313-6.
15. Greving JP, Wermer MJ, Brown RD Jr., Morita A, Juvela S, Yonekura M, *et al.* Development of the PHASES score for prediction of risk of rupture of intracranial aneurysms: A pooled analysis of six prospective cohort studies. *Lancet Neurol* 2014;13:59-66.
16. Etminan N, Brown RD Jr., Beseoglu K, Juvela S, Raymond J, Morita A, *et al.* The unruptured intracranial aneurysm treatment score: A multidisciplinary consensus. *Neurology* 2015;85:881-9.
17. Ravindra VM, de Havenon A, Gooldy TC, Scoville J, Guan J, Couldwell WT, *et al.* Validation of the unruptured intracranial aneurysm treatment score: Comparison with real-world cerebrovascular practice. *J Neurosurg* 2018;129:100-6.
18. Bijlenga P, Gondar R, Schilling S, Morel S, Hirsch S, Cuony J, *et al.* PHASES score for the management of intracranial aneurysm: A cross-sectional population-based retrospective study. *Stroke* 2017;48:2105-12.
19. Ujiie H, Tachibana H, Hiramatsu O, Hazel AL, Matsumoto T, Ogasawara Y, *et al.* Effects of size and shape (aspect ratio) on the hemodynamics of saccular aneurysms: A possible index for surgical treatment of intracranial aneurysms. *Neurosurgery* 1999;45:119-29.
20. Sonobe M, Yamazaki T, Yonekura M, Kikuchi H. Small unruptured intracranial aneurysm verification study: SUAVE study, Japan. *Stroke* 2010;41:1969-77.

21. Komotar RJ, Mocco J, Solomon RA. Guidelines for the surgical treatment of unruptured intracranial aneurysms: The first annual J. Lawrence pool memorial research symposium – Controversies in the management of cerebral aneurysms. *Neurosurgery* 2008;62:183-93.
22. Raabe A, Beck J, Gerlach R, Zimmermann M, Seifert V. Near-infrared indocyanine green video angiography: A new method for intraoperative assessment of vascular flow. *Neurosurgery* 2003;52:132-9.
23. Raabe A, Nakaji P, Beck J, Kim LJ, Hsu FP, Kamerman JD, *et al.* Prospective evaluation of surgical microscope-integrated intraoperative near-infrared indocyanine green videoangiography during aneurysm surgery. *J Neurosurg* 2005;103:982-9.
24. Washington CW, Zipfel GJ, Chicoine MR, Derdeyn CP, Rich KM, Moran CJ, *et al.* Comparing indocyanine green videoangiography to the gold standard of intraoperative digital subtraction angiography used in aneurysm surgery. *J Neurosurg* 2013;118:420-7.
25. Payner TD, Horner TG, Leipzig TJ, Scott JA, Gilmore RL, DeNardo AJ. Role of intraoperative angiography in the surgical treatment of cerebral aneurysms. *J Neurosurg* 1998;88:441-8.
26. Riva M, Amin-Hanjani S, Giussani C, De Witte O, Bruneau M. Indocyanine green videoangiography in aneurysm surgery: Systematic review and meta-analysis. *Neurosurgery* 2018;83:166-80.
27. Sato T, Suzuki K, Sakuma J, Takatsu N, Kojima Y, Sugano T, *et al.* Development of a new high-resolution intraoperative imaging system (dual-image videoangiography, DIVA) to simultaneously visualize light and near-infrared fluorescence images of indocyanine green angiography. *Acta Neurochir (Wien)* 2015;157:1295-301.
28. Feletti A, Wang X, Tanaka R, Yamada Y, Suyama D, Kawase T, *et al.* Dual-image videoangiography during intracranial microvascular surgery. *World Neurosurg* 2017;99:572-9.
29. Taniguchi M, Takimoto H, Yoshimine T, Shimada N, Miyao Y, Hirata M, *et al.* Application of a rigid endoscope to the microsurgical management of 54 cerebral aneurysms: Results in 48 patients. *J Neurosurg* 1999;91:231-7.
30. Kato Y, Sano H, Nagahisa S, Iwata S, Yoshida K, Yamamoto K, *et al.* Endoscope-assisted microsurgery for cerebral aneurysms. *Minim Invasive Neurosurg* 2000;43:91-7.
31. Tamaki N, Hara Y, Takaishi Y, Shimada S. Angled rigid neuroendoscope for continuous intraoperative visual monitoring: Technical note. *J Clin Neurosci* 2001;8:148-50.
32. Kalavakonda C, Sekhar LN, Ramachandran P, Hechl P. Endoscope-assisted microsurgery for intracranial aneurysms. *Neurosurgery* 2002;51:1119-26.
33. Mielke D, Malinova V, Rohde V. Comparison of intraoperative microscopic and endoscopic ICG angiography in aneurysm surgery. *Neurosurgery* 2014;10 Suppl 3:418-25.
34. Galzio RJ, Di Cola F, Raysi Dehcordi S, Ricci A, De Paulis D. Endoscope-assisted microneurosurgery for intracranial aneurysms. *Front Neurol* 2013;4:201.
35. Sharma BS, Kumar A, Sawarkar D. Endoscopic controlled clipping of anterior circulation aneurysms via keyhole approach: Our initial experience. *Neurol India* 2015;63:874-80.
36. Yoshioka H, Kinouchi H. The roles of endoscope in aneurysmal surgery. *Neurol Med Chir (Tokyo)* 2015;55:469-78.
37. Yamada Y, Kato Y, Ishihara K, Ito K, Kaito T, Nouri M, *et al.* Role of endoscopy in multi-modality monitoring during aneurysm surgery: A single center experience with 175 consecutive unruptured aneurysms. *Asian J Neurosurg* 2015;10:52.
38. Szelényi A, Kothbauer K, de Camargo AB, Langer D, Flamm ES, Deletis V. Motor evoked potential monitoring during cerebral aneurysm surgery: Technical aspects and comparison of transcranial and direct cortical stimulation. *Neurosurgery* 2005;57:331-8.
39. Szelényi A, Langer D, Beck J, Raabe A, Flamm ES, Seifert V, *et al.* Transcranial and direct cortical stimulation for motor evoked potential monitoring in intracerebral aneurysm surgery. *Neurophysiol Clin* 2007;37:391-8.
40. Motoyama Y, Kawaguchi M, Yamada S, Nakagawa I, Nishimura F, Hironaka Y, *et al.* Evaluation of combined use of transcranial and direct cortical motor evoked potential monitoring during unruptured aneurysm surgery. *Neurol Med Chir (Tokyo)* 2011;51:15-22.
41. Seng LB, Yamada Y, Rajagopal N, Mohammad AA, Teranishi T, Miyatani K, *et al.* Multimodality techniques in microsurgical clipping as the gold standard treatment in the management of basilar tip aneurysm: A case series. *Asian J Neurosurg* 2018;13:1148-57.
42. Joo SP, Kim TS. The clinical importance of perforator preservation in intracranial aneurysm surgery: An overview with a review of the literature. *Chonnam Med J* 2017;53:47-55.
43. Molyneux A, Kerr R, International Subarachnoid Aneurysm Trial (ISAT) Collaborative Group, Stratton I, Sandercock P, Clarke M, *et al.* International subarachnoid aneurysm trial (ISAT) of neurosurgical clipping versus endovascular coiling in 2143 patients with ruptured intracranial aneurysms: A randomized trial. *J Stroke Cerebrovasc Dis* 2002;11:304-14.
44. McDougall CG, Spetzler RF, Zabramski JM, Partovi S, Hills NK, Nakaji P, *et al.* The barrow ruptured aneurysm trial. *J Neurosurg* 2012;116:135-44.
45. Molyneux AJ, Birks J, Clarke A, Sneade M, Kerr RS. The durability of endovascular coiling versus neurosurgical clipping of ruptured cerebral aneurysms: 18 year follow-up of the UK cohort of the international subarachnoid aneurysm trial (ISAT). *Lancet* 2015;385:691-7.
46. Thomas AJ, Ogilvy CS. ISAT: Equipoise in treatment of ruptured cerebral aneurysms? *Lancet* 2015;385:666-8.
47. Bakker NA, Veeger NJ, Van Dijk JM. ISAT: End of the debate on coiling versus clipping? *Lancet* 2015;385:2251.
48. Spetzler RF, McDougall CG, Albuquerque FC, Zabramski JM, Hills NK, Partovi S, *et al.* 3-year results. *Neurosurg* 2013;119:146-57. Available from: <http://www.ncbi.nlm.nih.gov/pubmed/23621600>. [Last accessed on 2019 Feb 22].
49. Spetzler RF, McDougall CG, Zabramski JM, Albuquerque FC, Hills NK, Russin JJ, *et al.* The barrow ruptured aneurysm trial: 6-year results. *J Neurosurg* 2015;123:609-17.
50. Nanda A, Patra DP, Bir SC, Maiti TK, Kalakoti P, Bollam P, *et al.* Microsurgical clipping of unruptured intracranial aneurysms: A single surgeon's experience over 16 years. *World Neurosurg* 2017;100:85-99.
51. Spetzler RF, Zabramski JM, McDougall CG, Albuquerque FC, Hills NK, Wallace RC, *et al.* Analysis of saccular aneurysms in the barrow ruptured aneurysm trial. *J Neurosurg* 2018;128:120-5.