

A Case Series of Craniopharyngioma: Epidemiological Study and Management Analysis at Tertiary Care Center

Abstract

Introduction: Debate continues as to the optimal treatment for craniopharyngioma; radical surgical resection or partial resection followed by radiotherapy. Radical surgical resection may be complicated by intraoperative injury to surrounding structures and stormy postoperative hormonal problems. This study aims to examine the result of safe maximal surgical resection. **Methodology:** Retrospective study of all histopathologically proven craniopharyngiomas who had undergone surgical resection over an almost 4-year period was included. Data were collected reviewing demography, clinical presentation, hormonal dysfunction, extent of resection, and visual deterioration. Outcome was measured in terms of Glasgow Outcome Scale and recurrence. **Results:** Of 41 patients, 20(48.8%) were male and 21(51.2%) were female. Age of patients ranged from 1 to 59 years with a mean of 15.9 years. Thirty-seven patients (90%) had headache, 32 patients (78%) had visual disturbances, 23 patients (56%) had vomiting, and 10 patients (24%) had convulsions. Six patients (15%) had memory and sleep disorders and three patients of those >15 years (12.5%) had amenorrhea/sexual dysfunction. Patients who had surgery followed by radiotherapy had better prognosis, so also those aged 18 or less compared to older, males better than females and those without headache had better prognosis, though not statistically significant. **Conclusions:** Gross total excision if judiciously decided intraoperatively has a favorable outcome with acceptable morbidity. Patient has better prognosis who has surgery with radiotherapy.

Keywords: Craniopharyngioma, extent of resection, outcome

Introduction

Craniopharyngiomas (cranio = skull, pharynx = throat, and oma = tumor) are benign, slow-growing, locally invasive intracranial tumors that can generate considerable morbidity, and recurrences are often difficult to manage. Reliable morphologic criteria for accurately predicting the clinical outcome of these tumors are lacking. It has challenged the neurosurgeon and his skills for many years. These tumors have a very intricate relation with the hypothalamus, pituitary stalk, and optic apparatus, which have caused excessive problems regarding optimal management. In spite of its recognition in the late 1800's, no clear consensus is reached with regard to its treatment. Philosophy of treatment is not only different among different surgeons but also in the span of a surgeon's career. Computerized tomography (CT) and magnetic resonance imaging (MRI) are the investigations of choice, but today, the best imaging tool is

This is an open access journal, and articles are distributed under the terms of the Creative Commons Attribution-NonCommercial-ShareAlike 4.0 License, which allows others to remix, tweak, and build upon the work non-commercially, as long as appropriate credit is given and the new creations are licensed under the identical terms.

For reprints contact: reprints@medknow.com

MRI. Many people with craniopharyngioma go on to live uncompromised or relatively uncompromised lives. This is not always the outcome. Early detection and better therapeutic techniques are still required and must remain a priority. Total tumor removal is still the ideal form of treatment but should be attempted in situations when all the important adjacent structures can be safeguarded. Total tumor removal should be confirmed by a 3 month's postoperative CT scan and residual tumor should be treated with radiation therapy. Conservative removal of tumor is done when the cerebrovascular structures are at danger during surgery. The aim is to evacuate the distended cyst, excise as much as is absolutely safe and decompress the optic apparatus and hypothalamus. Residual tumor is irradiated. Karavtiki *et al.*^[1] reported the 10 years survival rates of 77% to 100% after partial resection and subsequent radiotherapy and 81.3%–100% after radiologically confirmed total removal. Data on the treatment option with the most favorable impact on survival are not consistent. Most studies^[1,2] suggest

How to cite this article: Ramanbhavana VS, Vara Prasad KS. A case series of craniopharyngioma: Epidemiological study and management analysis at tertiary care center. *Asian J Neurosurg* 2019;14:1196-202.

Venkata Satya Ramanbhavana, Kadali Satya Vara Prasad

Department of Neurosurgery,
Andhra Medical
College, King George
Hospital, Visakhapatnam,
Andhra Pradesh, India

Address for correspondence:

Dr. Venkata Satya
Ramanbhavana,
50-20-1, TPT Colony,
Seethammadhara,
Visakhapatnam,
Andhra Pradesh, India.
E-mail: ramanbhavana@gmail.
com

Access this article online

Website: www.asianjns.org

DOI: 10.4103/ajns.AJNS_67_19

Quick Response Code:



that postsurgical follow-up should be planned in 1–2 weeks for all patients and radiotherapy should start radiation within 3 weeks of surgery. Patients should be seen every 3 months for the first postsurgical year, every 6 months in the 2nd year, and 3rd years and yearly thereafter and should have a brain MRI/CT scan for comparison with previous films. In King George Hospital (KGH), no study has been done specifically to determine the incidence, management, and outcome of various treatment modalities on craniopharyngiomas, hence this study aims to generate useful data to improve the management of these patients.

Methodology

Study design

This is a descriptive hospital-based retrospective and prospective study to enable the researcher to get the required sample size due to the few number of patients.

Study setting

The study was conducted at the neurosurgery clinic, neurosurgical ward and histological results were retrieved at the pathology department and patients' files were retrieved from the records departments.

Study population

The cases treated from January 2014 to January 2018 at the above-mentioned units with a diagnosis of craniopharyngioma were recruited to the study and cases were followed for the duration of 3 and 6 months after treatment. Records of retrospective clients were retrieved and great effort used to follow-up and interview patients taking part in the study. The Karnofsky score, visual and motor deficits on admission; 1 week, 3 months, and 6 months postoperatively were recorded. Assistance of the ophthalmologists was required to assess visual acuity.

$$\text{Sample size } N = \frac{Z^2 c t P (1 - P)}{d^2}$$

Where N * Sample number

P * Prevalence of craniopharyngiomas among patients admitted with brain tumors (2%)

Z – Standard errors from the mean corresponding to 95% confidence interval

d = margin of error (absolute precision) (5%)

a = level of significance

The sample size was 41 patients.

Inclusion/exclusion criteria

- Inclusion criteria
 - All patients with confirmed diagnosis and admitted with craniopharyngioma in any department during the study period within the KGH
 - Patients who gave a voluntary informed consent.

- Exclusion criteria
 - Patients outside the above inclusion criteria
 - Patient not operated within KGH.

Data collection procedure

The information was collected using a data collection sheet (questionnaire). The same questionnaire was used for both the retrospective and prospective parts of the study. Demographic data including the age and sex were collected. The presenting symptoms, signs, and investigations done including laboratory and radiological prior to intervention and comorbidity factors such as hypertension, diabetes, and others were recorded. Preoperative care, treatment modalities, and complications after treatment were documented. Scoring of retrospective clients as per the Karnofsky and Lansky Scores was determined from the patient's file before admission, postoperatively and findings recorded in the file during the follow-up visits were used, and every effort was attempted to follow-up the patients at the neurosurgical clinic. The contacts recorded in the file were sought if the patients would have absconded to attend the follow-up clinics. Scoring of prospective patients as per the Karnofsky score was determined by the researcher on admission, 1-week and 3-months postoperatively, and the patients were followed up for a maximum period of 6 months.

Observation and Results

Incidence

The study assessed 41 patients who had been managed as cases of craniopharyngiomas from 2014 to 2018. Twenty-nine (71%) of the study participants were assessed prospectively and 12 (29%) were assessed retrospectively, over the study period of 2014–2018. There were 577 tumors treated at KGH, of which 41 (7.17%) were craniopharyngiomas. Figure 1 shows the proportion of brain tumors that were cases of craniopharyngioma treated at KGH over the period.

Demographics

There were 20 (48.8%) male and 21 (51.2%) female among the study participants. The mean age was 18.3 years with a mode of 5 and a standard deviation of 15.9 years. The youngest was <1 year and the oldest was 59 years. As shown in Table 1, craniopharyngioma was the most common in the age group (5–14 years [51.2%]).

As shown in Figure 2, the craniopharyngioma was more common in the younger population than in the older one.

Presenting complaints

Thirty-seven patients (90%) had headache, 32 patients (78%) had visual disturbances, 23 patients (56%) had vomiting, and 10 patients (24%) had convulsions. Six patients (15%) had memory and sleep disorders and 3 patients of those >15 years (12.5%) had amenorrhea/sexual dysfunction, as shown in Figure 3.

Physical examination findings

Six patients with oculomotor deficit, 3 patients (7%) had abducens nerve palsy, and 1 patient (2%) had vestibule cochlear nerve disorder, Twenty patients had decreased visual acuity and ten patients were totally blind as shown in Figure 4.

Laboratory investigations

As shown in Table 2, 4 out of 15 (26.7%), 2 out of 5 (40%), and 11 out of 21 (52.4%) had normal prolactin, growth hormone, and cortisol levels, respectively. Nine out of 15 (60.0%) patients had hyperprolactinemia and 13.3% had hypoprolactinemia, while three out of five patients (60%) had low growth hormone levels. Ten out

of 21 patients (47.6%) had hypocortisolemia as shown in Table 2.

Treatment

Forty-one patients were done CT-scanning and MRI. Twenty-six (63.4%) and 15 patients (36.6%) had suprasellar and sellar with suprasellar extension on radiological imaging, respectively, as shown in Figure 5.

Forty-one patients were done craniotomies. Twenty-three (57.5%) of the patients had surgery alone and seventeen (42.5%) underwent radiotherapy in addition to surgery. Thirty-seven (91.0%), three (7.5%), and one (2.5%) of the patients had partial excision/decompression, biopsy-only, and complete excision, respectively as show in Figure 6, during craniotomy and 23 (57.5%), underwent additional surgical procedures (ventriculoperitoneal shunt) to relieve hydrocephalus. Six patients had two craniotomies done due to confirmed tumor recurrence on follow-up.

Complications after surgical treatment

Forty-one patients were done craniotomies; no intraoperative death was reported. Thirteen patients (32.5%), seven (17.5%), nine (22.5%), seven (17.5%), and five (12.5%) had residual neurological deficits, diabetes insipidus, seizures, deteriorating neurological status, and

Table 1: Demographics

Characteristic	Retrospective (%)	Prospective (%)	Combined (%)	P of difference
Sex				
Male	14 (48.8)	6 (50.0)	20 (48.8)	0.920
Female	15 (51.7)	6 (50.0)	21 (51.2)	
Total	29 (70.7)	12 (29.3)	41 (100.0)	
Age groups				
0-4	1 (3.4)	3 (25.0)	4 (9.8)	0.993
5-14	18 (62.1)	3 (25.0)	21 (51.2)	
15-24	2 (6.9)	2 (16.7)	4 (9.8)	
25-34	3 (10.3)	2 (16.7)	5 (12.2)	
35-44	1 (3.4)	1 (8.3)	2 (4.9)	
45+	4 (13.8)	1 (8.3)	5 (12.2)	
Total	29 (70.7)	12 (29.3)	41 (100)	

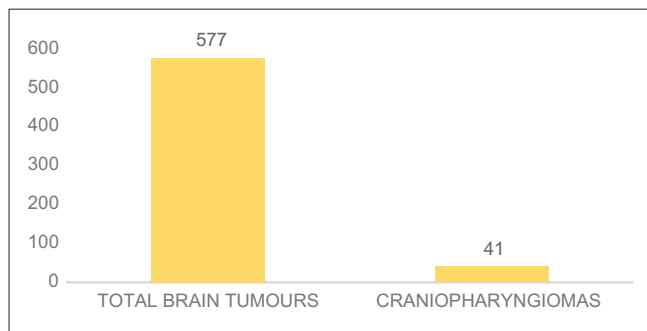


Figure 1: Proportion of tumors that were craniopharyngiomas treated at King George Hospital between 2014 and 2018

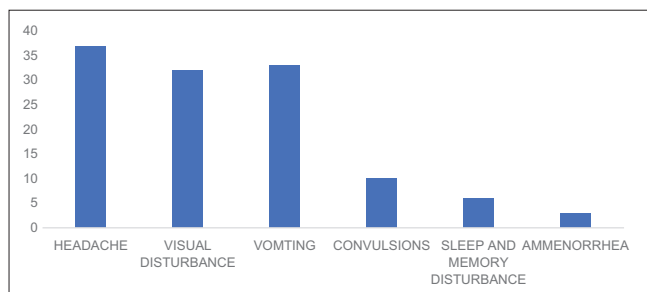


Figure 3: Presenting complaints

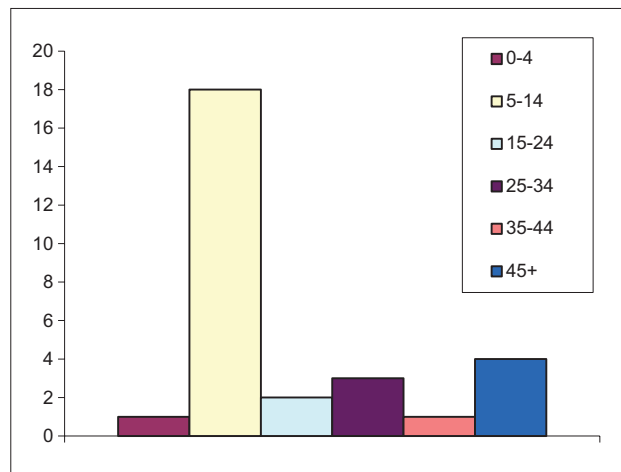


Figure 2: Age distribution

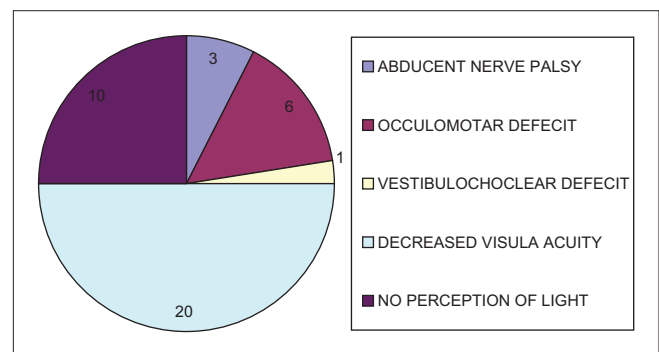


Figure 4: Clinical presentation

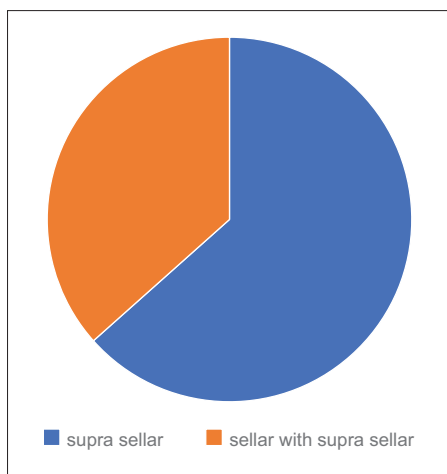


Figure 5: Radiological location of tumor

Table 2: Laboratory investigations-hormonal profile

Investigations	Value
Prolactin levels	
Normal	4
Lower	2
High	9
Total	15
Growth hormone levels	
Normal	2
Lower	3
Total	5
Cortisol levels	
Normal	11
Lower	10
Total	21

hydrocephalus, respectively, after surgical intervention. Postoperative infections (meningitis, wound sepsis, and pneumonia) occurred in seven patients (17.5%) during the follow-up period. Three patients (7.25%) had meningitis, one patient (2.0%) developed a wound infection, and three patients (7.25%) developed pneumonia.

Outcome

Overall outcome

Seventeen (41.4%) patients were dead, 23 (56.0%) had a good and moderate performance and 1 (2.4%) had a poor performance after surgery or surgery combined with radiotherapy upon 6 months of follow-up as shown in Figure 7.

Outcome in relation to type of treatment

12 out of 23 (52.1%) of patients were dead, 11 (47.8%) had a good and moderate performance, and none had a poor performance after 6 months of follow-up following surgical intervention alone and 4 out of 17 (17.6%) patients were dead, 12 (76.5%) had a good and moderate performance, and one (5.9%) had a poor performance after 6 months of

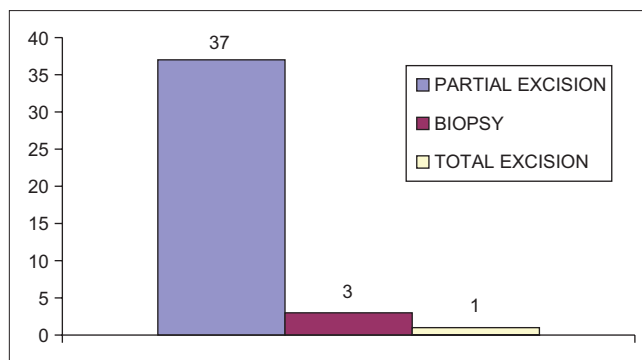


Figure 6: Type of procedure

follow-up following combined surgical and radiotherapy interventions.

Outcome in relation to type of surgery

As shown in Figure 8, outcome was more favorable in patients done biopsy only with 67% being alive at 6 months, whereas 44% of those done partial excision/decompression [Figures 9 and 10] being alive at 6 months, outcome was worse in the patient done complete excision.

Discussion

In a study at KNH by Mahindu,^[2] the relative incidence of craniopharyngioma was reported as 5.8%. In this study, the relative incidence is 7.1% which is different with the incidence reported by Cushing^[3] and Ruberti^[4] of 4.4%–4.6%. The majority of the patients in this study were mainly from the East and West Godavari probably due to the proximity to KGH. If the statistics from the rest of the country were considered, the results could have been different. There was no gender difference in the study participant. McDonald *et al.*^[5] reported in their study that there is no variation by gender or race and Shin *et al.*^[6] reported the same findings. Hoffman *et al.*^[7] from the hospital for sick children in Toronto in a study of total excision of craniopharyngioma in 50 children noted that the tumor was more common in boys than girls (56%, 44%), and this is supported by Nagpal^[8] and Baskin and Wilson^[9] (68%, 32%) and (54%, 36%), respectively. The age at diagnosis varies widely and cases have been reported in fetuses and in the elderly. It may occur at any age but most commonly presents in childhood or adolescence. A bimodal distribution by age with peak incidence rates in children (aged 5–14 years) and among older adults (aged 65–74) was noted.^[1] Fahlbusch *et al.*^[10] in Europe also noted a bimodal distribution with peak incidence at 15–20 years and another at 50–55 years. In this study, the tumor tends to occur in the young age groups of 0–14 years and 15–24 years. There is no bimodal distribution noted in this study. Kendall-Taylor *et al.*^[11] reported the peak age at onset as 15–20 years.

The most common presenting symptoms were headache (90%) and visual disturbances (78%),

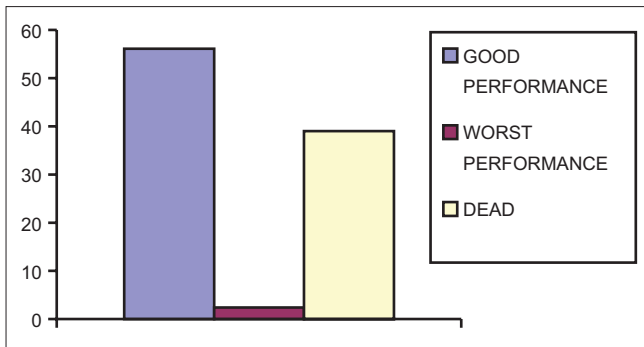


Figure 7: Outcome in relation to all type of treatment

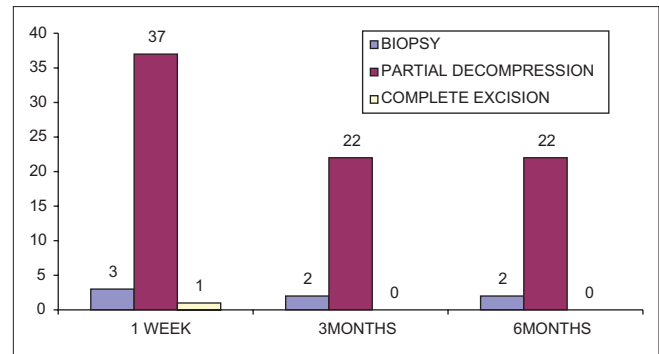


Figure 8: Outcome in relation to the type of surgery

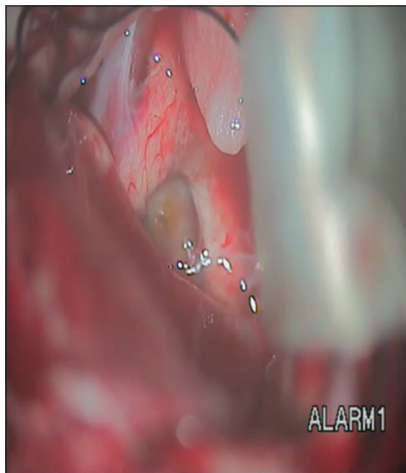


Figure 9: Retrochiasmatic cyst decompression

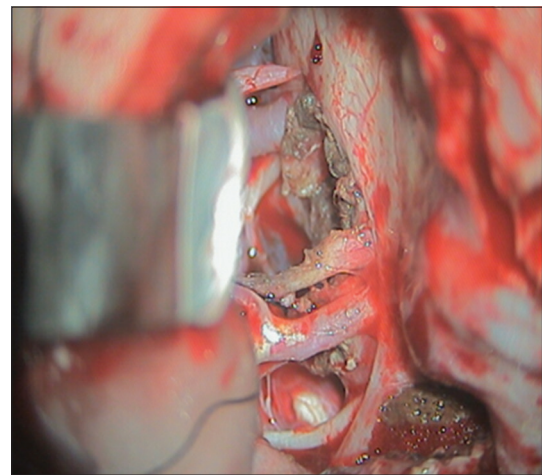


Figure 10: Partial decompression of tumor

which correspond to findings in other literature of headache (55%–86%) and visual disturbances (37%–68%). Honegger *et al.*^[12] showed visual compromise in 75.0% of patients compared with 78.0% in this study. Baskin and Wilson^[9] found that considering the pediatric and adult population together, on physical examination, 72% of patients have visual defects which correspond to the findings in this study, whereby 78% of the patients had visual defects. Nagpal^[8] found that the common presenting symptoms were headache and vomiting (48/63, 76%) and diminished vision (44/63, 70%) which corresponds to findings in this study. Other studies have reported the same.^[9,13-15] Amenorrhea/sexual dysfunction occurred in 3 out of 24 (12.5%) patients >15 years which concurs with findings reported by Nagpal^[8] of 8 out of 63 (13%) patients. Jennifer *et al.*^[16] found that most adult patients with craniopharyngioma present with amenorrhea (64%), impotence, or diminished libido (45%). In this study, hyperprolactinemia (60%) low growth hormone levels (60%), and hypocortisolism (47.6%) occurred in the tested population. In patients done hormonal tests, deficiency was found in 60% of patients compared to 39%–43% in the literature. Hypocortisolism occurred in 47.69% of tested patients in this study which is also comparable to 50% in other studies.^[16] This is due to the close anatomical relationship of the tumor with the

pituitary and hypothalamus leading to compression of these structures and thus various hormonal deficiencies.

CT and MRI are the examinations of choice. Although today MRI is the imaging tool of choice, almost all patients were done CT scanning. Most craniopharyngioma lesions were suprasellar 63.4% and only 36.6% were sellar with suprasellar extension. Craniopharyngioma lesions are located predominantly in the suprasellar area. Ten percentage of craniopharyngioma lesions are purely suprasellar in a study by Jennifer *et al.*^[16] and this is supported by Nagpal^[8] who reported suprasellar lesions/suprasellar extensions in 78% and only 1.6% of craniopharyngiomas were entirely intrasellar. This is related to development of the pituitary gland and the development of craniopharyngioma from the Rathke's cleft and craniopharyngeal duct remnants. Craniopharyngiomas are considered to be most effectively treated by a total excision.^[17-21] This is beset with many problems due to the close relationship of the tumors to the optic apparatus, carotid arteries, and the hypothalamus.^[19] Some tumors infiltrate into the hypothalamus,^[22] limited space between the chiasma, and the need to exert constant traction on the tumor during excision. In this study, complete excision was achieved in 1 out of 41 (2.5%), partial excision/decompression in 37 out of 41 (91.0%), and biopsy only

in 3 out of 41 (7.5%). In a study by Nagpal,^[8] biopsy and aspiration of cyst were done in 21 out of 58 patients (36%), partial and subtotal excision in 35 out of 58 (61%), and total excision in two patients (3%) which differs from the findings of this study. There is more tendency toward biopsy and aspiration of cyst in the Nagpal study.^[8] This illustrates the difficulty in surgical management of this condition.

Fahlbusch *et al.*^[10] in a study of 148 patients undergoing initial surgery, total tumor removal was accomplished in 45.7% of transcranial and 85.7% of transsphenoidal procedures. Reasons for incomplete removal were attachment and/or infiltration of the hypothalamus/major calcifications and attachment to vascular structures. 17 out of 40 patients (42.5%) received radiotherapy and 23 patients (57.5%) did not receive radiotherapy due to death in the immediate postoperative period, death at home/other peripheral health facilities after discharge, and loss to follow-up. In Nagpal study,^[8] 42 out of 58 (72.4%) patients received radiotherapy, which is higher than the number of patients who received radiotherapy in this study. Neurosurgical options at first surgery for craniopharyngioma included subtotal resection with radiotherapy (29%) Subtotal resection alone (57%) and gross total resection alone (14%) in a study by Jennifer *et al.*^[19]

Thomsett *et al.*^[23] in a review of the effect of treatment in 42 patients found that recurrence and mortality rates as well as neurological outcome of survivors were similar in children treated by radical excision and those treated by limited excision plus radiotherapy. The neurologic prognosis was poorest in those children who had limited excision or drainage without radiotherapy. Additional hypothalamopituitary dysfunction following treatment was less common in children who had limited excision plus radiotherapy than in children who had either limited excision or attempted total removal. They concluded that unless gross total tumor excision can be readily achieved, limited excision plus radiotherapy appears to be the treatment of choice for craniopharyngioma in childhood. 39% had a moderate and good outcome and 2.4% had a poor outcome at 6 months of follow-up. Nagpal^[8] at the time of the final evaluation of the 51 living patients found that 38 (74.5%) were independent, 9 (17.6%) were partially dependent, and 3 (6%) were dependent. Hoffman *et al.*^[22] at the final evaluation found that of the 46 children followed 64%, 27%, and 9% had good, moderate, and poor prognosis, respectively, which differs from the findings of this study.

In this study, the outcome was more favorable in patients <18 years, males, patients without headache, patients with vomiting, visual disturbances, hyperprolactinemia, hypoprolactinemia, and hypocortisolism. The outcome was also favorable in patients with completely suprasellar

lesions, intrasellar with suprasellar extension, patients done biopsy only, partial excision/decompression, and in those who received postoperative radiotherapy.

Bunin *et al.*^[24] in the USA found a 5-year survival rate of 80% and decreased with older age at diagnosis. Survival is higher among children and has improved in the recent years. Duff *et al.*^[25] found that 73 of 121 patients devaluated had a good outcome of a mean follow-up period of 10 years. A good outcome was associated with survival at the follow-up examination, functional vision; a Katz grade of A and a Karnofsky Performance Scale score of at least 80.

In this study, 7 patients (17.3%) had tumor recurrence after partial excision/biopsy. This is low in comparison to findings in other studies. This could be due to the high mortality rate in this study and lack of regular postoperative CT scan/MRI to assist in early detection of recurrence.

In the study by Shin *et al.*,^[6] recurrence rate was 62% and the mean time to recurrence + 24 months. None of the patients who had gross total resection had a recurrence in contrast to the 67% who had partial excision. The cumulative rates of recurrence-free survival were 57% at 5 years, 48% at 10 years, and 43% at 20 years. A similar recurrence rate (69%) with partial removal was found by Fahlbusch *et al.*^[10] Recent series reports indicate 81%–91% 10 years recurrence-free survival rate after subtotal tumor removal followed by radiotherapy with 46%–58% of the survivors living a normal independent life.^[26]

Conclusions

We believe that total removal of craniopharyngiomas is possible in selected cases, and it has been our experience in adults that this cannot often be achieved. A subtotal removal followed by radiation therapy has been a satisfactory approach in our hands, and with modern microsurgical techniques as well as with the advantages of modern radiotherapeutic techniques, this approach has led to remission in approximately 90% of our patients. While our follow-up period is admittedly short and it will be important to continue to follow these patients over the next several decades, it appears that with continuing and careful endocrine replacement therapy and monitoring, these patients can resume a fully functional life with few limitations.

Financial support and sponsorship

Nil.

Conflicts of interest

There are no conflicts of interest.

References

1. Karavitaki N, Brufani C, Warner JT, Adams CB, Richards P, Ansorge O, *et al.* Craniopharyngiomas in children and adults:

- Systematic analysis of 121 cases with long-term follow-up. *Clin Endocrinol (Oxf)* 2005;62:397-409.
2. Mahindu M. A 10-Month Prospective Study on Surgically Managed Intracranial Tumours at the Kenyatta National Hospital; 2004.
 3. Ruberti RF. Tumours of the central nervous system in the African. *Afri J Neurol Sci* 1989;8:24-9.
 4. Cushing H Eisenhardt L. *Meningiomas, Their Classification, Regional Behaviour, Life History, and Surgical Results.* Springfield III: Charles C. Thomas; 1938.
 5. MacDonald SM, Yock TI, Tarbell NJ, Vern-Gross TZ. Pediatric tumors. *Clin Radiat Oncol* 2017;99:805-43.
 6. Shin JL, Asa SL, Woodhouse LJ, Smyth HS, Ezzat S. Cystic lesions of the pituitary: Clinicopathological features distinguishing craniopharyngioma, Rathke's cleft cyst, and arachnoid cyst. *J Clin Endocrinol Metab* 1999;84:3972-82.
 7. Hoffman HJ, De Silva M, Humphreys RP, Drake JM, Smith ML, Blaser SI, *et al.* Aggressive surgical management of craniopharyngiomas in children. *J Neurosurg* 1992;76:47-52.
 8. Nagpal RD. Craniopharyngioma: Treatment by conservative surgery and radiation therapy. *J Postgrad Med* 1992;38:175-80.
 9. Baskin DS, Wilson CB. Surgical management of craniopharyngiomas. A review of 74 cases. *J Neurosurg* 1986;65:22-7.
 10. Fahlbusch R, Honegger J, Paulus W, Huk W, Buchfelder M. Surgical treatment of craniopharyngiomas: Experience with 168 patients. *J Neurosurg* 1999;90:237-50.
 11. Kendall-Taylor P, Jönsson PJ, Abs R, Erfurth EM, Koltowska-Hägström M, Price DA, *et al.* The clinical, metabolic and endocrine features and the quality of life in adults with childhood-onset craniopharyngioma compared with adult-onset craniopharyngioma. *Eur J Endocrinol* 2005;152:557-67.
 12. Honegger J, Buchfelder M, Fahlbusch R. Surgical treatment of craniopharyngiomas: Endocrinological results. *J Neurosurg* 1999;90:251-7.
 13. Lee IH, Zan E, Bell WR, Burger PC, Sung H, Yousem DM. Craniopharyngiomas: Radiological differentiation of two types. *J Korean Neurosurg Soc* 2016;59:466-70.
 14. Chatterjee T, Desai S, Lakhtakia R, Gill SS, Satyanarayana S. Suprasellar papillary squamous epithelioma (papillary craniopharyngioma). *Med J Armed Forces India* 2000;56:158-60.
 15. Carmel PW. Brain tumours of disordered embryogenesis. In: Youmans JR, editor. *Neurological Surgery.* 3rd ed. Philadelphia: WB Saunders; 1990. p. 3223-49.
 16. Shin JL, Asa SL, Woodhouse LJ. Cystic lesion of the pituitary: Clinicopathological features distinguishing craniopharyngioma, Rathke Cleft cyst and arachnoid cyst. p. 3972-82. doi: 10.1210/jc.84.11.3972.
 17. Yaşargil MG, Curcic M, Kis M, Siegenthaler G, Teddy PJ, Roth P, *et al.* Total removal of craniopharyngiomas. Approaches and long-term results in 144 patients. *J Neurosurg* 1990;73:3-11.
 18. Ota N, Tanikawa R, Miyama M, Miyazaki T, Kinoshita Y, Matsukawa H, *et al.* Radical resection of a craniopharyngioma via the extradural anterior temporal approach with zygomatic arch osteotomy. *Surg Neurol Int* 2016;7:S1113-20.
 19. Shin JL, Asa SL, Woodhouse LJ, Smyth HS, Ezza S. Cystic lesions of the pituitary: clinicopathological features distinguishing craniopharyngioma, Rathke's Cleft Cyst and Arachnoid cyst. doi:10.1210/jc.84.11.3972.
 20. Tomita T. Management of craniopharyngiomas in children. *Pediatr Neurosci* 1988;14:204-11.
 21. Ushio Y, Arita N, Yoshimine T, Nagatani M, Mogami H. Glioblastoma after radiotherapy for craniopharyngioma: Case report. *Neurosurgery* 1987;21:33-8.
 22. Hoffman HJ, Hendrick EB, Humphreys RP, Buncic JR, Armstrong DL, Jenkin RD, *et al.* Management of craniopharyngioma in children. *J Neurosurg* 1977;47:218-27.
 23. Thomsett MJ, Conte FA, Kaplan SL, Grumbach MM. Endocrine and neurologic outcome in childhood craniopharyngioma: Review of effect of treatment in 42 patients. *J Pediatr* 1980;97:728-35.
 24. Bunin GR1, Surawicz TS, Witman PA, Preston-Martin S, Davis F, Bruner JM. The descriptive epidemiology of craniopharyngioma. *Neurosurg* 1998;89:547-51.
 25. Duff J, Meyer FB, Ilstrup DM, Laws ER Jr., Schleck CD, Scheithauer BW, *et al.* Long-term outcomes for surgically resected craniopharyngiomas. *Neurosurgery* 2000;46:291-302.
 26. Rajan B, Ashley S, Gorman C, Jose CC, Horwich A, Bloom HJ, *et al.* Craniopharyngioma – A long-term results following limited surgery and radiotherapy. *Radiother Oncol* 1993;26:1-10.