

Institutional Experience of Microsurgical Management in Posterior Circulation Aneurysm

Abstract

Introduction: Posterior circulation aneurysm constitutes 15%–20% of all intracerebral aneurysms. With the advancement of endovascular techniques, the microsurgery for posterior circulation aneurysms has been pushed back a little. Even the International Subarachnoid Aneurysmal Trial gave support to the concepts of endovascular procedures, but microsurgical modality should not be discouraged. We present our institutional experience of microsurgical techniques on posterior circulation aneurysms. **Materials and Methods:** We performed a retrospective analysis of 37 patients of posterior circulation aneurysm from 2015 to 2019, referred to Bantane Hospital, Japan. We included all posterior circulation aneurysms such as basilar tip, basilar trunk, and vertebral artery-posterior inferior cerebellar artery (VA-PICA) aneurysms, admitted and treated with clipping or bypass and trapping. We assessed the outcome as measured by modified Rankin Score (mRS), complications, and mortality. **Results:** Out of 37 patients, 10 cases were a basilar tip, one case was the basilar trunk, and 26 cases were VA-PICA aneurysm. Intraoperatively, neuromonitoring, indocyanine green dye, dual-image videoangiography (DIVA), and neuro endoscope were used. Two patients of basilar tip aneurysm developed third cranial nerve paresis and six patients of VA-PICA aneurysm developed lower cranial nerve paresis which resolved spontaneously. All the patients were discharged with mRS of 0 or 1. No mortality was recorded in our study. **Conclusion:** Microsurgical clipping of posterior circulation aneurysm is safe in unruptured aneurysm with a very low risk of mortality and morbidity under experienced hands. All postoperative complications in our study were transient and resolved with time with no residual deficits. Preoperative simulation, intraoperative neuromonitoring, DIVA, and neuro endoscope help achieve complete obliteration of aneurysmal sac and avoid complications.

Keywords: Basilar tip aneurysm, dual-image videoangiography, posterior circulation aneurysm, vertebral artery-posterior inferior cerebellar artery aneurysm

Introduction

Aneurysms arising from the posterior circulation constitute about 15%–20% of all aneurysms.^[1,2] Morbidity and mortality are high in these types of aneurysms. For neurosurgeons, it is a very challenging task to deal with these types of aneurysms. Difficult location and multiple brain stem perforators make the situation worse for neurosurgeons. Surgery on these types of aneurysm requires great experience, mastery in skull base anatomy, proper planning, and approach. After the International Study of Unruptured Intracranial Aneurysm (ISUIA) and the International Subarachnoid Aneurysm Trial, the inclination toward endovascular procedures had increased and microvascular surgeries had

decreased.^[3,4] In the recent era, anterior circulation aneurysms are treated with endovascular as well as microsurgically, but in contrast, the posterior circulation aneurysms are preferably treated by endovascular techniques. However, for successful posterior circulation aneurysm treatment, multimodality treatment is required. We share our experiences of the last 5 years at Bantane Hospital, Fujita Health University, Japan, in the surgical management of posterior circulation aneurysm to demonstrate that microsurgery plays a vital role in the management and should not be stepped down.

Materials and Methods

We performed a retrospective analysis of all posterior circulation aneurysms including

How to cite this article: Sharma RK, Kumar A, Yamada Y, Tanaka R, Sharma S, Miyatani K, *et al.* Institutional experience of microsurgical management in posterior circulation aneurysm. *Asian J Neurosurg* 2020;15:484-93.

Submission: 26-Feb-2020 **Revised:** 01-Apr-2020
Accepted: 12-May-2020 **Published:** 28-Aug-2020

Raghavendra Kumar Sharma, Ambuj Kumar¹, Yasuhiro Yamada², Riki Tanaka², Saurabh Sharma³, Kyosuke Miyatani², Saeko Higashiguchi², Tsukasa Kawase², Srikanth Talluri⁴, Yoko Kato²

Department of Neurosurgery, AIIMS, Raipur, Chhattisgarh, ¹Department of Neurosurgery, N.S.C.B. Medical College, Jabalpur, Madhya Pradesh, ⁴Department of Neurosurgery, SVIMS, Tirupati, Andhra Pradesh, ³Department of Neurosurgery, Max Hospital, New Delhi, India, ²Department of Neurosurgery, Bantane Hospital, Fujita Health University, Nagoya, Japan

Address for correspondence:

Dr. Raghavendra Kumar Sharma,
Department of Neurosurgery,
AIIMS, Raipur, Chhattisgarh,
India.
E-mail: sdr.raghavendra@gmail.com

Access this article online

Website: www.asianjns.org

DOI: 10.4103/ajns.AJNS_69_20

Quick Response Code:



This is an open access journal, and articles are distributed under the terms of the Creative Commons Attribution-NonCommercial-ShareAlike 4.0 License, which allows others to remix, tweak, and build upon the work non-commercially, as long as appropriate credit is given and the new creations are licensed under the identical terms.

For reprints contact: WKHLRPMedknow_reprints@wolterskluwer.com

basilar tip, trunk, and vertebral artery-posterior inferior cerebellar artery (VA-PICA) aneurysm, referred to Bantane Hospital, Fujita Health University, Nagoya, Japan, and managed by microvascular techniques from 2015 to 2019. Every aneurysm's characteristics were analyzed, which include aneurysm size, morphology, the dominance of vertebral and posterior communicating arteries, anomaly, aneurysm origin, and collateral circulation. For basilar tip and trunk aneurysms, pterional craniotomy with or without modification was used. Anterior clinoidectomy was done to achieve better visualization of high riding basilar tip aneurysm;^[5] this excess bony work provides enough space in the operating corridor for clipping. However, in low riding aneurysm, we performed posterior clinoidectomy. In our institution for VA-PICA aneurysm, far-lateral transcondylar approach was preferred. Jugular tubercle was drilled out up to the condylar emissary vein and only 30% of the occipital condyle was drilled out as this drilling was sufficient to give enough operating field. However, the study suggests that unilateral resection of condyle does not result in craniovertebral instability.^[6] If the aneurysm was large and PICA was originating from the fundus or in such a way that clipping was impossible without sacrificing the PICA, then bypass procedure and trapping of the aneurysm was chosen. The occipital artery (OA) PICA bypass was preferred in these types of cases. If the opposite VA was not hypoplastic and if after trapping there was no change in PICA flow (due to collaterals), then only trapping was performed.

Preoperatively, we performed computed tomography angiography (CTA) with three-dimensional (3D) reconstruction in every patient, magnetic resonance imaging (MRI), and digital subtraction angiography (DSA), if necessary. To know the characteristics of the aneurysm, laminar flow, and weak point in aneurysm wall, we performed computational fluid dynamics (CFDs) in every aneurysm. Intraoperative neuromonitoring (somatosensory-evoked potential [SSEP] and motor-evoked potential [MEP]), intraoperative Doppler, neuro endoscope, and dual-image

videoangiography (DIVA) were used. Each case was analyzed for age, sex, intraoperative or postoperative complications, and outcomes in the form of a modified Rankin score (mRS) during discharge. The outcome was compared with those of other studies of endovascular and microsurgical techniques.

Results

Demographic data

The total number of patients in our study was 37, and all these patients were a homogenous Japanese population. It included unruptured basilar tip aneurysms, basilar trunk aneurysm, and VA-PICA aneurysms [Tables 1-3]. The median age for basilar tip and trunk aneurysm was 58 years (range 52–78) and for VA-PICA aneurysm was 58.5 years (range 42-84). Female patients constitute (19/37) 51.3%, and the rest were male. Headache was the most common presenting feature of these aneurysms in our series, and one patient of VA-PICA giant aneurysm presented with the 7th cranial nerve paresis due to mass effect.

Aneurysm characteristics

Our study included all unruptured aneurysms of the posterior circulation. Nine out of 37 (24.32%) patients had multiple intracranial aneurysms. Out of these, ten patients had basilar top aneurysm, one patient has a basilar trunk, and 26 patients had VA-PICA aneurysm [Tables 1 and 3].

The size of all basilar tip and trunk aneurysm was <7 mm, and all basilar tip aneurysms were saccular. The size of VA-PICA aneurysms was from 4 mm to 26 mm with only one giant aneurysm. Four aneurysms were fusiform and 22 were saccular. All basilar tip and trunk aneurysms underwent clipping; 13 patients of VA-PICA aneurysms underwent clipping, seven underwent trapping, one was managed by aneurysmorrhaphy (bipolar coagulation dome remodeling of aneurysm), and five VA-PICA aneurysms were managed by OA-PICA bypass along with trapping.

Table 1: Preoperative neuroimaging and findings in basilar artery aneurysm patients

Preoperative imaging	Size (mm)	Characteristic of A	Other findings
CTA	3.5	Superior	Acom
CTA, MRA	4	Posterior	IC-Acho, Fetal Pcom
DSA, MRA	3	Anterior	None
CTA, DSA, MRA	4	Anterior	None
CTA, DSA, MRA	7	Superior	MCA, IC-Pcom, MCA-ICA, IC-Acho, AC
DSA, MRA	6	Superior	ICA
CTA, MRA	6.5	Anterior	MCA
CTA, MRA	7	Superior	Fetal Pcom
CTA, MRA	3	Superior	None
CTA, MRA	3	Posterior	Acom, MCA, IC-Acho
CTA, MRA	4	Fusiform basilar trunk	None

CTA – Computed tomography angiography; MCA – Middle cerebral artery; DSA – Digital subtraction angiography, IC-Acho – Internal carotid-arterial choroidal artery; ICA – Inferior cerebellar artery; MRA – Magnetic resonance angiography

Table 3: Aneurysmal characteristics, surgical techniques of aneurysm dealing, complications, and patient status on discharge in vertebral artery-posterior inferior cerebellar artery aneurysm patients

ID	Age	Sex	Aneurysm size	Another aneurysm	Surgery	Occlusion	Complication	mRS at discharge
1	42	Male	12		Aneurysmorraphy	No increase	None	0
2	65	Female	15	MCA	Clipping	Complete	None	0
3	79	Female	4		Clipping	Complete	None	0
4	52	Male	18		Clipping	Complete	None	0
5	49	Male	8		Clipping	Complete	None	0
6	42	Male	20	MCA	Clipping	Complete	None	0
7	79	Female	4		Clipping	Complete	None	0
8	72	Female	5		Clipping	Complete	None	0
9	42	Male	10		Clipping	Complete	RL palsy	1
10	58	Male	5		Clipping	Complete	None	0
11	48	Female	6		Clipping	Neck remnant	None	0
12	84	Female	5		Clipping	Complete	None	0
13	59	Male	10		Clipping	Complete	RL palsy	1
14	55	Male	15		OA-PICA + TRAP	Complete	None	0
15	83	Female	20		OA-PICA + TRAP	Complete	None	0
16	65	Male	12		OA-PICA + TRAP	Complete	10 th CN	1
17	66	Male	4	MCA	OA-PICA + TRAP	Complete	RL palsy	1
18	70	Female	7		OA-PICA + TRAP	Complete	12 th CN	1
19	70	Female	6		OA-PICA + TRAP	Complete	RL palsy	1
20	68	Female	4		Trapping	Complete	None	0
21	53	Male	12		Trapping	Complete	None	0
22	53	Male	26		Trapping	Complete	None	0
23	46	Male	9		Trapping	Small residual sac	None	0
24	43	Male	13		Trapping	Complete	None	0
25	52	Male	15		Trapping	Complete	None	0
26	64	Female	13		Clipping	Complete	None	0

mRS – Modified Rankin score; MCA – Middle cerebral artery; OA-PICA – Occipital artery-posterior inferior cerebellar artery; CN – Cranial nerve; RL – Recurrent laryngeal nerve

Table 2: Surgical approaches, complications, and patient status on discharge in basilar artery aneurysm patients

Age	Sex	Surgery performed	Complication	mRS at discharge
76	Female	Pterional and clipping	None	0
60	Male	Pterional and clipping	None	0
53	Female	Anterior temporal and clipping	Transient third CN palsy	1
64	Female	Pterional and clipping	None	0
78	Female	Pterional and clipping	None	0
56	Female	Pterional and clipping	None	0
58	Male	Pterional and clipping	Transient third CN palsy	1
55	Female	Anterior temporal and clipping	None	0
53	Male	Anterior temporal and clipping	None	0
52	Female	Pterional and clipping	None	0
75	Female	Pterional and clipping	None	0

Outcome of basilar. mRS – Modified Rankin score; CN – Cranial nerve

Outcome

In our series of unruptured posterior circulation aneurysm, all the 37 patients were discharged with a favorable mRS. Out of the 37 patients, 28 patients discharged with an mRS score of 0, and only 8 patients had an mRS score of 1. Zero mortality was reported in our series. Out of 11 basilar tip and trunk aneurysms, 2 patients developed transient oculomotor paresis

which improved in the subsequent follow-up [Table 2]. One of the basilar tip aneurysm patients developed hydrocephalus and another developed chronic subdural hematoma ipsilateral to the surgical site in the follow-up. Hydrocephalus was treated with lumboperitoneal shunt (institutional preference in postsubarachnoid hemorrhage communicating hydrocephalus), and surgical evacuation of chronic hematoma was done. They also recovered very well. Among 26 VA-PICA aneurysms,

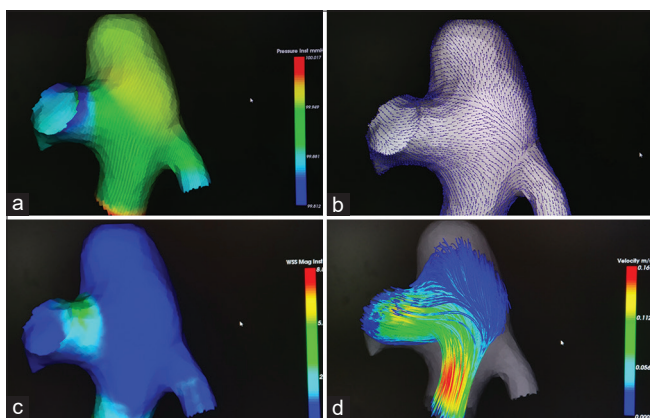


Figure 1: A computational fluid dynamic. (a) Moderate wall pressure within the sac of the basilar artery tip aneurysm; (b) wall shear stress vectors showing change in the direction of angle of the vectors at the neck and sac of the aneurysm in comparison with the vectors in the bifurcation; (c) wall shear stress pressure showing a low wall shear stress pressure within the aneurysmal sac, suggestive of low flow within the aneurysmal sac with high risk of rupture in a narrow neck and small saccular aneurysm; (d) streamline showing disturbed laminar flow within the sac of the aneurysm

6 patients developed lower cranial nerve palsy [Table 3]. On regular follow-up, they gradually improved. One patient underwent partial clipping and one had residual aneurysm neck; these patients are under close follow-up and have not required another procedure.

Illustrative case 1

A 52-year-old female patient with no comorbidities presented with an incidental finding of posterior pointing basilar tip aneurysm during a brain-screening program using an MRI brain with magnetic resonance angiography (MRA). She was a nonsmoker and nonalcoholic. Previously, she had been screened for an endovascular procedure, but due to narrow distance between aneurysmal sac and perforators, she was referred to Bantane hospital, Nagoya. Preoperatively, 3D CTA, DSA, and CFD were performed [Figures 1 and 2]. CFD showed high wall pressure, low shear stress, and disturbed laminar flow within the aneurysm sac. The basilar tip aneurysm was 2.8 mm × 3.0 mm and directed posteriorly. Left pterional craniotomy was performed, and the clip was applied [Figures 3 and 4]. Intraoperatively, we found two small aneurysms: one at the internal carotid-anterior choroidal artery junction and another at the middle cerebral artery bifurcation, which was also clipped. Intraoperative neuromonitoring, indocyanine green (ICG), DIVA, and neuro endoscope were used. Postoperatively, she was extubated immediately with no neurological deficit. The patient was discharged after 10 days with an mRS of 0, and a follow-up scan showed no residual neck.

Illustrative case 2

A 75-year-old female patient with no associated illness was incidentally diagnosed with basilar trunk aneurysm. This was also diagnosed during a screening program for which she was taken to Bantane Hospital, Nagoya. Preoperatively, CTA was done as a routine protocol for an

aneurysm. A 4.0 mm × 2.7 mm basilar trunk aneurysm was found proximal to the superior cerebellar artery [Figure 5]. CFD showed very high wall pressure, low shear stress, and disturbed laminar flow within the aneurysm sac [Figure 6]. Left pterional craniotomy was planned. Intraoperatively, an aneurysm sac wall was atherosclerotic, and two tandem clips were applied [Figure 7]. We use intraoperative neuromonitoring in every case. Distal blood flow in basilar artery and perforators was confirmed by ICG. There was no residual neck in postoperative CTA, and the patient was discharged with no neurological deficit. Her mRS was 0.

Illustrative case 3

A 64-year-old female was routinely screened for intermittent headache. The patient underwent MRA, CTA, and DSA, which showed a saccular aneurysm at VA-PICA confluence of size 4 mm X 5.2 mm with neck size of 3.6 mm [Figure 8]. The PICA was arising opposite to the neck of the aneurysm. CFD showed high wall pressure, low shear stress, and disturbed laminar flow within the aneurysm sac [Figure 9]. VA of the ipsilateral side was dominant. The patient underwent left transcondylar far-lateral craniotomy, and tandem two aneurysmal clips were applied. The flow to the PICA and complete clipping of aneurysm were confirmed using intraoperative ICG and DIVA. Clip direction and absence of residual neck were also reconfirmed using neuro endoscope [Figure 10]. During the postoperative period, she developed mild nonspecific symptoms that were treated symptomatically, otherwise, her hospital stay was uneventful. Postoperatively, CTA showed complete obliteration of the aneurysm [Figure 8]. The patient was discharged with a good outcome with an mRS of 0. In the follow-up period, the frequency of intermittent headache was reduced.

Discussion

The incidence of posterior circulation aneurysm is about 15%–20% in different studies.^[1,2] The incidence of multiple aneurysms is about 10%–30%.^[7,8] In our retrospective study, we found that 24.32% of patients had multiple aneurysms, which are collaborating with other studies.^[7,8] The management of posterior circulation has been a tough task due to multiple issues in which proximity to the brain stem, multiple perforators to the brain stem, and eloquent areas of the brain are important ones.^[9] Due to this complex anatomy, the margin of error is too narrow.

According to the international study of unruptured aneurysm, the risk of rupture of posterior circulation aneurysms is high as compared with anterior circulation aneurysm, especially basilar bifurcation aneurysm.^[3] To describe the natural history of the unruptured aneurysm in ISUIA, the patients were divided into Group 1 (patients with unruptured aneurysm without subarachnoid hemorrhage from a separate aneurysm) and Group 2 (patients with unruptured aneurysm with subarachnoid hemorrhage from

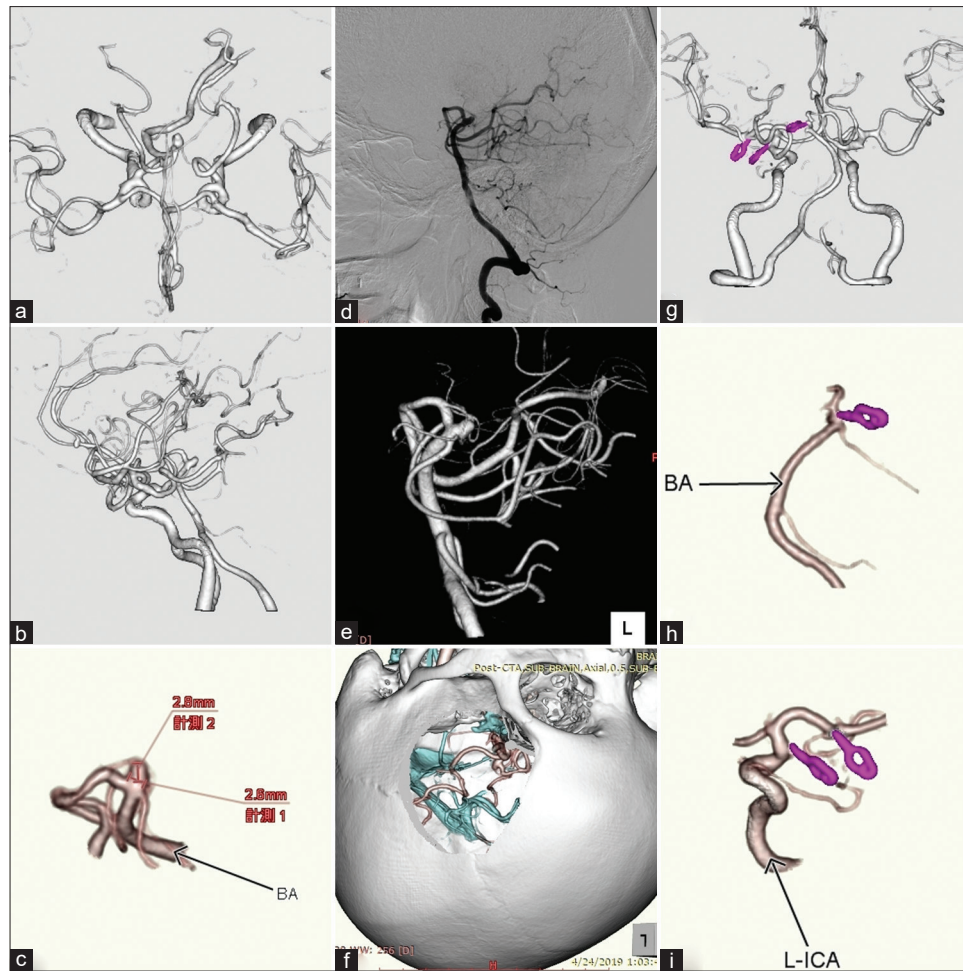


Figure 2: (a) Preoperative three-dimensional computed tomography angiography of patient showing basilar tip aneurysm on head view; (b) lateral view; (c) measurement of basilar tip aneurysm; (d) lateral view in DSA; (e) three-dimensional lateral view of aneurysm; (f) three-dimensional computed tomography angiography and venography with removal of bone simulating the best surgical approach for aneurysm; (g) postoperative three-dimensional computed tomography angiographic image showing clipped basilar tip, middle cerebral artery bifurcation, anterior choroidal artery aneurysms; (h and i) three-dimensional computed tomography reconstructed angiographic images of isolated basilar artery and left inferior cerebellar artery showing well-clipped aneurysms with no residual neck

a separate aneurysm). Over a period of 5 years, the risk of rupture of anterior circulation aneurysm is 0% and 1.5% in Group 1 and Group 2, respectively, whereas the rupture risk in posterior circulation aneurysm is 2.5% and 3.4%, respectively, in Groups 1 and 2, which is higher. Rinkel *et al.* also reported in their systemic review that symptomatic aneurysms, posterior circulation, and large (>10 mm) aneurysms had a higher risk of rupture.^[10]

Studies suggest that the risk of rupture of the aneurysm is 2.5 times higher in the Japanese population as compared with the general population, which is 21.1–24.8/100,000 person-year.^[11] A Japanese study of unruptured cerebral aneurysm showed that aneurysms at the basilar tip and basilar-superior cerebellar artery (10–24 mm) had a 6.94 annual rupture rate per aneurysm, which is higher as compared with other aneurysms located at the different site.^[12]

Raaymakers *et al.* described in their meta-analysis that the outcome depends on age, location (anterior or posterior), and size of the aneurysm. In that study, they analyzed that

patients with nongiant aneurysms at anterior circulation have approximated mortality and morbidity of 0.8% and 1.9%, respectively. However, the corresponding values are 3.0% and 12.9% in posterior circulation aneurysms. In giant anterior circulation aneurysms, the mortality and morbidity are 7.4% and 26.9%, respectively, but in giant posterior circulation aneurysms, it is 9.6% and 37.9%, respectively, which is much high.^[13]

Eftekhari and Morgan described the good outcome after surgical clipping of posterior circulation aneurysm, in which they showed that in 136 small unruptured vertebrobasilar aneurysms, the combined surgical mortality and morbidity was 3.2%.^[14] They also noted that the outcome was better in young patients and small-sized aneurysm. Hauck *et al.* also reported the favorable outcome of surgical clipping in 21 patients of small basilar tip aneurysm.^[15] We also reported very low morbidity and zero mortality.

After the invention of detachable platinum coils to treat an aneurysm, cerebrovascular neurosurgery practice has

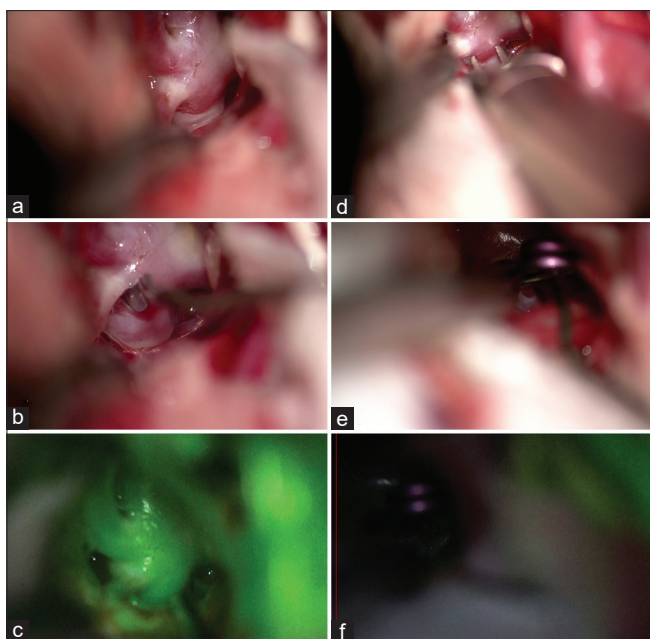


Figure 3: Intraoperative microscopic view. (a) blunt dissection of perforators from the wall of aneurysm; (b) dissected basilar tip aneurysm; (c) dual-image videoangiography used to inspect the sac of aneurysm prior to clip application; (d) application of aneurysmal clip; (e) applied clip over aneurysm; (f) postclipping repeat dual-image videoangiography

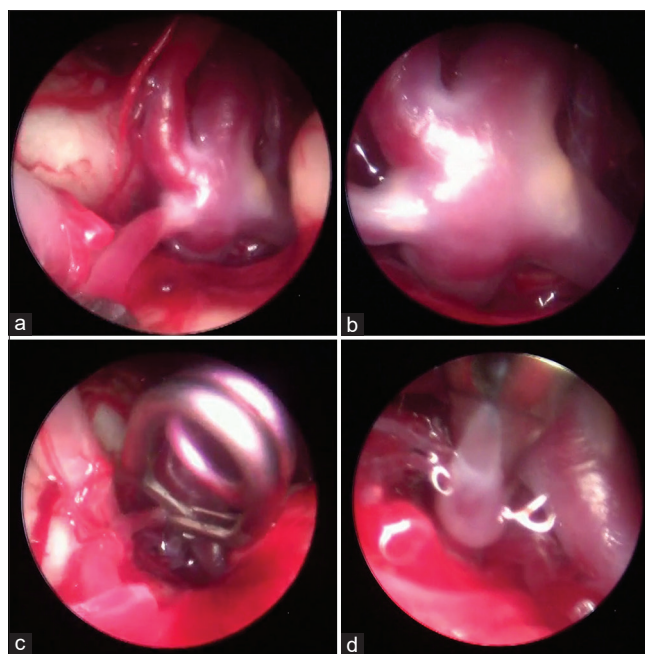


Figure 4: Neuroendoscopic intraoperative view (a) showing basilar tip aneurysm with multiple perforators; (b) aneurysm after dissection of surrounding perforators; (c) clipping of aneurysm sparing perforators; (d) confirming the orientation and position of clip along with clamped aneurysmal sac by clip

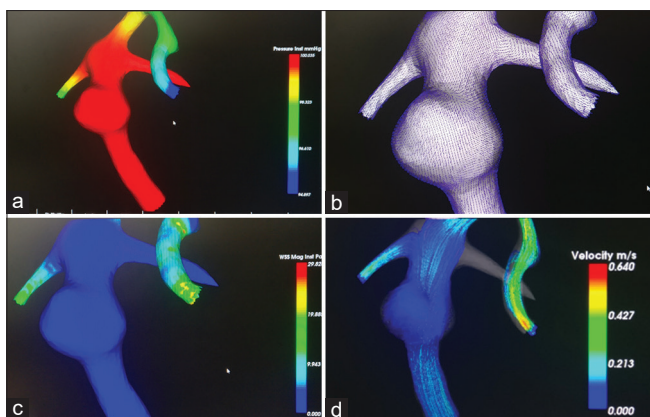


Figure 5: A computational fluid dynamic: (a) high wall pressure within the sac of the basilar trunk aneurysm; (b) wall shear stress vector showing change in the direction of angle of the vectors at the neck of the aneurysm in comparison with the vectors in the main basilar trunk; (c) low wall shear stress pressure within the aneurysmal sac, suggestive of high risk of rupture in the neck; (d) disturbed streamline laminar flow within the sacs

revolutionized.^[16] This evolution was much dramatic, especially for posterior circulation where the surgical morbidities were significant enough. Nowadays, microsurgery is replaced by endovascular therapy and has become a second-line treatment strategy for posterior circulation aneurysm. Several studies have shown low morbidity and mortality with the use of endovascular techniques in posterior circulation aneurysms.^[17-20] Conventional coiling is less effective in a wide neck aneurysm, whereas the balloon-assisted coiling has been described as an important adjuvant in the treatment of these types of aneurysms.^[21] However, despite advancements

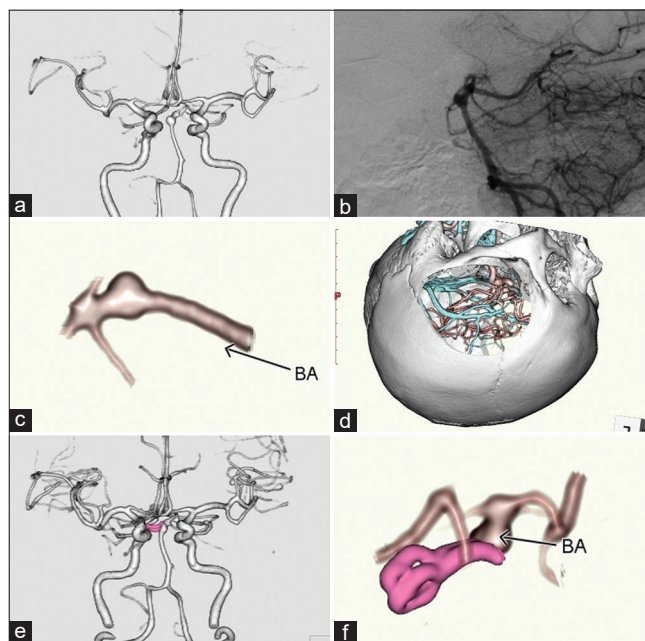


Figure 6: (a) Preoperative three-dimensional computed tomography angiographic anteroposterior view showing basilar trunk aneurysm; (b) lateral view in digital-subtraction angiography; (c) reconstructed isolated image of basilar artery with trunk aneurysm; (d) three-dimensional computed tomography angiography and venography with removal of bone; (e) postoperative three-dimensional computed tomography angiographic image showing clipped basilar trunk aneurysm; (f) three-dimensional computed tomography reconstructed angiographic images of isolated basilar artery with clip on trunk aneurysm

in endovascular techniques, micro neurosurgery is often required where the coiling is not effective/fail or where

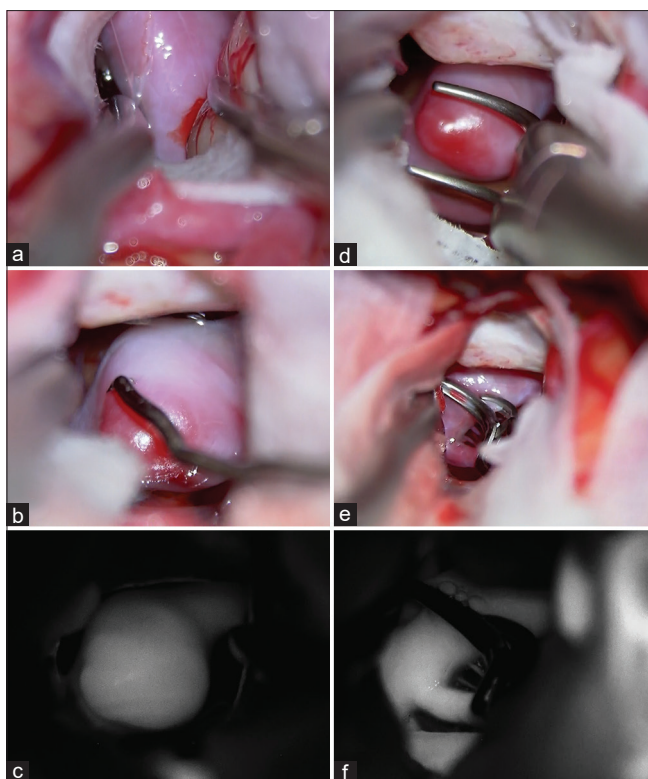


Figure 7: Intraoperative microscopic view. (a) Dissection of perforators attached with the aneurysm; (b) well-isolated basilar trunk aneurysm; (c) intraoperative angiography using indocyanine green used to inspect the sac of aneurysm; (d) applying the clip over the aneurysm; (e) tandem applied clips for complete obscuration of aneurysm; (f) postclipping angiography showing total occlusion of sac of the aneurysm and proper flow in the basilar artery

neck and parent vessel reconstruction is needed. In general, the posterior circulation aneurysms which are difficult to approach as compared to other aneurysms in this region are the basilar trunk, vertebra-basilar junction, proximal anterior inferior cerebellar artery (AICA), and P2 posterior cerebral artery aneurysm.

In preoperative preparation after imaging and CFD, side of approach and type of approach are very important decisions. In general, the parent artery accessibility ahead of aneurysm decides the side of the approach. In the case of midline lesion, if both sides provide equal access to the parent artery, then we prefer the right-sided approach. Regarding the type of approach, one should remember the principles of skull base surgeries. They are the shortest trajectory, bone removal without brain retraction, maximize extradural exposure, and proper arachnoidal dissection of vessels/nerves.

It is not wise to choose the shortest pathway if it causes maximum brain retraction.^[22] Proper bony work is very essential to avoid unnecessary brain retraction such as anterior clinoid drilling in high riding basilar tip aneurysm, posterior clinoid drilling in a low riding basilar tip or basilar trunk aneurysm and jugular tubercle, and occipital condyle drilling in VA-PICA aneurysm. Studies suggest

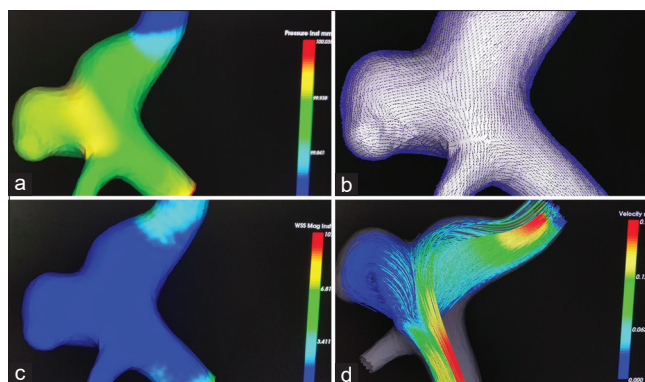


Figure 8: A computational fluid dynamic. (a) Moderate wall pressure within the sac of the vertebral artery-posterior inferior cerebellar artery aneurysm; (b) change in the direction of angle of the vectors at the neck and sac of the aneurysm in comparison with the vectors in the vertebral artery shown by wall shear stress vector; (c) low wall shear stress pressure within the aneurysmal sac; (d) nonlaminar flow within the sac of the aneurysm

that in the case of brain retraction, dynamic brain retraction is better than rigid retraction.^[23] Nowadays, the evolution of highly precise microsurgical instruments and high magnificent microscope allows us to do better arachnoid dissection without damage to brain tissue and neurovascular structures. In our institute, we use very minimal brain retraction by doing adequate bony work, adequate brain relaxation techniques (in terms of neuroanesthesia), proper head and body positioning, cerebrospinal fluid drainage, and good arachnoid dissection. We found no postoperative brain hematoma and contusion.

Surgical approach – there are few points which determine the surgical approach:

- Location of aneurysm along the axis of vertebro-basilar system
- Projection of aneurysm’s fundus
- Surgeon’s preference and experience.

According to the location of the posterior circulation aneurysm, there are several approaches.^[24] Usually, these aneurysms are divided into upper, middle, and lower vertebrobasilar artery aneurysms. For upper part (basilar tip, superior cerebellar artery, posterior cerebellar artery, and upper basilar trunk), pterional, orbitozygomatic, and subtemporal approach; for middle part (mid basilar trunk, AICA), transpetrosal, combined supra-infratentorial and extended middle fossa approach; and for lower part (vertebra basilar junction, PICA), far-lateral, modified far-lateral, and midline suboccipital approach have been described.

In our study, we encountered basilar tip, trunk, and VA-PICA aneurysm, in which we preferred pterional, modified pterional, and far-lateral approach, respectively.

For the management of aneurysm, a preoperative detailed workup is very essential. For screening purposes, CTA gives information on aneurysm location, size, wall characteristics, and association with bone very precisely

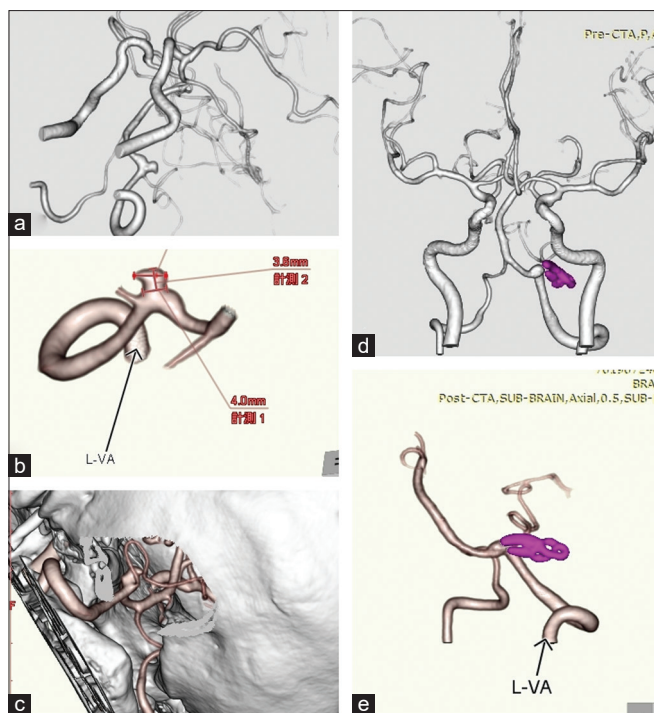


Figure 9: (a) Preoperative three-dimensional computed tomography angiographic oblique lateral view showing aneurysm at vertebral artery-posterior inferior cerebellar artery confluence; (b) reconstructed image of left vertebral artery with aneurysm measurement; (c) three-dimensional computed tomography angiography and venography with removal of bone simulating left transcondylar far-lateral craniotomy; (d) postoperative three-dimensional computed tomography angiographic anteroposterior view; (e) reconstructed isolated view of the left vertebral artery with tandem applied aneurysmal clips and obliterated aneurysm

and without performing invasive technique (DSA), which helps neurosurgeon for planning and approach. CTA data stored in the computer help to make CFD, which helps us to know the characteristics of the aneurysm. CFD tells us the aneurysm wall pressure, wall shear stress, vectors, and streamline flow patterns inside the sac. After correlating these variables, we can assess the tendency of impending rupture.^[25] We can also identify the weak point of the sac wall, which helps us to get the knowledge of intraoperative rupture points.

Nowadays, preoperative simulation is becoming an essential part of preoperative planning. This helps in understanding the 3D anatomy of an aneurysm, parent and branching vessels, bone, and surrounding structures. However, some institutions have intraoperative CT, and they correlate pre- and intraoperative CTA, which can help the neurosurgeons,^[26] but according to the legends of neurosurgery, proper preoperative planning, detailed study of the 3D aneurysm, and detailed knowledge of anatomy are good tools as compared with these recent gadgets. Instead of intraoperative CTA, we use DIVA after injecting intravenous ICG, high-magnification microscope, and endoscope, which allow us to visualize all small perforators and any hidden pathology such as any branch artery surrounding the aneurysm neck.

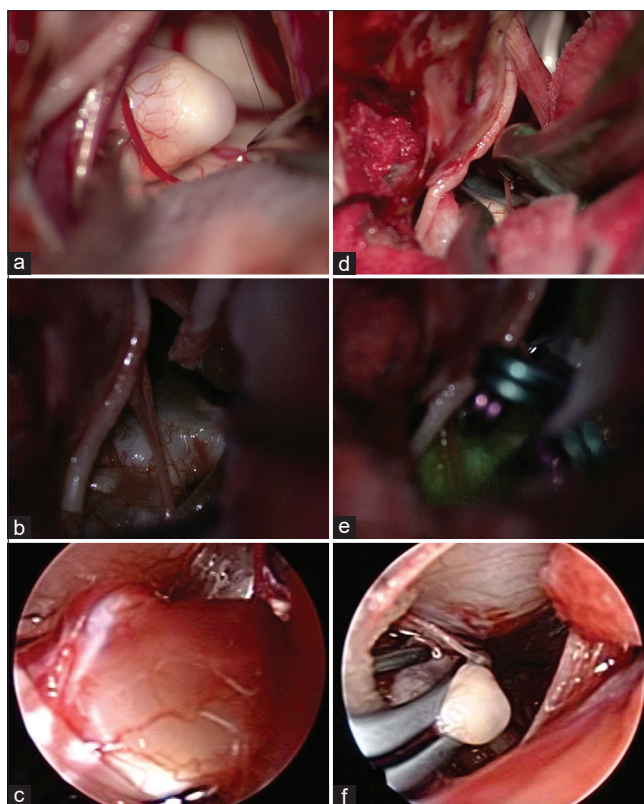


Figure 10: Intraoperative view. (a) Microscopic view showing well-dissected aneurysm at the confluence of vertebral artery and posterior inferior cerebellar artery with perforators around the sac; (b) dual-image videoangiography used to inspect the aneurysmal sac; (c) endoscopic close view of aneurysm with perforators; (d) clip application; (e) postclipping dual-image videoangiography showing the preserved blood flow in the vertebral artery; (f) postclipping endoscopic view showing the position of clip with clamped aneurysmal sac

In basilar tip aneurysm, we sometimes perform anterior clinoidectomy and opening of the dural ring, which helps in the mobilization of ICA. This reduces the retraction of ICA because we prefer the carotid-oculomotor triangle and helps to visualize the aneurysm neck. We did posterior clinoidectomy in three cases because in those patients, basilar tip was located at the lower position and to visualize the neck, all perforators are mandatory while clipping because even small perforator injury can cause disaster.

For VA-PICA aneurysm, we prefer a far-lateral transcondylar approach. Twelve patients of VA-PICA aneurysm underwent clipping and 12 patients underwent trapping of aneurysm, out of which 6 patients underwent bypass. We cannot sacrifice PICA. In the case of hypoplastic opposite VA, in which there is a need for trapping of aneurysm along with PICA, it is an indication of PICA revascularization. We found one case of this kind. Lehto *et al.* also found nine out of seventy aneurysms that were arising from contralateral to hypoplastic VA.^[27] In our series, we found one giant broad neck saccular aneurysm in which PICA was originating from the fundus. The patient presented with a mass effect with facial paresis. There would be high chances of PICA occlusion if the patient

chooses endovascular coiling. To overcome this situation, OA-PICA bypass was a better option. Postoperatively, the same patient developed 9th cranial nerve paresis, which improved with time. Similar transient lower cranial nerve palsy after a far-lateral approach has been reported in some studies.^[28]

In one giant case of VA-PICA, the endovascular coiling was attempted twice but failed, that patient was managed by OA-PICA bypass and trapping. Hence, if the endovascular technique was not able to deal with this type of situation, then the microsurgical technique is the final option. Izumo *et al.* also described their experience of bypass surgery in the failed endovascular procedure.^[29]

Many studies suggest that the complication rate of posterior circulation aneurysm during the endovascular procedure is low^[17-20,30,31] and as well as these procedures also provide less discomfort to patients because in this procedure, open surgery is not required. Still, these procedures constitute some high degree of risk and considered blind procedures. Due to procedural complications, some endovascular specialists have to face medico-legal implications.^[32] The major disadvantage of endovascular procedures with stent-assisted coiling for basilar top aneurysm and trunk aneurysm is the risk of compromising blood flow to brain stem perforators. A study conducted by Richling *et al.* showed that there is a 92% occlusion rate in basilar bifurcation aneurysm size <10 mm, but in aneurysm size of 10 mm or above, the occlusion rate is 61%.^[33]

Mascitelli *et al.* emphasize the need for multimodality approach in the treatment of PICA aneurysms.^[34] Bohnstedt *et al.* also described in their large series of 102 PICA aneurysm that micro neurosurgical treatment was preferred for both saccular and fusiform aneurysms, whereas endovascular intervention was more common for dissecting aneurysms.^[35] Spetzler *et al.* analyzed the 10-year results of the Barrow Ruptured Aneurysm Trial and published that for the saccular posterior circulation aneurysms, clinical outcome after endovascular treatment was better after 1 year, but after 1 year at any follow-up time, there was no statistically significant difference in deaths between two treatment modalities.^[36] In our series of 37 unruptured posterior circulation aneurysms patients, no mortality was reported. Transient oculomotor palsy in two patients of basilar tip aneurysm and transient lower cranial nerve palsy in three patients of VA-PICA aneurysm were found but fully improved over a period of 1 year. This morbidity is much lower than the published series.^[8,37]

Conclusion

As per our experience over a period of 5 years, microsurgical clipping of unruptured posterior circulation aneurysm is safe even though most of the patients in our hospital were elderly patients. There was no mortality and even the transient neurological complications were there

but with no long-term sequel. Intraoperative MEP, SSEP, neuro endoscope, and dual-image videoangiography are important during surgery; these modalities improve the safety profile of microsurgical clipping. These modalities also help us to avoid complications (perforator injury, brain stem handling). Hence, under the experienced hands, microsurgical management of most of the unruptured posterior circulation aneurysm is safe with low risk of mortality and morbidity.

Financial support and sponsorship

Nil.

Conflicts of interest

There are no conflicts of interest.

References

1. Ishibashi T, Murayama Y, Urashima M, Saguchi T, Ebara M, Arakawa H, *et al.* Unruptured intracranial aneurysms: Incidence of rupture and risk factors. *Stroke* 2009;40:313-6.
2. Schievink WI. Intracranial aneurysms. *N Engl J Med* 1997;336:28-40.
3. Wiebers DO, Whisnant JP, Huston J 3rd, Meissner I, Brown RD Jr., Piepgras DG, *et al.* Unruptured intracranial aneurysms: Natural history, clinical outcome, and risks of surgical and endovascular treatment. *Lancet* 2003;362:103-10.
4. Molyneux A, Kerr R, Stratton I, Sandercock P, Clarke M, Shrimpton J, *et al.* International subarachnoid aneurysm trial (ISAT) of neurosurgical clipping versus endovascular coiling in 2143 patients with ruptured intracranial aneurysms: A randomised trial. *Lancet* 2002;360:1267-74.
5. Musara A, Yamada Y, Takizawa K, Seng LB, Kawase T, Miyatani K, *et al.* Anterior temporal approach and clipping of a high-riding basilar tip aneurysm: Case report and review of the surgical technique. *Asian J Neurosurg* 2019;14:1283-7.
6. Shibani E, Török E, Wostrack M, Meyer B, Lehmburg J. The far-lateral approach: Destruction of the condyle does not necessarily result in clinically evident craniovertebral junction instability. *JNS* 2016;125:196-201.
7. Brisman JL, Song JK, Newell DW. Cerebral aneurysms. *N Engl J Med* 2006;355:928-39.
8. Pahl FH, Oliveira MF, Rotta JM. Microsurgical treatment of basilar tip aneurysms: Is it still acceptable? *Arq Neuropsiquiatr* 2017;75:697-702.
9. Kleinpeter G. Why are aneurysms of the posterior inferior cerebellar artery so unique? Clinical experience and review of the literature. *Minim Invasive Neurosurg* 2004;47:93-101.
10. Rinkel GJ, Djibuti M, Algra A, van Gijn J. Prevalence and risk of rupture of intracranial aneurysms: A systematic review. *Stroke* 1998;29:251-6.
11. de Rooij NK, Linn FH, van der Plas JA, Algra A, Rinkel GJ. Incidence of subarachnoid haemorrhage: A systematic review with emphasis on region, age, gender and time trends. *J Neurol Neurosurg Psychiatry* 2007;78:1365-72.
12. Morita A, Kirino T, Hashi K, Aoki N, Fukuhara S, Hashimoto N, *et al.* UCAS Japan Investigators. The natural course of unruptured cerebral aneurysms in a Japanese cohort. *N Engl J Med* 2012;366:2474-82.
13. Raaymakers TW, Rinkel GJ, Limburg M, Algra A. Mortality and morbidity of surgery for unruptured intracranial aneurysms: A meta-analysis. *Stroke* 1998;29:1531-8.

14. Eftekhar B, Morgan MK. Preoperative factors affecting the outcome of unruptured posterior circulation aneurysm surgery. *J Clin Neurosci* 2011;18:85-9.
15. Hauck EF, White JA, Samson D. The small "surgical aneurysm" at the basilar apex. *J Neurosurg* 2010;112:1216-21.
16. Guglielmi G, Viñuela F, Duckwiler G, Dion J, Lylyk P, Berenstein A, *et al.* Endovascular treatment of posterior circulation aneurysms by electrothrombosis using electrically detachable coils. *J Neurosurg* 1992;77:515-24.
17. Tateshima S, Murayama Y, Gobin YP, Duckwiler GR, Guglielmi G, Viñuela F. Endovascular treatment of basilar tip aneurysms using Guglielmi detachable coils: Anatomic and clinical outcomes in 73 patients from a single institution. *Neurosurgery* 2000;47:1332-9.
18. Birchall D, Khangure M, McAuliffe W, Apsimon H, Knuckey N. Endovascular treatment of posterior circulation aneurysms. *Br J Neurosurg* 2001;15:39-43.
19. Uda K, Murayama Y, Gobin YP, Duckwiler GR, Viñuela F. Endovascular treatment of basilar artery trunk aneurysms with Guglielmi detachable coils: Clinical experience with 41 aneurysms in 39 patients. *J Neurosurg* 2001;95:624-32.
20. Pandey AS, Koebbe C, Rosenwasser RH, Veznedaroglu E. Endovascular coil embolization of ruptured and unruptured posterior circulation aneurysms: Review of a 10-year experience. *Neurosurgery* 2007;60:626-36.
21. Cottier JP, Pasco A, Gallas S, Gabrillargues J, Cognard C, Drouineau J, *et al.* Utility of balloon-assisted Guglielmi detachable coiling in the treatment of 49 cerebral aneurysms: A retrospective, multicenter study. *AJNR Am J Neuroradiol* 2001;22:345-51.
22. Nakov VS, Spiriev TY, Todorov IT, Simeonov P. Technical nuances of subtemporal approach for the treatment of basilar tip aneurysm. *Surg Neurol Int* 2017;8:15.
23. Darsaut TE, Fahed R, Macdonald RL, Arthur AS, Kalani MY, Arikani F, *et al.* Surgical or endovascular management of ruptured intracranial aneurysms: An agreement study. *J Neurosurg* 2018;131:25-31.
24. Peerless SJ, Drake CG. Posterior circulation aneurysms. In: Suzuki J, editor. *Advances in Surgery for Cerebral Stroke*. Tokyo: Springer Japan; 1988. p. 53-6.
25. Xiang J, Tutino VM, Snyder KV, Meng H. CFD: Computational fluid dynamics or confounding factor dissemination? The role of hemodynamics in intracranial aneurysm rupture risk assessment. *AJNR Am J Neuroradiol* 2014;35:1849-57.
26. Carl B, Bopp M, Chehab S, Bien S, Nimsky C. Preoperative 3-dimensional angiography data and intraoperative real-time vascular data integrated in microscope-based navigation by automatic patient registration applying intraoperative computed tomography. *World Neurosurg* 2018;113:e414-25.
27. Lehto H, Kivisaari R, Niemelä M, Dashti R, Elsharkawy A, Harati A, *et al.* Seventy aneurysms of the posterior inferior cerebellar artery: Anatomical features and value of computed tomography angiography in microneurosurgery. *World Neurosurg* 2014;82:1106-12.
28. Liew D, Ng PY, Ng I. Surgical management of ruptured and unruptured symptomatic posterior inferior cerebellar artery aneurysms. *Br J Neurosurg* 2004;18:608-12.
29. Izumo T, Matsuo T, Morofuji Y, Hiu T, Horie N, Hayashi K, *et al.* Microsurgical clipping for recurrent aneurysms after initial endovascular coil embolization. *World Neurosurg* 2015;83:211-8.
30. Peluso JP, van Rooij WJ, Sluzewski M, Beute GN. Coiling of basilar tip aneurysms: Results in 154 consecutive patients with emphasis on recurrent haemorrhage and re-treatment during mid- and long-term follow-up. *J Neurol Neurosurg Psychiatry* 2008;79:706-11.
31. Chalouhi N, Jabbour P, Gonzalez LF, Dumont AS, Rosenwasser R, Starke RM, *et al.* Safety and efficacy of endovascular treatment of basilar tip aneurysms by coiling with and without stent assistance: A review of 235 cases. *Neurosurgery* 2012;71:785-94.
32. Lee KS, Shim JJ, Shim JH, Oh JS, Yoon SM. Cerebral aneurysms in judicial precedents. *J Korean Neurosurg Soc* 2018;61:474-7.
33. Richling B, Gruber A, Killer M, Bavinzski G. Treatment of ruptured saccular intracranial aneurysms by microsurgery and electrolytically detachable coils: Evaluation of outcome and long-term follow-up. *Oper Tech Neurosurg* 2000;3:282-99.
34. Mascitelli JR, Yaeger K, Wei D, Kellner CP, Oxley TJ, de Leacy RA, *et al.* Multimodality treatment of posterior inferior cerebellar artery aneurysms. *World Neurosurg* 2017;106:493-503.
35. Bohnstedt BN, Ziemba-Davis M, Edwards G, Brom J, Payner TD, Leipzig TJ, *et al.* Treatment and outcomes among 102 posterior inferior cerebellar artery aneurysms: A comparison of endovascular and microsurgical clip ligation. *World Neurosurg* 2015;83:784-93.
36. Spetzler RF, McDougall CG, Zabramski JM, Albuquerque FC, Hills NK, Nakaji P, *et al.* Ten-year analysis of saccular aneurysms in the barrow ruptured aneurysm trial. *J Neurosurg* 2019;132:771-6.
37. Lai L, Morgan MK. Surgical management of posterior circulation aneurysms: defining the role of microsurgery in contemporary endovascular era. In Signorelli F, editor, *Explicative cases of controversial issues in neurosurgery*. Rijeka, Croatia: InTech. 2012. p. 235-256.