

# Thoracic Spinal Intramedullary Arachnoid Cyst Presented with Myelopathy with Marked Postoperative Improvement: A Case Report and Review of Literature

## Abstract

Intramedullary spinal cord arachnoid cysts are rare. So, we present an interesting case of adult male presented with myelopathic symptoms and signs. Further investigations revealed a finding of thoracic intramedullary cystic lesion, found postoperatively to be an arachnoid cyst. Patient improved remarkably postoperative and during follow up period.

**Keywords:** *Arachnoid cyst, intramedullary, spinal cord*

## Introduction

Intramedullary spinal cord tumors represent about 5% of all spinal cord tumors.<sup>[1]</sup> The most common types described are astrocytoma and ependymoma. Arachnoid cyst represents a rare entity, especially in the thoracic area. They are mostly extradural and asymptomatic, though sometimes can be intradural extramedullary. Pediatric age groups develop arachnoid cyst more frequently either congenital, posttraumatic, postinfectious, secondary to kyphoscoliosis, or spinal dysraphism.<sup>[1]</sup> Based on our literature review, only nine cases were reported in the pediatric age groups<sup>[2-9]</sup> and eight cases in the adult age groups.<sup>[5,10-16]</sup> Here, we present an interesting case of thoracic intramedullary spinal tumor in an adult patient presenting with myelopathic symptoms and signs with marked regression of the cyst and remarkable clinical improvement early postoperatively and during follow-up.

## History of Presenting Illness

A 31-year-old male presented to our clinic complaining of heaviness and vague sensation in his lower limbs and lower part of his trunk, slowly progressive over 2-year duration.

Three months before his presentation, he experienced back pain and difficulties in passing urine (weak stream) and

constipation which was progressing. On further questioning, the patient also mentioned recent history of impotence and frequent falls while walking.

## Clinical examination

The clinical examination showed he was fully awake; moving all his limbs; mild spasticity in both the lower limbs; unstable gait; sensory level in the form of bilateral hypoesthesia from D6 down below; motor power in both the lower limbs was 4/5 in all muscle groups, with well-sustained bilateral clonus; exaggerated deep jerk reflexes all over the lower limbs; and intact anal tone.

## Imaging

Whole spine X-ray showed mild thoracic and mild thoracolumbar scoliosis with convexity toward the left at the midthoracic region (mild thoracic levoscoliosis) and to the right at the upper lumbar region (mild lumbar dextroscoliosis) [Figure 1].

Magnetic resonance imaging spine showed midthoracic intramedullary cystic lesion (2.5 cm), extending along T6, T7, and T8 level with 9.5 mm width. Of note, secondary developed syrinx at the lower part of the lesion corresponding to T8–T9 level. The lesion was hypointense on T1 and hyperintense on T2-weighted sequence. Postcontrast sequence showed no enhancement [Figure 2].

**Ahmed Shaaban,  
Amrou  
Abdelrahman,  
Raed Abu Jarir,  
Issam Al-Bozom<sup>1</sup>,  
Ali Raza**

*Departments of Neurosurgery  
and <sup>1</sup>Pathology, Hamad General  
Hospital, Doha, Qatar*

*Address for correspondence:  
Dr. Ali Raza,  
Department of Neurosurgery,  
Hamad General Hospital,  
Al Rayyan Road, P. O.  
Box 3050, Doha, Qatar.  
E-mail: aali6@hamad.qa*

## Access this article online

**Website:** [www.asianjns.org](http://www.asianjns.org)

**DOI:** 10.4103/ajns.AJNS\_72\_19

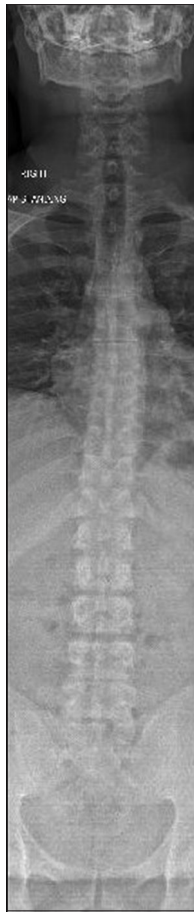## Quick Response Code:



**How to cite this article:** Shaaban A, Abdelrahman A, Jarir RA, Al-Bozom I, Raza A. Thoracic spinal intramedullary arachnoid cyst presented with myelopathy with marked postoperative improvement: A case report and review of literature. *Asian J Neurosurg* 2019;14:981-4.

This is an open access journal, and articles are distributed under the terms of the Creative Commons Attribution-NonCommercial-ShareAlike 4.0 License, which allows others to remix, tweak, and build upon the work non-commercially, as long as appropriate credit is given and the new creations are licensed under the identical terms.

**For reprints contact:** [reprints@medknow.com](mailto:reprints@medknow.com)



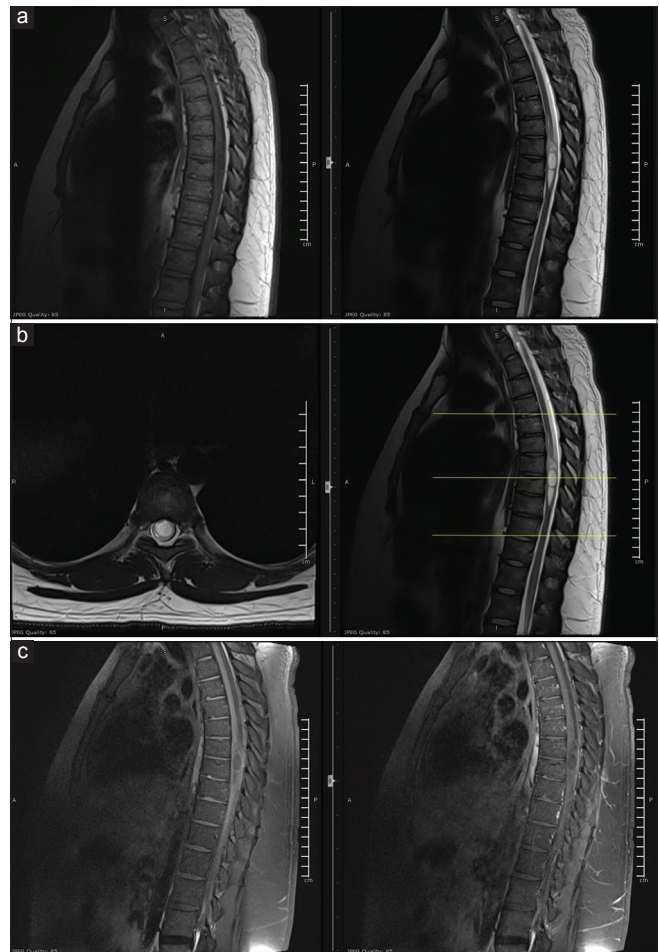
**Figure 1:** Whole spine X-ray showing mild thoracic and mild thoracolumbar scoliosis with convexity toward the left at the midthoracic region (mild thoracic levoscoliosis) and to the right at the upper lumbar region (mild lumbar dextroscoliosis)

### Hospital course

Urodynamic testing was done on outpatient department basis, showing obstructive void pattern with normal detrusor pressure, which could be related to the spinal lesion. The patient was then electively admitted for surgery.

### Operation

- The patient underwent D6–D8 laminectomy
- The dura was then opened longitudinally in the midline. Abnormally thickened arachnoid was encountered which was carefully dissected
- Abnormal-looking area was noted at the upper part of the dural opening; after arachnoidal adhesions were divided, the cord was spotted to be extremely swollen and protruding out
- An abnormal grayish area was seen on the right side of the cord which was also adherent to arachnoid
- Multiple biopsies of this lesion were done
- This was not separable from the cord and medially there was no clear boundary between the lesion and the cord; hence, it was not attempted for complete excision
- After taking biopsy, midline myelotomy for about 1 cm was carried out distal to lesion by a sharp knife



**Figure 2:** (a) Magnetic resonance imaging T1 and T2 sagittal. (b) Magnetic resonance imaging T2 axial and T2 Sagittal. (c) T1 sagittal pre- and postcontrast gadolinium-based enhancement

followed by micro dissector and fine forceps dissection down the midline

- A larger syrinx was entered and was decompressed
- Soon after the cord appeared to be lax and pulsating
- Hemostasis was secured, and the dura was closed using running stitches
- Valsalva was done to confirm no cerebrospinal fluid leakage
- DuraGen was applied and then tisseal was overlaid the dura. Wound was closed in layers in standard fashion.

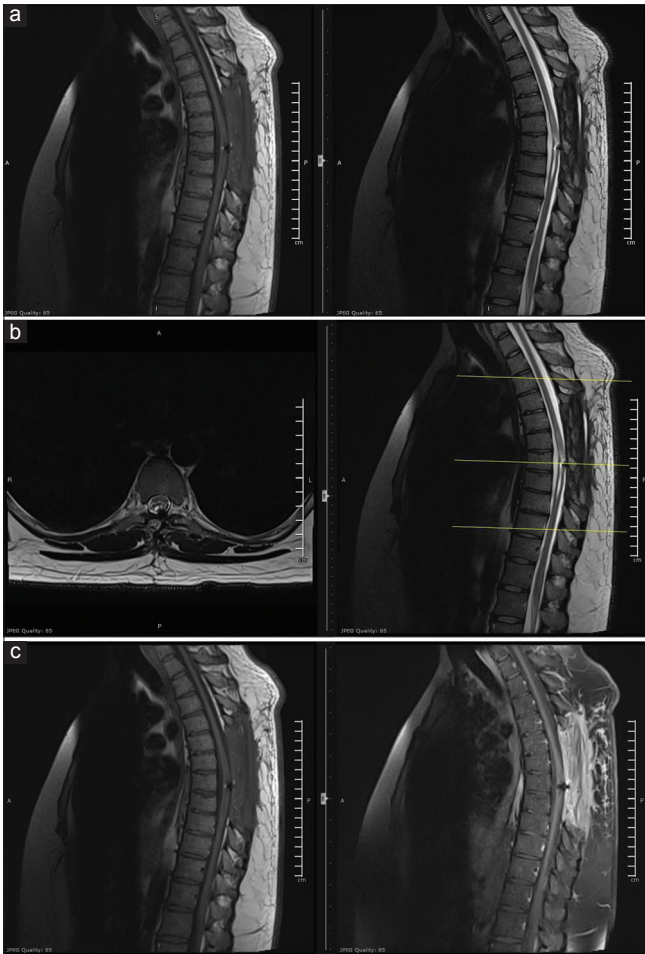
### Surgical pathology

Arachnoid cyst [Figure 4].

### Postoperative course

In postoperative period during his stay in the hospital, there was clinical improvement in his gait and motor power.

The Patient was then transferred to the rehabilitation unit for intensive rehabilitation, and he was able to ambulate independently and to control his bowel/bladder with subtle residual spasticity. Sensation was same as preoperative status, which improved after few weeks.



**Figure 3:** (a) Magnetic resonance imaging T1 and T2 sagittal postoperative. (b) T2 axial and sagittal postoperative. (c) T1 sagittal pre- and postcontrast gadolinium-based postoperative

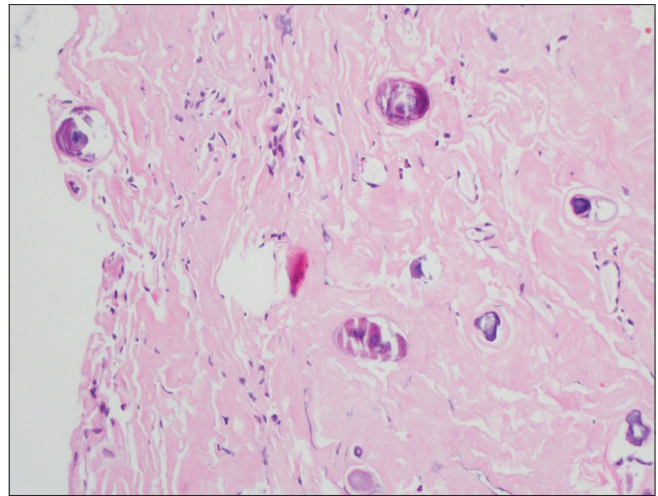
MRI about 3 months postoperative showed postoperative changes with regression of intramedullary cystic lesion [Figure 3]

### Follow-up

The patient was seen in the clinic 50 days after discharge from the hospital and he reported dramatic improvement in the radicular pain, erectile dysfunction, and lower limb weakness.

### Discussion

Arachnoid cyst is a rare presentation of spinal cord tumors. Even when found, they are mostly extradural or intradural extramedullary. Extradural cysts usually originate from arachnoid herniation, but intradural cysts originate from arachnoid trabeculations. Intramedullary arachnoid cysts are very rare and their origin, risk factors still not well understood.<sup>[14]</sup> Most of the cases reported in the literature are mainly pediatric with some reported cases in adults. Hence, this may explain the relations of intramedullary arachnoid cyst to genetic factors or developmental anomalies. A case reported discussing the association of intramedullary



**Figure 4:** Microscopic view showing a thickened cyst wall containing numerous psammomatous calcifications and has flat lining (H and E, ×200). Pathological examination of the tissue revealed a cyst with thickened fibrous wall that contains numerous psammomatous calcifications and has flat denuded lining. Immunohistochemistry was performed and showed the flat lining to be positive with EMA while negative with S100, GFAP, and cytokeratin cocktail

arachnoid cyst with cervical myelopathy which may play a role in its pathogenesis.<sup>[15]</sup> Although most arachnoid cysts are asymptomatic, our case presented with myelopathic symptoms which improved postoperatively.

Some research studies appeared recently investigating the surgical outcome of arachnoid cyst and showed that their results are promising. Most patients show marked improvement which may change the surgeon's decision to operate on spinal arachnoid cysts even if asymptomatic to decrease risk of myelopathy.<sup>[17]</sup>

### Conclusion

We recommend surgery for symptomatic arachnoid cysts and those asymptomatic cysts that appear to have progressive overt clinical impairment on follow-up. We should discuss with our patients the future risk of myelopathy and the need for surgery at any point once the asymptomatic cyst started to have neurological impairment. Furthermore, more research is needed to address the risk factors associated with this type of cysts and less invasive surgical techniques to be developed.

### Declaration of patient consent

The authors certify that they have obtained all appropriate patient consent forms. In the form the patient(s) has/have given his/her/their consent for his/her/their images and other clinical information to be reported in the journal. The patients understand that their names and initials will not be published and due efforts will be made to conceal their identity, but anonymity cannot be guaranteed.

### Financial support and sponsorship

Nil.



## Conflicts of interest

There are no conflicts of interest.

## References

- Greenberg MS. Handbook of Neurosurgery. 8<sup>th</sup> ed. New York: Thieme; 2016. p. 1661.
- Aithala GR, Sztriha L, Amirlak I, Devadas K, Ohlsson I. Spinal arachnoid cyst with weakness in the limbs and abdominal pain. *Pediatr Neurol* 1999;20:155-6.
- Ghannane H, Haddi M, Aniba K, Lmejjati M, Ait Benali S. Symptomatic intramedullary arachnoid cyst. Report of two cases and literature review. *Neurochirurgie* 2007;53:54-7.
- Guzel A, Tatli M, Yilmaz F, Bavbek M. Unusual presentation of cervical spinal intramedullary arachnoid cyst in childhood: Case report and review of the literature. *Pediatr Neurosurg* 2007;43:50-3.
- Kataria R, Sinha VD, Chopra S. Intramedullary arachnoid cyst: Report of two cases. *Neurol India* 2012;60:123-4.
- Lmejjati M, Aniba K, Haddi M, Hakkou M, Ghannane H, Ait Ben Ali S. Spinal intramedullary arachnoid cyst in children. *Pediatr Neurosurg* 2008;44:243-6.
- Medved F, Seiz M, Baur MO, Neumaier-Probst E, Tuettenberg J. Thoracic intramedullary arachnoid cyst in an infant. *J Neurosurg Pediatr* 2009;3:132-6.
- Sharma A, Karande S, Sayal P, Ranadive N, Dwivedi N. Spinal intramedullary arachnoid cyst in a 4-year-old girl: A rare cause of treatable acute quadriplegia: Case report. *J Neurosurg* 2005;102:403-6.
- Sharma A, Sayal P, Badhe P, Pandey A, Diyora B, Ingale H. Spinal intramedullary arachnoid cyst. *Indian J Pediatr* 2004;71:e65-7.
- Alugolu R, Arradi V, Sahu BP. Intramedullary arachnoid cyst in an adult: Case report and review. *Asian J Neurosurg* 2016;11:70.
- Diyora B, Kamble H, Nayak N, Dugad P, Sharma A. Thoracic intramedullary arachnoid cyst. *Neurol India* 2010;58:964-6.
- Gezici AR, Ergün R. Intramedullary arachnoid cyst: 3-year follow up after bilateral dorsal root entry zone myelotomy. *Acta Neurochir (Wien)* 2008;150:595-7.
- Goyal A, Singh AK, Singh D, Gupta V, Tatke M, Sinha S, *et al.* Intramedullary arachnoid cyst. Case report. *J Neurosurg* 2002;96:104-6.
- Novegno F, Umana G, Di Muro L, Fraioli B, Fraioli MF. Spinal intramedullary arachnoid cyst: Case report and literature review. *Spine J* 2014;14:e9-15.
- Rahimizadeh A, Soufiani H. Intramedullary arachnoid cyst in association with cervical spondylosis: Case report. *Spine J* 2013;13:e21-5.
- Willems PW, van den Bergh WM, Vandertop WP. An arachnoid cyst presenting as an intramedullary tumour. *J Neurol Neurosurg Psychiatry* 2000;68:508-10.
- Garg K, Borkar SA, Kale SS, Sharma BS. Spinal arachnoid cysts – Our experience and review of literature. *Br J Neurosurg* 2017;31:172-8.