

Surgical Management of Spinal Tuberculosis – A Retrospective Observational Study from a Tertiary Care Center in Karnataka

Abstract

Context: Tuberculosis (TB) is a common infectious disorder in developing countries. A significant load of patients with extrapulmonary TB are diagnosed in our institute, mostly involving the spine. **Aim:** We aimed to present our experience in the surgical management of spinal TB. **Setting and Design:** This was a retrospective observational study. **Materials and Methods:** Seventy patients (year 2016–2018) who underwent surgical management with minimum of 1-year follow-up (17 patients lost during follow-up) were graded as per the American Spinal Injury Association (ASIA) grading system for neurological deficits. All were surgically treated with laminectomy and epidural abscess drainage/transpedicular debridement of granulation with/without spinal stabilization. Thoracic and lumbar cases were managed by posterior approach; among them, 12 patients who had no significant cord compression and good ASIA grade with facet involvement (requiring fusion) underwent minimally invasive pedicle screw fixation. Cervical cases were managed mostly by anterior approach. All patients received Anti-tubercular treatment (ATT) post operatively as per protocol postoperatively, following which magnetic resonance imaging (MRI) spine was done. **Statistical Analysis:** Data were analyzed using SPSS software version 18.0 (SPSS Inc. Released in 2009. PASW Statistics for Windows, version 18.0. Chicago, IL, USA: SPSS Inc.). The continuous variables were analyzed using descriptive statistics using mean and standard deviation. **Results:** The average age was 42.5 years. The most common location was thoracic (28 patients), followed by lumbar (20 patients), cervical (16 patients), and thoracolumbar (6 patients). Twenty patients had epidural abscess with cord compression. All patients who presented within 4 weeks of onset of symptoms showed a statistically significant improvement postsurgery. Sixteen patients with epidural abscess had good neurological recovery immediately after surgery (ASIA B to ASIA D/E). Four patients with epidural abscess with late presentation remained ASIA A after surgery. All patients had good fusion rates (follow-up X-ray) at 1 year. After ATT course completion, all patients had complete eradication of disease (MRI spine). **Conclusion:** Surgical treatment for spinal TB, if performed early (within 4 weeks) with good decompression, results in satisfactory clinical outcome with early improvement in the neurological deficits. Posterior approach to the spine with decompression and fixation gives good results, and minimally invasive procedures further help lessen muscle dissection, less pain, and early mobilization.

Keywords: Early surgical management, minimally invasive surgery, posterior approach, tuberculosis of spine

Introduction

Tuberculosis (TB) is a disease of the low socioeconomic group with occurrence more common in developing countries, but incidence of the disease is found to be increasing in developed countries, probably due to growing number of immunocompromised individuals and the increasing number of immigrants arriving from endemic areas.^[1] India has the highest TB burden in the world having an estimated incidence of 2.69 million cases

in 2019.^[2] Spinal TB occurs in fewer than 1% of patients with TB.^[3-5] However, spinal TB accounts for 40%–50% of all spinal infection.^[4,5] Spine TB accounts for 50% of the cases of extrapulmonary musculoskeletal TB.^[3,4] Spinal TB continues to be a burden in developing countries, contributing to deformity and neurological deficit. Surgery is reserved for patients with mechanical instability or neurological deficits.^[3] The first documented case of spinal TB dates back to

This is an open access journal, and articles are distributed under the terms of the Creative Commons Attribution-NonCommercial-ShareAlike 4.0 License, which allows others to remix, tweak, and build upon the work non-commercially, as long as appropriate credit is given and the new creations are licensed under the identical terms.

For reprints contact: WKHLRPMedknow_reprints@wolterskluwer.com

How to cite this article: Srinivasa R, Furtado SV, Kunikullaya KU, Biradar S, Jayakumar D, Basu E. Surgical management of spinal tuberculosis – A retrospective observational study from a Tertiary Care Center in Karnataka. *Asian J Neurosurg* 2021;16:695-700.

Submitted: 22-Feb-2021 **Revised:** 14-May-2021
Accepted: 13-Jun-2021 **Published:** 24-Sep-2021

Rakshith Srinivasa, Sunil Valentine Furtado, Kirthana Ubrangala Kunikullaya¹, Sangeeta Biradar, Dravya Jayakumar², Eilene Basu²

*Department of Neurosurgery,
¹Departments of Physiology,
²Medical student, M S Ramaiah
Medical College and Hospital,
Bengaluru, Karnataka, India*

Address for correspondence:
Dr. Sunil Valentine Furtado,
Department of Neurosurgery,
M.S. Ramaiah Memorial
Hospital, Bengaluru - 560 054,
Karnataka, India.
E-mail: sunilvf@gmail.com

Access this article online

Website: www.asianjns.org

DOI: 10.4103/ajns.AJNS_78_21

Quick Response Code:



5000 years, recognized in Egyptian mummies. However, the first modern case of spinal TB was described by Percival Pott in the year 1779. TB spine usually affects the intervertebral disc and the adjacent vertebral bodies, “paradiscal” area. Involvement of posterior elements is rare. The thoracic spine is most affected followed by the lumbar and cervical spine. Neurological complications are the most crippling complications of spinal TB with the incidence ranging from 10% to 43% in various reports.^[6,7] The kyphotic deformity, paravertebral abscess, or progression to neurological deformity are the most difficult complications of spine TB. Epidural abscess with cord compression is the most common cause of neurological deficits. The cardinal symptoms of TB, fever, chills, loss of weight, and decreased appetite are not commonly seen in patients with spinal TB, and diagnosis is therefore based on clinical suspicion. With advanced imaging techniques such as magnetic resonance imaging (MRI),^[8] many cases of spinal TB are diagnosed earlier and are treated before they develop significant neurological deficits. Unfortunately, we still see a significant number of patients presenting late after disease onset with severe neurological dysfunction. The frequent absence of concurrent pulmonary involvement and the health-care personnel’s lack of familiarity with the disease in developed countries, poses a significant challenge in the diagnosis of TB.^[9] Blood investigations are of only limited value in the form of raised erythrocyte sedimentation rate (ESR) and lymphocyte count. The definitive diagnosis can be made by identification of mycobacterium TB in the biopsy specimen.^[8,9]

Antitubercular drugs are the gold standard for the treatment of TB in cases without spinal deformity or neurological impairment and are the first choice of treatment often resulting in fusion in 80% of cases.^[10] The indication for surgery in patients with tuberculosis of the spine are severe spinal deformity, spinal instability, neurological deficits, presence of large tubercular abscess either para spinal or epidural and failure of response to anti-tubercular drugs.^[11-13] The approach for the surgery can be anterior, posterior, combined, or posterolateral with promising results with posterior or combined approaches. Further, early recognition and surgical management is recommended in order to prevent morbidity, in the form of neurological deficit or spinal deformity.^[14] In this article, we discuss our institutional experience with the surgical management of spinal TB and also would like to emphasize that early presentation and surgery would significantly influence neurological recovery.

Materials and Methods

The study design was a retrospective nonrandomized interventional design. We studied all the patients with spinal TB who presented with or without motor deficits due to spinal TB admitted and surgically treated in the department of neurosurgery at a tertiary care center in Bengaluru, Karnataka, over a duration of 2 years (2016–2018).

The medical records were retrieved from our database, and the clinical presentation, any family history or history of exposure, clinical examination notes, imaging, histopathological report, and follow-up data (Only those data of patients who had completed 1 year follow up were included in this study and analysed) were analyzed. Cases in which the follow-up period was shorter than 12 months were considered as lost to follow-up and excluded. A total of 87 patients’ data were retrieved from the database, out of which 17 patients did not fulfill the follow-up criteria. Hence, 70 patients were included in the final analysis. We considered early presentation for those patients presenting within 4 weeks of onset of symptoms. The study was approved by the local institutional ethical review board. A written informed consent was obtained from all the patients for publication of data for academic purposes.

Preoperative evaluation

All patients underwent neurological impairment grading according to the American Spinal Association Impairment Scale (ASIA) of motor and sensory impairments ranging from A to E,^[11] ranging from no motor and sensory function to normal function: Grade A – complete loss of motor and sensory function, Grade B – sensory incomplete, Grade C – motor incomplete with less than half of key muscle functions below the single neurological level having a Muscle grade > or = 3 (greater than or equal to 3), Grade D – motor incomplete with at least half (half or more) of key muscle functions below the single neurological level having a muscle grade g3, and Grade – E normal motor and sensory function. ASIA Grades A, B, and C were considered severe.

All the patients in the study had undergone following investigations: MRI spine with gadolinium (to identify involved spinal level, presence of para spinal or epidural abscess and to assess the extent of spinal cord compression and to also assess the posterior elements, facet joint involvement). X ray spine (lateral view, anterior-posterior view and dynamic flexion-extension view)-to assess for mobility to rule out spondylolisthesis of the involved level. Routine pre-operative blood investigation including ESR.

Surgical procedure

All surgical procedures were performed by a single team of neurosurgeons (2 per team), who were consistently involved in patient selection and surgical intervention. This ensured uniformity of inclusion of patients and the procedures followed. The patients underwent surgical procedures based on the presence of epidural abscess/granulation tissue with cord compression, neurological impairment, vertebral body destruction, facet destruction, and spine instability. All the patients with thoracic or lumbar TB in the current study underwent surgery by posterior approach with fusion using the titanium implants (Jayon Implants Private Limited, India) for spinal instability. Twenty patients

underwent emergency laminectomy and decompression for the epidural collection. In the thoracic and lumbar group, 42 out of 54 patients underwent open procedure, midline incision, subperiosteal paraspinal muscle dissection at the involved level and two levels above and below, laminectomy at the involved level with abscess drainage, and/or debridement of granulation tissue and pedicle screw fixation [Figure 1]. Twelve out of 54 patients, with no significant thecal compression, but involvement of facets requiring stabilization, underwent minimally invasive pedicle screw fixation and transpedicular decompression/biopsy, and in those patients where extensive vertebral body involvement was seen, initially minimally invasive pedicle screw insertion in two levels above and below the involved vertebra was done [Figure 1]. In patients with involvement of a single level with paradiscal and posterior element involvement with significant epidural collection, the surgical option is laminectomy and decompression of epidural abscess with pedicle screw stabilisation two levels above and two level below the involved segment. For example, if L1-2 vertebral level is involved, patient will require L1 and L2 Laminectomy and epidural abscess drainage and decompression and pedicle screw D11 and D12 and L3 and L4 level. If we consider open technique, then midline incision from D10-L5 is required with extensive subperiosteal muscle dissection, instead we perform minimal invasive pedicle screw fixation with percutaneous rod placement and make a small incision at level L1-L2 subperiosteal muscle dissection only at that level and perform Laminectomy at L1 and L2 and abscess

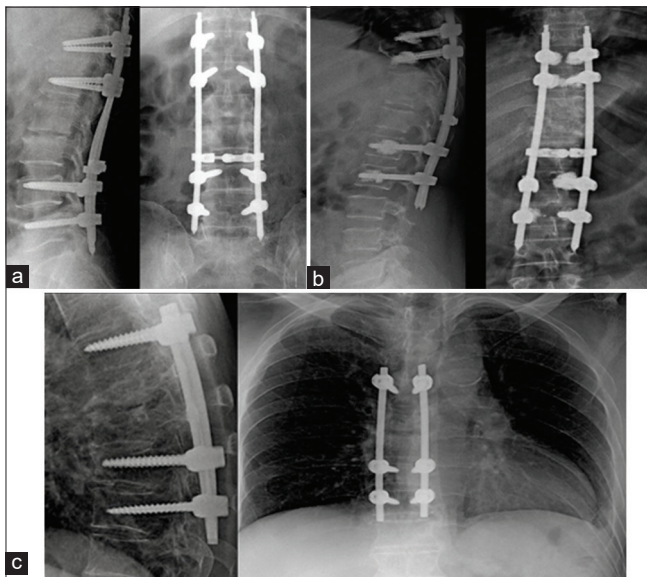


Figure 1: (a) post- opt X-ray Dorso-lateral spine- lateral and antero-posterior view- thoracolumbar minimal invasive pedicle screw with rods. The separate small midline incision at the level of involvement allowed us to perform laminectomy, decompression and horizontal connecting rod placement. (b) post- opt X- ray Dorso-lateral spine- lateral and antero-posterior view- thoracolumbar minimal invasive pedicle screw with bone cement augmentation for a patient with associated osteoporosis. (c) post –opt X – ray DL spine- lateral and antero-posterior view- open thoracolumbar fusion

drainage. This limited open technique restricts muscle dissection only at the involved levels and also allows us to place the horizontal transverse bars on the previously placed percutaneous rods. This we believe gives biomechanical strength to the construct and significantly reduced the muscle dissection to just one level and reduced blood loss and operative time.

Among 16 cervical Tb patients, 6 patients underwent only anterior approach with median cervical corpectomy of the involved cervical vertebral body, decompression of epidural abscess and fusion with expandable cage and anterior cervical plate (Jayon Implants, Titanium) [Figure 2]. The remaining 10 patients underwent both anterior and posterior cervical fusion (360 degree), Anterior- corpectomy with cage and plate fixation and posterior lateral mass fixation, due to the presence of kyphosis. All patients' abscess/granulation samples were sent for Ziehl–Neelsen staining and TB culture and histopathology to identify mycobacterium. In the latter half of the study, samples were also sent for cartridge-based nucleic acid amplification test (CBNAAT).

Postoperative management

All the patients were started on antitubercular treatment (ATT), 2 months intensive phase (4 drugs, H – isoniazid [5 mg/kg], R – rifampicin [10 mg/kg], Z – pyrazinamide [35 mg/kg], and E – ethambutol [20 mg/kg]), followed by 3 drugs (H-Isoniazid, R-Rifampicin, Z-ethambutol) for 4 months followed by continuation phase (2 drugs, H- Isoniazid R-Rifampicin) for 12 months according to RNTCP guidelines. Postoperatively, patients

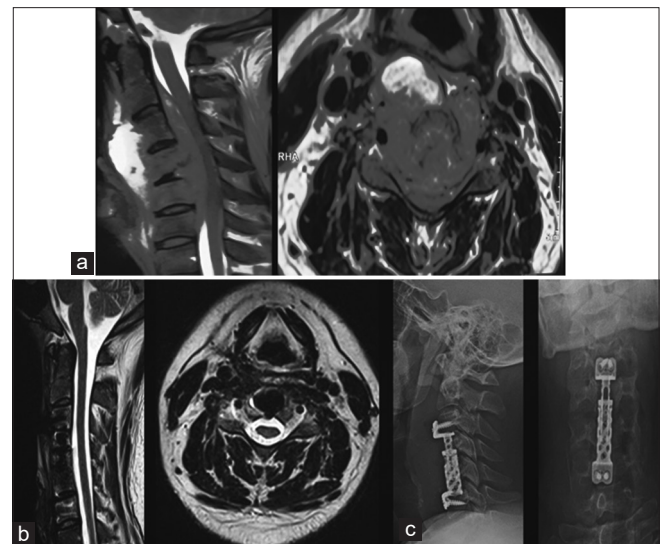

Figure 2: (a) pre-opt T2 W MRI Cervical spine, sagittal and axial images- showing isointense lesion with C4 body destruction and extension to epidural space with cord compression and also to prevertebral space. (b) post-opt T2 W MRI Cervical spine- showing complete resolution of lesion with no cord compression. (c) Post –opt X-Ray C spine lateral and antero-posterior view- C 4 Corpectomy with placement of expandable cage and cervical plate.

were followed up at 6, 12, and 18 months. At the 6th and 18th months, X-ray spine was done to assess the fusion and MRI scan with gadolinium was repeated after 12 months to assess the eradication of disease.

Statistical analysis

Data were analyzed using SPSS software version 18.0 (SPSS Inc. Released in 2009. PASW Statistics for Windows, version 18.0. Chicago, IL, USA: SPSS Inc.). The continuous variables were analyzed using descriptive statistics using mean and standard deviation (SD). The categorical variables were analyzed using frequency and percentage. The frequency distribution of the number of cases, as per their ASIA grade (ordinal data), was compared before and after surgery using Wilcoxon signed-rank test. Further, the A to E score was converted into Likert scale 1–5, respectively, for statistical analysis of the mean scores. Baseline comparisons were carried out using Students' *t*-test for continuous variables and Chi-square test for categorical variables. Paired *t*-test was employed for analysis of presurgery to postsurgery scores. $P \leq 0.05$ was considered statistically significant.

Results

A total of 70 patients were included in the study. A total number of patients were 87, out of which 17 patients were lost to follow-up and were excluded from the study. Out of which, 42 were males and 28 were females. The average age group is 42.5 years, the youngest being 16 years and the oldest 65 years. No gender-related difference was seen in our study. The most common site of involvement was thoracic followed by lumbar, cervical, and thoracolumbar [Table 1]. Pain was the most common symptom, and weakness was seen in 32 patients, 20 of whom had epidural compression [Table 1]. All patients underwent surgical treatment which allowed effective abscess drainage and debridement of tubercular granulation and adequate decompression and spine stabilization. The frequency distribution of patients based on ASIA grade indicated a

significant improvement in the grading postsurgery with a higher number of cases in D and E grades [Table 2].

On Analysing all the patients who presented before 4 weeks and underwent surgery with or without epidural abscess (either percutaneous pedicle screw fixation and transpedicular biopsy followed by anti-tubercular treatment or underwent laminectomy and abscess draining), all patients undergoing early surgery showed improvement in their ASIA grade significantly. [Table 3].

On Analysing, only those patients presenting with epidural abscess with neurological deficits, significant improvement in ASIA grade was seen in patients who underwent surgical decompression of abscess within 4 weeks as compared to those patients who presented later. This shows early decompression is beneficial in patients with epidural abscess [Table 3].

Complication

Surgical complication was seen in one patient, who had postoperative wound infection and residual psoas abscess. The patient was managed by CT-guided aspiration of psoas abscess and injectable antibiotics short course, and ATT was continued. Good fusion was seen in all the patients by 1 year on an average (6–24 months) as seen on X-ray and complete eradication of disease seen in all 70 patients after 18 months of ATT as seen on MRI with gadolinium.

Discussion

TB has a worldwide impact and is more commonly seen in developing countries with multidrug resistance TB a growing concern in society.^[15,16] Spinal TB accounts for 40% of all extrapulmonary TB.^[17] The most difficult cases to treat are those with extensive spine involvement, vertebral body collapse, severe deformity, and neurological deficits due to large abscesses causing spinal cord compression.

The antitubercular drug is the mainstay of treatment for TB resulting in spontaneous fusion in about 80% of cases. Conventional medical treatment for spinal TB is for 18–24 months,^[10] however, some prefer to treat for 6–12 months.^[18,19] In our center, we followed RNTCP protocol of intensive phase for 6 months followed by continuation

Table 1: Frequency distribution of location and clinical presentation of spinal tuberculosis

	n (%)
Location of TB spine	
Cervical	16 (22.8)
Thoracic	28 (40)
Lumbar	20 (28.5)
Thoracolumbar	6 (8.5)
Total	70 (100)
Clinical presentation	
Back pain	70 (100)
Fever	52 (74.3)
Cough	10 (14.3)
Weight loss	26 (37.1)
Weakness	32 (45.7)
Numbness	28 (40)
TB – Tuberculosis	

Table 2: Frequency distribution of cases as per American Spinal Injury Association grading before and after surgery

	Pre, n (%)	Post, n (%)	P
A	2 (2.9)	2 (2.9)	0.001
B	6 (8.6)	0	
C	6 (8.6)	2 (2.9)	
D	24 (34.3)	12 (17.1)	
E	32 (45.7)	54 (77.1)	

Values are given as number of patients, and number in parenthesis indicates the percentage; *P* value was calculated using Wilcoxon signed-rank test; $P < 0.05$ was considered statistically significant; Values are given as mean (SD). SD – Standard deviation

Table 3: Change in ASIA grade (score) after surgical intervention among patients with and without epidural abscess/ collection based on time of presentation

	Pre	Post	P
All patients			
Time of presentation and treatment (weeks)			
≤4	4.1 (0.57)	5 (0)	<0.0001
>4	3.25 (2.06)	3.75 (1.89)	0.170
Patients with epidural abscess/collection			
Time of presentation and treatment (weeks)			
≤4	4.0 (0.54)	5 (0)	<0.001
>4	3 (2.83)	3 (2.83)	

Values are given as number of patients, and number in parenthesis indicates the percentage; *P* value was calculated using Wilcoxon signed-rank test; *P*<0.05 was considered statistically significant; Values are given as mean (SD). SD – Standard deviation

phase for 12 months which showed complete resolution on MRI images. The diagnosis of the disease is made by histopathological examination and CBNAAT report. Medical management has to be combined with surgery if there is vertebral instability, pan-vertebral lesions, severe kyphosis, failure of the medical management, progressive deformity, evolving neurological impairment, or presence of abscess or epidural collection. Combined treatment is more effective in the management of TB spine,^[20] which enables for abscess drainage/debridement of granulation tissue, specimen for histopathology, and spinal fusion and deformity correction. Surgical management has resulted in early neurological improvement and enabling the early return of patients to routine activity. However, surgical management of spinal TB has always been controversial, with a few advocating surgical management, versus others claiming no additional benefits with surgical management.^[21] Several benefits of surgical management of spinal TB do exist. These are immediate relief from symptoms (pain), and compression of neural tissue, reduced kyphosis (early and late), faster and higher bone fusion, and less bone loss.^[22] In the current retrospective nonrandomized study, we presented data of about seventy patients who presented with spinal TB and were surgically treated over a duration of 2 years. Only those who had all medical records and at least a year of follow-up were analyzed for prognosis postsurgical management. American Spinal Association Impairment Scale (ASIA) was used to grade neurological impairment (both motor and sensory).

The main observation of this study was the time of presentation and treatment – “earlier the better” – when the patient presented before 4 weeks and was surgically managed within that time, there was a statistically significant improvement in ASIA grading after surgery, especially in those patients with epidural abscess with cord compression. Good fusion was seen in all the patients by the end of a year, with complete eradication after 18 months of ATT. Early presentation and early start of ATT and early surgery when required results in prevention of neurological deterioration.^[22] To the best of our knowledge, not many studies have shown the exact timing of surgery

and clinical improvement with early surgical management of TB spine, in order to compare our observations.

Approaches for surgery can be either anterior, posterior, or combined approaches. We have also observed good surgical outcome with the posterior approach in all the thoracic and lumbar TB cases, as was seen in previous studies.^[23-26] Posterior approach surgery not only reduces bleeding but also shortens operation time and length of stay.^[24] Posterior approach can directly relieve spinal stenosis and nerve root compression; both spinal decompression and internal fixation can be done at the same time, so patient compliance is better.^[23-25] Posterior fusion combined with rigid instrumentation has shown to reduce intraoperative anesthetic and surgical complexity and morbidity that can be associated with the anterior approach. Even without debridement of the affected vertebral bodies, up to 98% cure rate with posterior fusion alone and chemotherapy is seen.^[27] Posterior debridement and internal fixation using transpedicular screw or pedicular/laminar hook/rod hardware in patients with neurological impairment due to spondylitis gives good neurological results and also gives better kyphosis correction as compared to anterior procedures.^[28] Some authors prefer anterior approach as they feel better decompression and larger surface area for graft placement post debridement.^[6,29,30]

In the current study, 12 patients underwent minimally invasive pedicle screw fixation either with transpedicular decompression and biopsy or with an additional midline small incision for single-level laminectomy and epidural abscess drainage. This significantly reduced the muscle dissection in the upper and lower levels of involvement and time of surgery. Various studies do show benefit with minimally invasive procedures with reduced operative time, blood loss, postoperative pain and early recovery with adequate improvement in neurological status postsurgery.^[31-33]

Conclusion

Since spinal TB is a disease of the younger population, it is important to conserve neural tissue, prevent spread of infection, and prevent associated comorbidities. With this study, it may thus be concluded that surgical management is effective in treatment of spinal TB when intervention is early

along with standard medical management of TB. With our experience in this tertiary care center, it may be commented that posterior approach can offer adequate decompression and internal fixation as a single-stage procedure with postoperative fusion rates. Minimally invasive pedicle screw fixation is an advanced surgical technique with less muscle dissection and blood loss and especially found effective in long-segment fusions wherein midline open single-level laminectomy and decompression could be added at the level of epidural abscess.

Financial support and sponsorship

Nil.

Conflicts of interest

There are no conflicts of interest.

References

- Sai Kiran NA, Vaishya S, Kale SS, Sharma BS, Mahapatra AK. Surgical results in patients with tuberculosis of the spine and severe lower-extremity motor deficits: A retrospective study of 48 patients. *J Neurosurg Spine* 2007;6:320-6.
- India TB Report 2020 – National Tuberculosis Elimination Programme. Available from: <https://tbcindia.gov.in/showfile.php?lid=3538>. [Last accessed on 2021 Apr 20].
- Khanna K, Sabharwal S. Spinal tuberculosis: A comprehensive review for the modern spine surgeon. *Spine J* 2019;19:1858-70.
- Cavus G, Gezeran Y, Ökten AI, Tolunay O, Çelik T, Arslan A, *et al.* Surgical approaches to upper thoracic Pott's disease with spinal instability during childhood: Two cases. *Childs Nerv Syst* 2018;34:1221-7.
- Fam AG, Rubenstein J. Another look at spinal tuberculosis. *J Rheumatol* 1993;20:1731-40.
- Bailey HL, Gabriel M, Hodgson AR, Shin JS. Tuberculosis of the spine in children. Operative findings and results in one hundred consecutive patients treated by removal of the lesion and anterior grafting. *J Bone Joint Surg Am* 1972;54:1633-57.
- Tuli SM. Treatment of neurological complications in tuberculosis of the spine. *J Bone Joint Surg Am* 1969;51:680-92.
- Rivas-Garcia A, Sarria-Estrada S, Torrents-Odin C, Casas-Gomila L, Franquet E. Imaging findings of Pott's disease. *Eur Spine J* 2013;22 Suppl 4:567-78.
- Nussbaum ES, Rockswold GL, Bergman TA, Erickson DL, Seljeskog EL. Spinal tuberculosis: A diagnostic and management challenge. *J Neurosurg* 1995;83:243-7.
- Rajasekaran S, Khandelwal G. Drug therapy in spinal tuberculosis. *Eur Spine J* 2013;22 Suppl 4:587-93.
- A 10-year assessment of a controlled trial comparing debridement and anterior spinal fusion in the management of tuberculosis of the spine in patients on standard chemotherapy in Hong Kong. Eighth Report of the Medical Research Council Working Party on Tuberculosis of the Spine. *J Bone Joint Surg Br* 1982;64:393-8.
- Halsey JP, Reeback JS, Barnes CG. A decade of skeletal tuberculosis. *Ann Rheum Dis* 1982;41:7-10.
- Soares do Brito J, Batista N, Tirado A, Fernandes P. Surgical treatment of spinal tuberculosis: An orthopedic service experience. *Acta Med Port* 2013;26:349-56.
- Rasouli MR, Mirkoohi M, Vaccaro AR, Yarandi KK, Rahimi-Movaghar V. Spinal tuberculosis: Diagnosis and management. *Asian Spine J* 2012;6:294-308.
- McLain RF, Isada C. Spinal tuberculosis deserves a place on the radar screen. *Cleve Clin J Med* 2004;71:537-9, 543-9.
- WHO | Guidelines for Treatment of Tuberculosis. Available from: <https://www.who.int/tb/publications/2010/9789241547833/en/>. [Last accessed on 2020 Oct 27].
- Guerrado E, Cerván AM. Surgical treatment of spondylodiscitis. An update. *Int Orthop* 2012;36:413-20.
- Bjune G, Cotton M. WHO | Guidance for National Tuberculosis Programmes on the Management of Tuberculosis in Children. WHO. Available from: http://www.who.int/tb/publications/childtb_guidelines/en/. [Last accessed on 2020 Sept 29].
- Blumberg HM, Burman WJ, Chaisson RE, Daley CL, Etkind SC, Friedman LN, *et al.* American Thoracic Society/Centers for Disease Control and Prevention/Infectious Diseases Society of America: Treatment of tuberculosis. *Am J Respir Crit Care Med* 2003;167:603-62.
- Phalak M, Kale SS. Tuberculosis of the thoracic spine- when and how to operate. *Current practice in Neurosciences*. 2019;1:1-12.
- Pandita A, Madhuripan N, Pandita S, Hurtado RM. Challenges and controversies in the treatment of spinal tuberculosis. *J Clin Tuberc Other Mycobact Dis*. 2020;19. doi:10.1016/j.jctube.2020.100151. eCollection 2020 May.
- Garg RK, Somvanshi DS. Spinal tuberculosis: A review. *J Spinal Cord Med* 2011;34:440-54.
- D'souza AR, Mohapatra B, Bansal ML, Das K. Role of posterior stabilization and transpedicular decompression in the treatment of thoracic and thoracolumbar TB: A retrospective evaluation. *Clin Spine Surg* 2017;30:E1426-33.
- Zhang H, Sheng B, Tang M, Guo C, Liu S, Huang S, *et al.* One-stage surgical treatment for upper thoracic spinal tuberculosis by internal fixation, debridement, and combined interbody and posterior fusion via posterior-only approach. *Eur Spine J* 2013;22:616-23.
- Jain A, Jain RK, Kiyawat V. Evaluation of outcome of transpedicular decompression and instrumented fusion in thoracic and thoracolumbar tuberculosis. *Asian Spine J* 2017;11:31-6.
- Rath SA, Neff U, Schneider O, Richter HP. Neurosurgical management of thoracic and lumbar vertebral osteomyelitis and discitis in adults: A review of 43 consecutive surgically treated patients. *Neurosurgery* 1996;38:926-33.
- Güven O, Kumano K, Yalçın S, Karahan M, Tsuji S. A single stage posterior approach and rigid fixation for preventing kyphosis in the treatment of spinal tuberculosis. *Spine (Phila Pa 1976)* 1994;19:1039-43.
- Cui X, Ma YZ, Chen X, Cai XJ, Li HW, Bai YB. Outcomes of different surgical procedures in the treatment of spinal tuberculosis in adults. *Med Princ Pract* 2013;22:346-50.
- Dai LY, Jiang LS, Wang W, Cui YM. Single-stage anterior autogenous bone grafting and instrumentation in the surgical management of spinal tuberculosis. *Spine (Phila Pa 1976)* 2005;30:2342-9.
- Hodgson AR, Stock FE. Anterior spinal fusion a preliminary communication on the radical treatment of Pott's disease and Pott's paraplegia. *Br J Surg* 1956;44:266-75.
- Ito M, Sudo H, Abumi K, Kotani Y, Takahata M, Fujita M, *et al.* Minimally invasive surgical treatment for tuberculous spondylodiscitis. *Minim Invasive Neurosurg* 2009;52:250-3.
- Kandwal P, Garg B, Upendra B, Chowdhury B, Jayaswal A. Outcome of minimally invasive surgery in the management of tuberculous spondylitis. *Indian J Orthop* 2012;46:159-64.
- Garg N, Vohra R. Minimally invasive surgical approaches in the management of tuberculosis of the thoracic and lumbar spine. *Clin Orthop Relat Res* 2014;472:1855-67.