

The Importance of Measuring Mamillopontine Distance as a Diagnostic Criterion of Hydrocephalus Degrees

Abstract

Objectives: The occurrence of obstructive hydrocephalus (ObH) as sequelae of deep midline brain tumors (third and lateral ventricles, thalamic, pineal region, brainstem, and fourth ventricle) can be estimated up to 90% of cases. We believe that the mamillopontine distance (MPD) – the distance between the lower surface of the mammillary body and the upper surface of the pons in the sagittal images – can be a sufficiently reliable alternative to the Evans' index (EI) for the diagnosis of ObH. **Patients and Methods:** The results of mamillopontine distance (MPD), Evans' index (EI), and angle of corpus callosum (ACC) measurement of 43 patients with non-communicative hydrocephalus were analyzed compared with results of 30 people without brain pathology. **Results:** Findings revealed that MPD is a strong and reliable alternative to the EI. MPD showed high specificity and sensitivity in the diagnosis of occlusive hydrocephalus. Moreover, from those findings, we have proposed classification of the degree of hydrocephalus severity, depending on the MPD. **Conclusion:** MPD one of the more accurate and powerful method for defining presence of hydrocephalus in-patient even in early stage of occlusion. It has high specificity and sensitivity and capable classify hydrocephalus into grades according to severity.

Keywords: Brain tumor, Evans' index, mamillopontine distance, neuro-oncology, obstructive hydrocephalus

Introduction

The occurrence of obstructive hydrocephalus (ObH) as sequelae of deep midline brain tumors (third and lateral ventricles, thalamic, pineal region, brainstem, and fourth ventricle) can be estimated up to 90% of cases. The Evans' index (EI) proposed in 1942 by William Evans remains the most popular index of ventricular dilatation,^[1] and EI >0.3 is accepted in many international recommendations as the criterion of ventriculomegaly.^[2-5]

The EI is an easy, fast, and a strong linear method, which does not require special software. It shows the ratio of the maximum width of the anterior horns of the lateral ventricles and the maximum internal diameter of the skull at the same level in the axial magnetic resonance imaging (MRI) and computed tomography (CT) scans. However, the EI cannot be accurate in cases of asymmetric or uneven expansion of the lateral ventricles,^[6] which is one of the limitations of its application in cases of

occlusive hydrocephalus of tumor origin. Hence, recent studies using volumetric analysis have suggested that EI is not an ideal method in the diagnostics of ventricular dilatation, its values vary significantly depending on the CT/MRI slice within the same scan.^[7,8] Despite this, the EI is routinely used in clinical practice^[9] and has shown that it correlates well with ventricular volume.^[10]

In modern neurosurgery, volumetric ventricular volume analysis provides the most accurate information about ventricular volume, but it is labor-intensive, technically complex (as it requires specialized software) that is not always available in every hospital (especially in rural and developing countries) and is not suitable for general neurosurgical practice, as it is not financially affordable. It has been proven that simple, reliable, and easily reproducible linear measurements, including EI, can be effective alternatives to volumetric analysis to determine the size of the ventricles.^[10,11]

We believe that the mamillopontine distance (MPD) – the distance between

**Gayrat Maratovich Kariev,
Ulugbek Maksudovich Asadullaev,
Temur Anvarovich Duschanov,
Shavkat Orzikulovich Rasulov,
Dilshod Muhammad Valievich Mamadaliev,
Dilshod Nayimovich Khodjimetov**

Republican Specialized Scientific and Practical Medical Center of Neurosurgery, Tashkent, Uzbekistan

Address for correspondence:

*Dr. Temur Anvarovich Duschanov,
Republican Specialized Scientific and Practical Medical Center of Neurosurgery, Tashkent, Uzbekistan.
E-mail: asadullaevu@gmail.com*

Access this article online

Website: www.asianjns.org

DOI: 10.4103/ajns.AJNS_79_18

Quick Response Code:



This is an open access journal, and articles are distributed under the terms of the Creative Commons Attribution-NonCommercial-ShareAlike 4.0 License, which allows others to remix, tweak, and build upon the work non-commercially, as long as appropriate credit is given and the new creations are licensed under the identical terms.

For reprints contact: reprints@medknow.com

How to cite this article: Kariev GM, Asadullaev UM, Duschanov TA, Rasulov SO, Mamadaliev DM, Khodjimetov DN. The importance of measuring mamillopontine distance as a diagnostic criterion of hydrocephalus degrees. *Asian J Neurosurg* 2019;14:166-71.

the lower surface of the mammillary body and the upper surface of the pons in the sagittal images – can be a sufficiently reliable alternative to the EI for the diagnosis of ObH.

The purpose of this study was to study the results of CT/MRI images in patients with tumor-associated occlusive hydrocephalus and to compare the significance of differences in MPD, angle of corpus callosum (ACC), and EI with the control group and the correlation of MPD, ACC, and EI with various other indicators of increased intracranial pressure (periventricular edema [PvE], papilledema, and Karnofsky scale [KS]).

Pathological changes in MRI or CT scan of the brain with intracranial hypertension can be explained pathophysiologically, which is well understood by the Monro–Kelly doctrine.^[12] According to this theory, the volume of intracranial and intraspinal spaces is constant, and these spaces consist of (1) cerebrospinal fluid (CSF), (2) brain and spinal cord, that is, -parenchyma, and (3) arteries and veins. If one of the components changes in volume, CSF, or blood volume, therefore, there will be compensatory decrease on the other parts. Thereby, increasing ventricular CSF leads to increasing intraventricular pressure, consequently, PvE develops. Ventricular dilation and PvE of white matter due to transependymal resorption of CSF are characteristic features of hypertensive hydrocephalus.^[13-16] This is the reason we included an objective quantitative assessment of PvE in our study as an indicator of increased intracranial pressure in the obstructive form of hydrocephalus. We also included an assessment of the state of the optic disc (OD) in ophthalmoscopy, as one of the objective signs of increased intracranial pressure.^[17,18] We assume that a comprehensive approach to comparing these indicators of morphometric analysis with objective and clinical data such as the quantitative parameters of PvE and the condition of OD at ObH can serve to create a classification of the degree of severity of ObH, depending on the most reliable and sensitive morphometric parameters.

Materials and Methods

All patients underwent a comprehensive examination, including clinical-neurological, instrumental, and laboratory methods of investigation. The leading clinical sign of the disease was hypertensive-hydrocephalic syndrome, the severity of focal symptoms depended on the level of occlusion of the CSF pathways, the etiology and phase of the clinical course of the disease, and the patient's age. The inclusion criteria were as follows:

1. Presence of a brain tumor which causes compression of the CSF pathways
2. Clinical presentation of ObH.

The work is based on a retrospective analysis of the results of clinical and laboratory examination and observation of 43 patients with ObH of different origin-etiology, who were on treatment at the Republican Scientific Center of Neurosurgery of the Republic of Uzbekistan during the period 2013–2016. Age of patients ranged from 1.5 months to 60 years. Most predominantly: By age group amount of patients older and younger 12 years were 27 (62.8%) and 16 (37.2%) respectively. By gender there were no critical different, 53.5% ($n = 23$) were female and 46.5% ($n = 20$) male.

The control group consisted of individuals who underwent MRI and/or CT examination in the private clinics “Diyor” and “Jacksoft Medical Service,” the inclusion criterion was absence of brain pathology on MRI and/or CT examinations. Age varied from 5 to 72 years, of which number of younger children 12 years were $n = 7$ (23.3%) and older $n = 23$ (76.7%). Men – 16 (53.3%) and women – 14 (46.7%).

Measurement methods

The MRI study was included an assessment of the following morphometric parameters:

1. MPD – the distance between the lower surface of the mammillary body and the upper surface of the pons in the sagittal images^[19,20] [Figure 1a]
2. ACC – ideally the angle should be measured in a coronary projection perpendicular to the line between the anterior and posterior commissure at the level of the posterior commissure^[21,22] since the angle of the corpus callosum is very different, depending on the level of the scan in which the measurement was

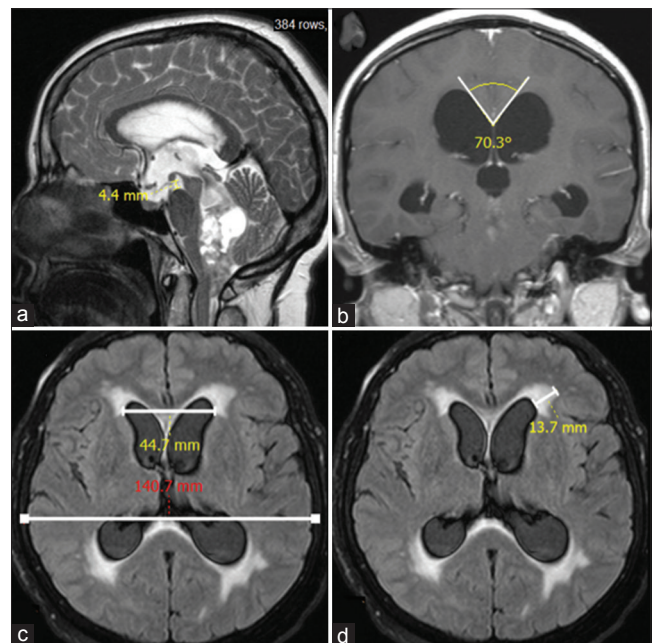


Figure 1: Types of linear measurement methods on magnetic resonance imaging images: (a) mammillopontine distance; (b) angle of corpus callosum; (c) Evans' index; (d) periventricular edema

performed. The normal value is usually between 100° and 120°^[22] [Figure 1b]

3. EI – The ratio of the maximum width of the anterior horns of the lateral ventricles and the maximum internal diameter of the skull at the same level in the axial MRI and CT scans^[8,23] [Figure 1c]
4. PvE – The prevalence of PvE was measured from the anterior side of the anterior horn of the lateral ventricles in millimeter. [Figure 1d].

Clinical correlation

A study of the ocular fundus (OF) for the presence of papilledema was also performed, and its degree was determined as a clinical indicator of increased intracranial pressure to make subsequent correlation with the above-mentioned morphometric parameters. During OF examination, the condition of the optic nerve disc was assessed as follows, starting from the absence of papilledema to a severe stage; we have used popular papilledema grading system (Frisen Scale):

- Stage 0: Normal OD – absence of papilledema, retinal angiopathy can be observed in ophthalmoscopy
- Stage 1: Very early papilledema
- Stage 2: Early papilledema
- Stage 3: Moderate papilledema
- Stage 4: Marked papilledema
- Stage 5: Severe papilledema.

Furthermore, we carried out an integrative assessment of the patient’s state according to the KS, which serves to assess the patient’s quality of life and take into account the dynamics during treatment, is also widely used by neurosurgeons in clinical practice.

Statistical analysis

The relationship between the indicators was analyzed using the appropriate coefficient or criterion: the Pearson’s correlation and the Spearman’s correlation. The analysis was made using Student’s *t*-criteria for two groups. All results were corresponded statistically strong *P* value (≤ 0.05 or ≤ 0.01). The statistical calculations were performed using the IBM SPSS Statistics 22.0.0.0, (IBM, Armonk, NY, USA), based on the Mac OS operating system.

Results and Discussion

We considered it is rational to compare the morphometric parameters of MRI studies in patients with occlusive hydrocephalus with a control group, and we divided the group with pathology into two: 1st group: children under 12-year-old, and 2nd group: 12–60 years. Age of patients ranged from 1.5 months to 60 years. Most predominantly: adults were 27 (62.8%) and children under 12 years – 16 (37.2%). Women were 23 (53.5%) and men were 20 (46.5%).

The results of the study of all four morphometric parameters, the status of the fundus and the KS showed that the differences in the mean values of all the indicators between the group with pathology and control are statistically significant. All examined in the control group had no PvE, pathology of the optic nerve disc, and there were also 100 pts on the KS [Table 1]. The mean value of the EI was equal to 0.299 ± 0.005 , at 0.242 ± 0.003 in the control group. In 19 patients, EI < 0.30 (44.2%) was observed, and in the remaining 24, the diagnostic threshold of ventriculomegaly proposed by many authors was observed. There was also a significant narrowing of the MPD (3.4 ± 0.3) in patients with pathology, at 9.8 ± 0.1 in the control group. In 4 (9.3%) patients, the MPD was < 1 mm, 3 of them children and 1 adult. Our results for the normal MPD (9.85 ± 0.14 mm) were similar to the results of Segev *et al.*^[20] and differ from the results published by El Gammal *et al.* (11.5 mm), probably because, that our reference point was the center of the mammillary body and not the top of their anterior part.^[24]

When analyzing the indexes of ACC, a narrowing of the angle was revealed in many patients – 97.7 ± -3.3 , with an average value in the control group – 125.3 ± 1.2 . When dividing patients into two groups due to anthropometric age differences, the following differences were found in (1) children under 12 years (37.2%) and (2) adults and children over 12 years of age: MPD and ACC rates were significantly lower in children in comparison with the 2nd group. Furthermore, children have a relatively large PvE – $8.3 \text{ mm} \pm 1.1 \text{ mm}$ than in adults (6.0 ± 0.9). Furthermore, in children, a significantly poor condition of OD and KS was observed in the 2nd group.

Table 1: The average values of IE, MPD, ACC, PvE, OD and KS in all patients and control group (Mean±standard deviation). The maximum and minimum values are in brackets

	IE	MPD	ACC	PvE	OD	KS
All patients (n=43)	0.299±0.005 (0.203-0.378)	3.4±0.3 (0.0-8.8)	97.1±3.3 (45.3-128.1)	6.9±0.7 (0.6-22.0)	2.2±0.2 (0.0-5.0)	68.6±1.4 (50-80)
Children (n=16)	0.295±0.009 (0.203-0.344)	2.6±0.6 (0.0-7.4)	87.4±6.1 (45.3-128.1)	8.3±1.1 (0.6-20.9)	2.4±0.4 (0.0-4.0)	65.6±1.6 (50-70)
Adults (n=23)	0.302±0.008 (0.221-0.378)	3.9±0.4 (0.5-8.8)	102.9±3.4 (70.2-128.1)	6.0±0.9 (1.3-22.0)	2.0±0.3 (0.0-5.0)	70.4±1.9 (50-80)
Control (n=30)	0.242±0.003 (0.202-0.279)	9.8±0.1 (9.0-11.8)	125.3±1.2 (106.3-136.8)	0.0 (0)	0.0 (0)	100 (100)

The greatest statistically significant differences in morphometric parameters were in the MPD ($P < 0.001$) between patients with pathology and the control group, and it was also the highest in children under 12 years of age ($P < 0.001$), and the remaining patients were older than 12 years ($P < 0.001$) [Table 2].

We also investigated the correlation between the morphometric parameters and the data of air defense, OD, and KS. For this, we used the two-sided Spearman correlation analysis method, which is most often used in medicine. The analysis data showed that the EI has the strongest inverse correlation with MPD ($r = -0.725$, $P = 0.01$) [Table 3], followed by UMR ($r = -0.690$; $P = 0.01$) and PvE ($r = 0.362$; $P = 0.05$). We did not reveal a statistically significant correlation of EI with KS and OD.

In the study of the correlation of MPD with the rest of the indices, a strong correlation was observed with the indices of ACC ($r = 0.698$, $P = 0.01$) and PvE ($r = -0.588$, $P = 0.01$), except for the strong inverse correlation with the EI described above. Furthermore, the MPD correlates with the KS ($r = 0.356$; $P = 0.05$). When analyzing ACC data, the greatest correlation with MPD is determined ($r = 0.698$, $P = 0.01$) and EI ($r = -0.690$; $P = 0.01$). The greatest correlation of PvE is observed with MPD ($r = -0.588$, $P = 0.01$) and ACC ($r = -0.608$; $P = 0.01$).

In medical practice, the sensitivity and specificity of the diagnostic method is important, as far as it determines truly positive and negative results. We determined and compared the sensitivity and specificity of the most popular and often used in practice method of morphometric analysis – EI and MPD. The specificity of both linear methods in our sample is 100% since the absence of pathology is reliably determined. The sensitivity of the EI is equal to 55.8% since the criterion proposed by many authors of ventriculomegaly – $EI > 0.30$, then the data of 24 patients (0.327 ± 0.005) corresponded to the criterion,

and in the remaining 19 patients, the mean EI was $0.265 + 0.006$. When studying the parameters of MPD in patients, we found 100% sensitivity of the method, as in all patients according to our criteria the MPD values were more than 9 mm. In Figure 2, a visual interpretation of the MPD and EI indicators of all patients and control group is presented, with each point corresponding to a single patient. It is clearly seen that EI often gives a significant number of false-negative results.

As a result of the analysis of all the data of the study, we found that MPD is a worthy and strong alternative to EI in the diagnosis of ventricular hydrocephalus of occlusive genesis, in favor of this conclusion say:

1. The highest statistically significant differences between the control group and the patients ($P < 0.001$)
2. The strongest inverse correlation was between EI and MPD ($r = -0.725$, $P = 0.01$), which indicates the tightness of the relationship between these indicators
3. MPD accurately separates 43 patients with obstructive hydrocephalus from 30 ones of control group, which proves high sensitivity and specificity of this method and 30 of them had MPD < 9 mm from all 30 examined in the control group
4. Ease of use, MPD is measured in the sagittal scan MRI/CT and does not require any arithmetic calculations and special equipment.

We believe that these MPD data can serve to assess the degree of hydrocephalus, and we propose our classification of the degrees of hydrocephalus based on the MPD, and we divide it into three degrees:

- I – degree: MPD from 5.1 to 8.9 mm
- II – degree: MPD from 2.1 to 5.0 mm
- III – degree: MPD from 0 to 2.0 mm.

In the study of patients, we divided them into three groups, depending on the MPD, and studied their relationship to other indicators. A direct proportional relationship between

Table 2: Results of the statistical significance of differences in mean values between groups with pathologies and control (t-test of Student)

	IE	MPD	ACC	PvE
All patients (n=43)	t=8.21 P-l=6.9*10-12	t=16.7 P-l=2.7*10-26	t=8.1 P-l=1.1*10-11	t=9.6 P-l=1.7*10-14
Children (n=16)	t=5.16 P-l=5.7*10-6	t=12.1 P-l=1.2*10-15	t=6.1 P-l=2.6*10-7	t=7.1 P-l=6.7*10-9
Adults (n=23)	t=7.02 P-l=3.5*10-9	t=12.9 P-l=2.7*10-18	t=6.3 P-l=5.2*10-8	t=6.8 P-l=7.4*10-9

Table 3: Results of the correlation analysis of Spearman’s morphometric data (2-sided)

	IE	MPD	ACC	PvE	OD	KS
IE	1	r=-0,725**	r=-0,690**	r=0,362*	r=0.253	r=-0.289
MPD	r=-0,725**	1	r=0,698**	r=-0,588**	r=-0.294	r=0,356*
ACC	r=-0,690**	r=0,698**	1	r=-0,608**	r=0-,345*	r=0,502**
PvE	r=0,362*	r=-0,588**	r=-0,608**	1	r=0,449**	r=-0,401*
OD	r=0.253	r=-0.294	r=-0,345*	r=0,449**	1	r=-0.267
KS	r=-0.289	r=0,356*	r=0,502**	r=-0,401*	r=-0.267	1

Note: **Correlation is significant at the level of 0.01 (2-sided). *Correlation is significant at the level of 0.05 (2-sided).

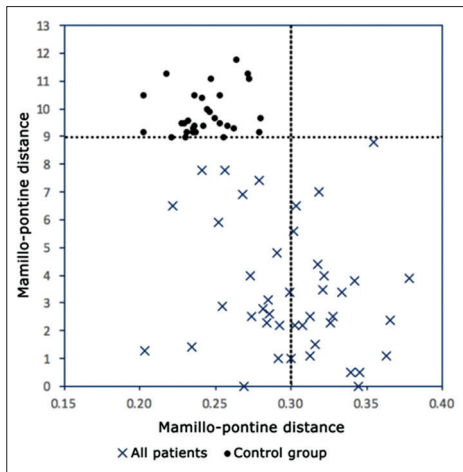


Figure 2: The values of the Evans' index and the mamillopontine distance of each examined person in the control group and in the group with occlusive hydrocephalus. The dotted line shows the mamillopontine distance (=9.0 mm) and the Evans index (=0.30)

the MPD and ACC and KS indices was found, as well as an inverse proportional relationship with the results of EI, PvE, and OD [Figure 2]. We also found that MPD is the most sensitive method that shows the patient's clinical condition, correlating with air defense, OD, and KS data.

I – degree was revealed in 10 (23.2%) patients, 8 (80%) of them are older than 12 years old. It differed significantly in the high index of the KS – 74 ± 2.2 . MPD was 7 ± 3 and EI was 0.28 ± 0.01 .

II – degree was detected in 22 (51.2%) patients, of which 16 (72.72%) patients were older than 12 years. The MPD was 3.1 ± 0.2 and the PvE was 7.6 ± 0.9 .

III – degrees were revealed in 11 (25.6%) patients, 8 (72.7%) of them were children under 12 years old. MPD was 0.9 ± 0.1 , PvE was 9.3 ± 1.5 ; and OF was 2.5 ± 0.4 . The lowest indications of KS were in the 1st group – 65.5 ± 1.6 .

From the above-mentioned results of the study, it follows that the division of the degree of hydrocephalus, depending on the MPD, makes it possible to clinically assess the overall condition of the patient with a single morphometric measurement that correlates well with other objective indicators of intracranial hypertension (OD and PvE), ventriculomegaly (EI and ACC), and patient status.

This is understandable with the advent of a new technology for image processing and the introduction of more complex calculations, that older methods of linear measurements can be eliminated in favor of three-dimensional volumes. Nevertheless, it should be taken into account that in the current economic climate of healthcare and with an increasing emphasis on cost-saving procedures, MPD and EI are simple measurements that reliably determine the increase in ventricles and do not require the expensive, laborious

and technically complex software required for volumetric analysis. In addition, these linear measurements may be the only way available in some medical institutions, such as rural areas and developing countries that do not have access to the latest imaging technology.

Conclusions

MPD is a strong and reliable alternative to the EI in all age groups and may be useful in rural areas and developing countries that do not have access to the latest imaging technology. MPD has high specificity and sensitivity in the diagnosis of occlusive hydrocephalus. The EI has the strongest inverse correlation with the MPD ($r = -0.725$, $P = 0.01$). The greatest statistically significant differences in morphometric indicators among patients and the control group were in MPD ($P < 0.001$). The use of the proposed classification of the degree of severity of hydrocephalus, depending on the MPD, makes it possible to clinically assess the patient's overall condition with a single morphometric measurement that correlates well with other objective indicators of intracranial hypertension (OD and PvE), ventriculomegaly (EI and ACC), and patient's status.

Financial support and sponsorship

Nil.

Conflicts of interest

There are no conflicts of interest.

References

- Evans WA. An encephalographic ratio for estimating ventricular enlargement and cerebral atrophy. *Arch Neurol Psych* 1942;47:931-37.
- Ishikawa M; Guideline Committee for Idiopathic Normal Pressure Hydrocephalus, Japanese Society of Normal Pressure Hydrocephalus. Clinical guidelines for idiopathic normal pressure hydrocephalus. *Neurol Med Chir (Tokyo)* 2004;44:222-3.
- Ishikawa M, Hashimoto M, Kuwana N, Mori E, Miyake H, Wachi A, et al. Guidelines for management of idiopathic normal pressure hydrocephalus. *Neurol Med Chir (Tokyo)* 2008;48 Suppl:S1-23.
- Marmarou A, Bergsneider M, Relkin N, Klinge P, Black PM. Development of guidelines for idiopathic normal-pressure hydrocephalus: Introduction. *Neurosurgery* 2005;57:S1-3.
- Relkin N, Marmarou A, Klinge P, Bergsneider M, Black PM. Diagnosing idiopathic normal-pressure hydrocephalus. *Neurosurgery* 2005;57:S4-16.
- Ragan DK, Cerqua J, Nash T, McKinstry RC, Shimony JS, Jones BV, et al. The accuracy of linear indices of ventricular volume in pediatric hydrocephalus: Technical note. *J Neurosurg Pediatr* 2015;15:547-51.
- Ambarki K, Israelsson H, Wählin A, Birgander R, Eklund A, Malm J, et al. Brain ventricular size in healthy elderly: Comparison between Evans index and volume measurement. *Neurosurgery* 2010;67:94-9.
- Toma AK, Holl E, Kitchen ND, Watkins LD. Evans' index revisited: The need for an alternative in normal pressure hydrocephalus. *Neurosurgery* 2011;68:939-44.

9. Lieb JM, Stippich C, Ahlhelm FJ. Normal pressure hydrocephalus. *Radiologe* 2015;55:389-96.
10. Reinard K, Basheer A, Phillips S, Snyder A, Agarwal A, Jafari-Khouzani K, *et al.* Simple and reproducible linear measurements to determine ventricular enlargement in adults. *Surg Neurol Int* 2015;6:59.
11. Bao J, Gao Y, Cao Y, Xu S, Zheng Y, Wang Y, *et al.* Feasibility of simple linear measurements to determine ventricular enlargement in patients with idiopathic normal pressure hydrocephalus. *J Craniofac Surg* 2016;27:e462-5.
12. Mokri B. The Monro-Kellie hypothesis: Applications in CSF volume depletion. *Neurology* 2001;56:1746-8.
13. Barkovich AJ. *Pediatric Neuroimaging*. 2nd ed. Philadelphia: Lippincott-Raven; 1996. p. 439-75.
14. Quisling RQ, Peters KR. Computed tomography. In: Youmans JR, editor. *Neurological Surgery*. 4th ed. Philadelphia: Saunders; 1996. p. 101-5.
15. Bradley WM, Quencer RM. Hydrocephalus and cerebrospinal fluid flow. In: Stark DD, Bradley WM, editors. *Magnetic Resonance Imaging*. 3rd ed. St. Louis: Mosby; 1999. p. 1483-507.
16. Zimmerman RD, Fleming CA, Lee BC, Saint-Louis LA, Deck MD. Periventricular hyperintensity as seen by magnetic resonance: Prevalence and significance. *AJR Am J Roentgenol* 1986;146:443-50.
17. Constantino T, Digre K, Zimmerman P. Neuro-ophthalmic complications of sarcoidosis. *Semin Neurol* 2000;20:123-37.
18. Katz JM, Bruno MK, Winterkorn JM, Nealon N. The pathogenesis and treatment of optic disc swelling in neurosarcoidosis: A unique therapeutic response to infliximab. *Arch Neurol* 2003;60:426-30.
19. Shah LM, McLean LA, Heilbrun ME, Salzman KL. Intracranial hypotension: Improved MRI detection with diagnostic intracranial angles. *AJR Am J Roentgenol* 2013;200:400-7.
20. Segev Y, Metser U, Beni-Adani L, Elran C, Reider-Groswasser II, Constantini S, *et al.* Morphometric study of the midsagittal MR imaging plane in cases of hydrocephalus and atrophy and in normal brains. *AJNR Am J Neuroradiol* 2001;22:1674-9.
21. Virhammar J, Laurell K, Cesarini KG, Larsson EM. The callosal angle measured on MRI as a predictor of outcome in idiopathic normal-pressure hydrocephalus. *J Neurosurg* 2014;120:178-84.
22. Ishii K, Kanda T, Harada A, Miyamoto N, Kawaguchi T, Shimada K, *et al.* Clinical impact of the callosal angle in the diagnosis of idiopathic normal pressure hydrocephalus. *Eur Radiol* 2008;18:2678-83.
23. Ng SE, Low AM, Tang KK, Chan YH, Kwok RK. Value of quantitative MRI biomarkers (Evans' index, aqueductal flow rate, and apparent diffusion coefficient) in idiopathic normal pressure hydrocephalus. *J Magn Reson Imaging* 2009;30:708-15.
24. El Gammal T, Allen MB Jr., Brooks BS, Mark EK. MR evaluation of hydrocephalus. *AJNR Am J Neuroradiol* 1987;8:591-7.