

Symptomatic Postsurgical Lumbar Pseudomeningocele Treated by Ultrasound-Guided Epidural Blood Patch Application

Abstract

Postsurgical pseudomeningoceles are extradural collections of cerebrospinal fluid (CSF) that results following an intraoperative dural breach. Although usually asymptomatic and self-subiding, they may present with symptoms of postural headache, blurred vision, diplopia, photophobia, back pain, radiculopathy, and vomiting. Most of the cases recover with conservative measures such as bed rest, hydration, and pressure dressings. Symptomatic patients usually require surgical re-exploration and direct open repair of the durotomy. We report the case of a 48-year-old female who presented with lumbar pseudomeningocele following lumbar microdiscectomy treated by Ultrasound-guided (USG)-guided epidural blood patch application. She had globular swelling at the surgical site, postural headache, and left lower-limb radicular pain with normal neurology. Her magnetic resonance imaging (MRI) showed a left L4 lamina defect with pseudomeningocele (measuring 5.5 cm × 4.2 cm × 4 cm) with intraspinal communication. USG was used to guide the aspiration of CSF from pseudomeningocele and to apply the epidural blood patch one level above and at the level of laminectomy. Postoperatively, she had marked improvement in her symptoms. At 1-year follow-up, she was completely symptom free and full resolution of pseudomeningocele was seen on 1-year follow-up MRI. This case is being reported to highlight the use of USG-guided epidural blood patch for the treatment of postoperative lumbar pseudomeningocele.

Keywords: Blood patch, durotomy, epidural, pseudomeningocele

Introduction

Pseudomeningocele is an extradural cerebrospinal fluid (CSF) collection arising from a dural defect that may be congenital, traumatic, or as a result of intraoperative dural tear during spinal surgery. The incidence of dural tears during spinal surgeries reported in the literature ranges from 1.7% to 16%.^[1,2] The exact incidence of postoperative pseudomeningocele is not known. Most cases go underreported as they are asymptomatic and resolve either spontaneously or with conservative methods. Surgeons are also reluctant to report this complication. Gerardi *et al.* reported an incidence of 6.8% of dural tears which are inaccessible to repair or go unrecognized during spinal surgeries.^[3,4] In cases of persistent CSF leak following dural repair, a multitude of consequences such as postural headache, nausea, vomiting, neck or back pain, dizziness, and VI cranial nerve palsy leading to diplopia, photophobia, and tinnitus may occur.^[5-7] Persistence of

these dural tears may result in chronic CSF leakage into the extradural space with encapsulation causing a pseudomeningocele.

Various treatment options such as close observation for spontaneous resolution, conservative measures such as bed rest, lumbar subarachnoid drainage, pressure dressings, hydration, and use of abdominal binder have been recommended.^[8-11] Re-exploration and surgical repair of defect may be necessary in patients with clinical features of intracranial hypotension, neurological deficit, external fistula, or infection.^[12-16] Epidural blood patches (EBPs) have been used successfully in postspinal headaches and spontaneous intracranial hypotension. EBP was first described for postlaminectomy pseudomeningocele by Lauer and Haddox in 1992.^[17] We report the case of a 40-year-old female with postoperative pseudomeningocele successfully treated with ultrasound (USG)-guided epidural blood patch application.

Rohit Akshay Kavishwar, Ajoy Prasad Shetty, Balavenkata Subramanian, Shanmuganathan Rajasekaran

Department of Spine Surgery, Ganga Medical Centre and Hospitals Pvt Ltd., Coimbatore, Tamil Nadu, India

Address for correspondence:

*Dr. Ajoy Prasad Shetty, Department of Spine Surgery, Ganga Medical Centre and Hospitals Pvt Ltd, Mettupalayam Road, Coimbatore – 641 043, Tamil Nadu, India
E-mail: ajoyshetty@gmail.com*

Access this article online

Website: www.asianjns.org

DOI: 10.4103/ajns.AJNS_83_21

Quick Response Code:



This is an open access journal, and articles are distributed under the terms of the Creative Commons Attribution-NonCommercial-ShareAlike 4.0 License, which allows others to remix, tweak, and build upon the work non-commercially, as long as appropriate credit is given and the new creations are licensed under the identical terms.

For reprints contact: WKHLRPMedknow_reprints@wolterskluwer.com

How to cite this article: Kavishwar RA, Shetty AP, Subramanian B, Rajasekaran S. Symptomatic postsurgical lumbar pseudomeningocele treated by ultrasound-guided epidural blood patch application. *Asian J Neurosurg* 2021;16:827-9.

Submitted: 15-Mar-2021

Revised: 26-Apr-2021

Accepted: 25-Jun-2021

Published: 18-Dec-2021

Case Report

A 48-year-old female presented at our hospital with a fluctuant, globular swelling on her back 1 month postmicrodiscectomy for L4–L5 disc prolapse, operated elsewhere. She also had back pain, left lower-limb radiculopathy, and postural headache. The swelling was 4 cm × 3 cm in size at the previous surgical healed scar and increased on standing and sitting. On examination, straight leg raising test was negative and she had normal motor power. There was no history of visual disturbances, fever, and bladder disturbances. Magnetic resonance imaging (MRI) showed a left L4 laminectomy defect with a pseudomeningocele having an ill-defined CSF intensity collection in the posterior paraspinal region [Figure 1] measuring 5.5 cm × 4.2 cm × 4 cm.

We treated the case by USG-guided CSF aspiration from the pseudomeningocele and application of epidural blood patch. Under all aseptic precautions, L3–L4 and L4–L5 spaces were identified and CSF was aspirated from the pseudomeningocele at L4–L5 space with a Tuohy needle. At the same time, 20 ml of blood was drawn from the antecubital vein, followed by 10 ml blood injection at L4–L5 and 10 ml at L3–L4 epidural space under USG guidance. The patient was made to sit for 15 min. Her postural headache and lower-limb radiculopathy were immediately relieved following the procedure.

On 1-year follow-up, the patient was completely symptom free and showed full resolution of pseudomeningocele on 1-year follow-up MRI [Figure 2].

Discussion

There is a reported incidence of 0.3%–2% of pseudomeningocele after spinal surgery in the literature.^[3,4] Pseudomeningoceles >5 cm have been characterized as “large,” while those >8 cm are characterized as “giant.”^[14] The most common symptoms reported in patients with pseudomeningocele were neck and back pain (64%), headaches (55%), and nausea and vomiting (36%). Sirlomask *et al.*^[18] suggest nonsurgical treatment in

asymptomatic patients and use of subarachnoid catheter in mildly symptomatic patients. Extirpation and dural repair should be reserved for patients with severe symptoms or those with persisting symptoms beyond several weeks postoperation. Re-exploration and closure procedures are not always effective, sometimes requiring repeated repair procedures.

EBPs have long been used to relieve postdural puncture headaches in patients who do not respond to conservative measures or in patients who present with spontaneous intracranial hypotension.^[19,20] EBP was first described for postlaminectomy pseudomeningocele by Lauer and Haddox in 1992.^[17] EBP is a procedure in which a small volume of the patient’s own blood is injected into the epidural space in an attempt to “plug” any small dural openings.

Sandwell *et al.*^[21] reported a success rate of 84% in resolution of headache and other symptoms. Successful injections occurred as late as 184 days after development of pseudomeningocele. It is thought that the blood forms a clot over the dural tear and allows healing of the dura; furthermore, the clot in the epidural space raises extradural tissue pressure relative to subarachnoid pressure and decreases the gradient for CSF efflux. An established or chronic pseudomeningocele is thought of as extradural CSF leakage, which is completely contained within the body and presents with no CSF drainage through the site of incision. This procedure may reduce the need for surgical intervention.

There is difference of opinion regarding the level of blood patch application and the amount of blood to be injected. The blood patch can be injected at the same level as the laminectomy operation or at the epidural space one level above.^[19] In postsurgical pseudomeningoceles, it is more practical to localize the epidural space at a level higher than the laminectomy and introduce the blood while the patient is maintained in the sitting position. The injected blood travels downward due to gravity and creates a clot adherent, directly patching hole in it and preventing CSF leak. The most common approach is to locate the epidural space at a level above operation site. The volume of blood

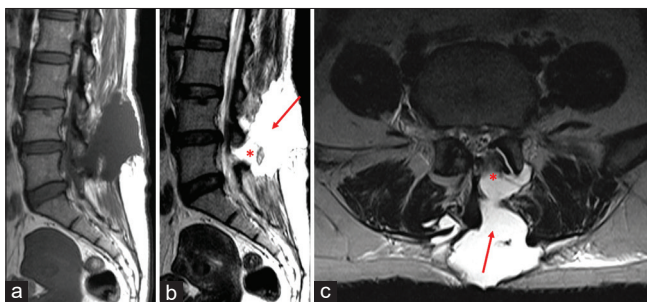


Figure 1: Postoperative pseudomeningocele – magnetic resonance imaging of the patient showing post-L4–L5 discectomy pseudomeningocele measuring 5 cm × 4.2 cm × 4 cm, ill-defined cerebrospinal fluid collection extending into the paraspinal region on the left side. *Dural defect, Arrow: Cerebrospinal fluid collection. Sagittal T1-weighted (a), Sagittal T2-weighted (b), Axial T2-weighted (c)

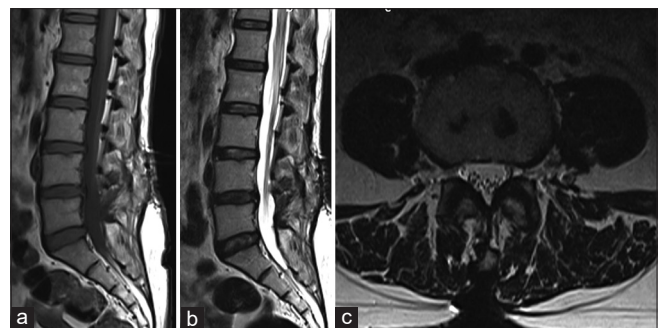


Figure 2: Magnetic resonance imaging of the patient showing complete resolution of pseudomeningocele at 1-year follow-up. Sagittal T1-weighted (a), Sagittal T2-weighted (b), Axial T2-weighted (c)

injected also varies from 5 to 30 ml in different studies in the literature. In our patient, we injected 10 ml of blood in the cavity after CSF aspiration from pseudomeningocele and another 10 ml at one level above the laminectomy. The CSF aspiration and blood patch at the level of pseudomeningocele may help in healing and fibrosis.

Although EBP is still not an established procedure for postlumbar surgery pseudomeningocele, it is worth trying this procedure to avoid second surgery as it may sometimes be unsuccessful. Because of this reason in our case as the patient had a pseudomeningocele but without neurologic deficit, we decided to try epidural patch. Our patient was completely symptom free postprocedure and after 1 year on follow-up visit. Furthermore, the MRI showed complete resolution of pseudomeningocele at 1-year follow-up. It can be safely concluded that for all cases of pseudomeningoceles postspinal surgery, we go for USG-guided epidural blood patch application before opting for re-exploration.

Declaration of patient consent

The authors certify that they have obtained all appropriate patient consent forms. In the form, the patient has given her consent for her images and other clinical information to be reported in the journal. The patient understands that name and initials will not be published and due efforts will be made to conceal identity, but anonymity cannot be guaranteed.

Financial support and sponsorship

Nil.

Conflicts of interest

There are no conflicts of interest.

References

1. Mayfield FH, Kurokawa K. Watertight closure of spinal dura mater. Technical note. *J Neurosurg* 1975;43:639-40.
2. Rodriguez-Olaverri JC, Zimick NC, Merola A, Vicente J, Rodriguez J, Tabuenca A, *et al.* Comparing the clinical and radiological outcomes of pedicular transvertebral screw fixation of the lumbosacral spine in spondylolisthesis versus unilateral transforaminal lumbar interbody fusion (TLIF) with posterior fixation using anterior cages. *Spine (Phila Pa 1976)* 2008;33:1977-81.
3. Swanson HS, Fincher EF. Extradural arachnoidal cysts of traumatic origin. *J Neurosurg* 1947;4:530-8.
4. Teplick JG, Peyster RG, Teplick SK, Goodman LR, Haskin ME. CT identification of postlaminectomy pseudomeningocele. *AJR Am J Roentgenol* 1983;140:1203-6.
5. Couture D, Branch CL Jr. Spinal pseudomeningoceles and cerebrospinal fluid fistulas. *Neurosurg Focus* 2003;15:E6.
6. Maycock NF, van Essen J, Pfitzner J. Post-laminectomy cerebrospinal fluid fistula treated with epidural blood patch. *Spine (Phila Pa 1976)* 1994;19:2223-5.
7. Thomas A, Shetty AP, Rajasekaran S. Abducens nerve palsy associated with pseudomeningocele after lumbar disc surgery: A case report. *Spine (Phila Pa 1976)* 2012;37:E511-3.
8. Leis AA, Leis JM, Leis JR. Pseudomeningoceles: A role for mechanical compression in the treatment of dural tears. *Neurology* 2001;56:1116-7.
9. Waisman M, Schweppe Y. Postoperative cerebrospinal fluid leakage after lumbar spine operations. Conservative treatment. *Spine (Phila Pa 1976)* 1991;16:52-3.
10. Solomon P, Sekharappa V, Krishnan V, David KS. Spontaneous resolution of postoperative lumbar pseudomeningoceles: A report of four cases. *Indian J Orthop* 2013;47:417-21.
11. Stambough JL, Templin CR, Collins J. Case report. Subarachnoid drainage of an established or chronic pseudomeningocele. *J Spinal Disord* 2000;13:39-41.
12. Hawk MW, Kim KD. Review of spinal pseudomeningoceles and cerebrospinal fluid fistulas. *Neurosurg Focus* 2000;9:e5.
13. Eismont FJ, Wiesel SW, Rothman RH. Treatment of dural tears associated with spinal surgery. *J Bone Joint Surg Am* 1981;63:1132-6.
14. Weng YJ, Cheng CC, Li YY, Huang TJ, Hsu RW. Management of giant pseudomeningoceles after spinal surgery. *BMC Musculoskelet Disord* 2010;11:53.
15. Gupta R, Narayan S. Post-operative Pseudomeningocele after spine surgery: Rare cause of failed back syndrome. *Iran J Neurosurg* 2016;2:15-8.
16. Rudrappa S, Govindasamy R, Tukkapuram VR, Gopal S. Lumbar pseudomeningocele presenting as decerebrate rigidity – A rare case entity. *Int J Surg Case Rep* 2018;47:41-4.
17. Lauer KK, Haddox JD. Epidural blood patch as treatment for a surgical durocutaneous fistula. *J Clin Anesth* 1992;4:45-7.
18. Srilomsak P, Okuno K, Sakakibara T, Wang Z, Kasai Y. Giant pseudomeningocele after spinal surgery: A case report. *World J Orthop* 2012;3:109-13.
19. Fridley JS, Jea A, Glover CD, Nguyen KP. Symptomatic postsurgical cerebrospinal fluid leak treated by aspiration and epidural blood patch under ultrasound guidance in 2 adolescents. *J Neurosurg Pediatr* 2013;11:87-90.
20. Akbar RA, Khan AA, Fernandes GM, Ahmed Mohamed AZ, Elsouhly A, Ali YO. Spontaneous intracranial hypotension and its management with a cervical epidural blood patch: A case report. *Am J Case Rep* 2020;21:e925986.
21. Sandwell S, Walter K, Westesson PL. Pseudomeningocele aspiration and blood patch effectively treats positional headache associated with postoperative lumbosacral pseudomeningocele. *Spine (Phila Pa 1976)* 2017;42:1139-44.