

Spontaneous Resolution of Brain Abscess by Rupture into Middle Ear

Abstract

Intracranial abscesses are uncommon, serious, and life-threatening infections, with mortality rate of about 15%. Surgical treatment is warranted for an abscess size more than 2.5 cm. We present an unusual case with spontaneous resolution of a large abscess through the middle ear without any surgical intervention.

Keywords: *Intracranial abscess, nonsurgical management, spontaneous resolution*

Introduction

Intracranial abscesses are uncommon, serious, and life-threatening infections, with mortality rate of about 15%. Surgical treatment is warranted for an abscess size more than 2.5 cm. We present an unusual case with spontaneous resolution of a large abscess through the middle ear without any surgical intervention.

Case Report

A 17-year-old female reported to the hospital with history of left ear discharge from childhood along with decreased hearing from the left ear. She was diagnosed with chronic suppurative otitis media and underwent left Modified Radical Mastoidectomy 10 years ago at a local hospital with no postoperative complications. She developed fever, intermediate to high grade with pus discharge from her left ear 2 months before reporting to our institute. She also developed headache, which was gradually progressive in nature, along with vomiting and altered sensorium for one week. A non contrast CT scan of the head dated 18th January, 2017; done at a local hospital on revealed obstructive hydrocephalus with periventricular ooze [Figure 1a]. A contrast enhanced scan done at the same hospital on 18th January, 2017 was suggestive of ring enhancing lesion in the left cerebellar hemisphere 2.5 × 3.8 cm, with perilesional edema [Figure 2a]. She was started on intra venous antibiotics at the same local hospital. Following this, she had copious ear discharge from her left ear,

This is an open access journal, and articles are distributed under the terms of the Creative Commons Attribution-NonCommercial-ShareAlike 4.0 License, which allows others to remix, tweak, and build upon the work non-commercially, as long as appropriate credit is given and the new creations are licensed under the identical terms.

For reprints contact: reprints@medknow.com

2 days after starting treatment, following which her symptoms improved. When she reported to our institute, she still had fever of low grade variety with intermittent pus discharge, but no features suggestive of raised intra cranial pressure. Repeat CT and MRI scanning was done at our institute in February 2017, which showed decrease in ventricular size as compared to the previous scan [Figure 1b] along with resolution of the abscess [Figure 2b]. There was evidence of destruction of the sinodural plate and lateral wall of left mastoid air cells. Conservative management of the patient was continued with intravenous antibiotics and she was referred to otology department for further management.

Discussion

Brain abscess is a focal collection within the brain parenchyma, which can arise as a complication of a variety of infections, trauma, or surgery. Intracranial abscesses can originate from infection of contiguous structures (e.g., otitis media, dental infection, mastoiditis, and sinusitis) secondary to hematogenous spread from a remote site (especially in patients with cyanotic congenital heart disease), after skull trauma or surgery, and rarely, following meningitis. The most frequent organism causing brain abscess is *Streptococcus* followed by *Staphylococcus*.^[1] Unsafe chronic suppurative otitis media is usually characterized by the presence of cholesteatoma, which by virtue of its bone-eroding properties causes a variety of extracranial and intracranial complications.

How to cite this article: Agrawal M, Phalak M, Panda S, Kale SS. Spontaneous resolution of brain abscess by rupture into middle ear. *Asian J Neurosurg* 2019;14:1011-2.

**Mohit Agrawal,
Manoj Phalak,
Smriti Panda¹,
Shashank Sharad
Kale**

*Departments of Neurosurgery
and Gamma Knife and
¹Otorhinolaryngology, All India
Institute of Medical Sciences,
New Delhi, India*

Address for correspondence:

*Dr. Manoj Phalak,
Department of Neurosurgery
and Gamma Knife,
Room No. 720, Neurosciences
Centre, All India Institute of
Medical Sciences,
New Delhi, India.
E-mail: manojphalak@gmail.
com*

Access this article online

Website: www.asianjns.org

DOI: 10.4103/ajns.AJNS_85_18

Quick Response Code:



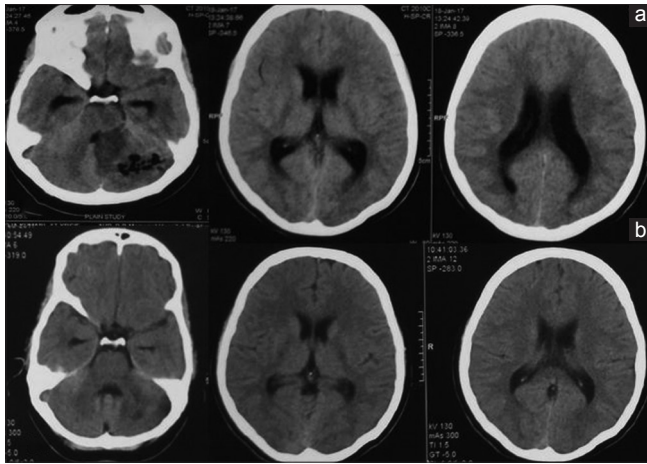


Figure 1: (a) NCCT Head showing 4th ventricular obstruction with obstructive hydrocephalus. (b) Resolution of the hydrocephalus

The intracranial complications are a result of direct spread or thrombophlebitis of communicating veins.^[2] Before the abscess has become encapsulated and localized, antimicrobial therapy, accompanied by measures to control increasing intracranial pressure, is essential. Once an abscess has formed, surgical excision or drainage combined with prolonged antibiotics (usually 4–8 weeks) remains the treatment of choice. Abscesses larger than 2.5 cm are excised or aspirated, while those smaller than 2.5 cm or which are at the cerebritis stage are aspirated for diagnostic purposes only. Although surgical intervention remains an essential treatment, selected patients may respond to antibiotics alone.^[3,4] Spontaneous drainage of the abscess has only been reported once before through a similar mechanism via the middle ear by Kumar *et al.* in 1998.^[5] This will be the second such case reported in world literature. The abscess followed the path of least resistance and spontaneously evacuated, resulting in resolution of the symptoms of raised intracranial pressure of the patient. Such a unique mechanism of resolution of a life-threatening condition is interesting and will increase our understanding of the management of rare brain abscesses.

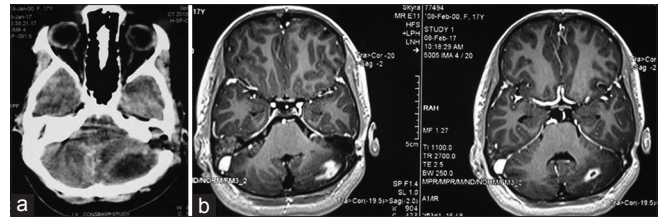


Figure 2: (a) Contrast-enhanced computed tomography head shows ring enhancing lesion in the left cerebellar hemisphere with evidence of mastoid destruction. (b) Postsymptom resolution Contrast-enhanced magnetic resonance imaging reveals resolution of the abscess with relief in 4th ventricular obstruction

Declaration of patient consent

The authors certify that they have obtained all appropriate patient consent forms. In the form the patient(s) has/have given his/her/their consent for his/her/their images and other clinical information to be reported in the journal. The patients understand that their names and initials will not be published and due efforts will be made to conceal their identity, but anonymity cannot be guaranteed.

Financial support and sponsorship

Nil.

Conflicts of interest

There are no conflicts of interest.

References

1. Brouwer MC, Coutinho JM, van de Beek D. Clinical characteristics and outcome of brain abscess: Systematic review and meta-analysis. *Neurology* 2014;82:806-13.
2. Hafidh MA, Keogh I, Walsh RM, Walsh M, Rawluk D. Otogenic intracranial complications. A 7-year retrospective review. *Am J Otolaryngol* 2006;27:390-5.
3. Cavuşoglu H, Kaya RA, Türkmenoglu ON, Colak I, Aydin Y. Brain abscess: Analysis of results in a series of 51 patients with a combined surgical and medical approach during an 11-year period. *Neurosurg Focus* 2008;24:E9.
4. Honda H, Warren DK. Central nervous system infections: Meningitis and brain abscess. *Infect Dis Clin North Am* 2009;23:609-23.
5. Kumar R, Sharma R, Tyagi I. Spontaneous evacuation of cerebellar abscess through the middle ear. A case report. *Neurosurg Rev* 1998;21:66-8.