

Patent Persistent Fibrous Tract in a Patient with Disconnected Lumboperitoneal Shunt

Abstract

Disconnection of proximal or distal catheter is seen more frequently in the complication of the lumboperitoneal (LP) shunt. A connective tissue sheath that forms around the peritoneal catheter of silicone shunt tubing is a normal biological response to foreign material. The literature did not establish whether the disconnected LP shunt can allow passage of cerebrospinal fluid (CSF) through the disconnected portion. However, proof of the passage of CSF through these sheaths has been reported in only one published study to date. We present a case of a young patient with disconnected LP shunt who reported patent persistent fibrous tract around the tube shunt. In conclusion, asymptomatic patients with shunt disconnection should be evaluated with shuntography for patency of fibrous sheath before removal of the shunt to avoid the possible complications.

Keywords: *Malfunction, patent persistent fibrous tract, rare*

Introduction

There is a huge advancement in the evaluation and the treatment of hydrocephalus over several years after the introduction of the effective cerebrospinal fluid (CSF) shunting methods.^[1] Despite the development and improvement of these diversion methods, there are various complications of the shunt system such as catheter occlusion, disconnection, migration, fracture, and outgrowth.^[2-4] When there are mechanical problems with the shunt but the patients are asymptomatic or minimally symptomatic and the cranial computed tomography (CT) scan does not reveal an active ventricular dilatation, the decision of treatment becomes difficult. It has postulated that patent fibrous tract allows passage of the CSF through disconnected outgrowth distal catheter.^[5,6] It has been asserted that in these situations, CSF passes through the fibrous sheath around the catheter, but this has not been definitively proved in previous reports. We present here a case of a 17-year-old boy who had lumboperitoneal (LP) shunt done for the postoperative pseudomeningocele which occurred postsuboccipital decompression for Arnold–Chiari type I malformation. The patient had a disconnection of the LP shunt

and was asymptomatic, so the LP shunt was removed. Later, the patient developed symptoms of increased intracranial pressure (ICP) and we had to place LP shunt again.

Case Report

A 17-year-old man was performed LP shunt at 12 years old due to pseudomeningocele from suboccipital decompression in Arnold–Chiari type I malformation [Figure 1a and b]. LP shunt revision was performed 8 months after because of shunt malfunction. He recovered so completely that he again started his favorite sports (Kendo; Japanese fencing). He frequently bent his back while performing Kendo. Then, he complained about low back pain after revision. Radiographic studies demonstrated that the proximal catheter disconnected [Figure 2] and CSF could not aspirate from the flushing device. The LP shunt removal was performed, and subcutaneous mass from CSF collection was observed after the closing of the proximal fibrous tract by tobacco-bag suture [Figure 3]. Collagen fibers, fat tissue, and small vessels were also observed in that fibrous tract [Figure 4]. The patient complained about a severe headache after the procedure. The lumbar puncture revealed the high pressure of 40 cmH₂O. The patient had undergone CT scan and

**Rajan Kumar Sharma^{1,2},
Kiyoshi Takagi³,
Yasuhiro Yamada²,
Tsukasa Kawase²,
Yoko Kato²**

¹Department of Neurosurgery, National Academy of Medical Sciences, Bir Hospital, Kathmandu, Nepal, ²Department of Neurosurgery, Banbuntane Hotokukai Hospital, Fujita Health University, Nagoya, ³Department of Neurosurgery, Chiba Kashiwa Tanaka Hospital, Kashiwa, Japan

Address for correspondence:

Dr. Rajan Kumar Sharma,
Department of Neurosurgery,
National Academy of Medical
Sciences, Bir Hospital,
Kathmandu, Nepal.
E-mail: rajanktm58@gmail.com

Access this article online

Website: www.asianjns.org

DOI: 10.4103/ajns.AJNS_91_19

Quick Response Code:



How to cite this article: Sharma RK, Takagi K, Yamada Y, Kawase T, Kato Y. Patent persistent fibrous tract in a patient with disconnected lumboperitoneal shunt. *Asian J Neurosurg* 2019;14:935-7.

This is an open access journal, and articles are distributed under the terms of the Creative Commons Attribution-NonCommercial-ShareAlike 4.0 License, which allows others to remix, tweak, and build upon the work non-commercially, as long as appropriate credit is given and the new creations are licensed under the identical terms.

For reprints contact: reprints@medknow.com

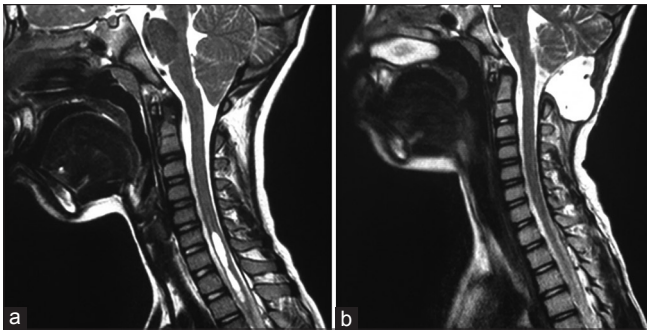


Figure 1: (a) Case of Arnold-Chiari malformation type I, (b) pseudomeningocele from suboccipital decompression in the Arnold-Chiari type I malformation

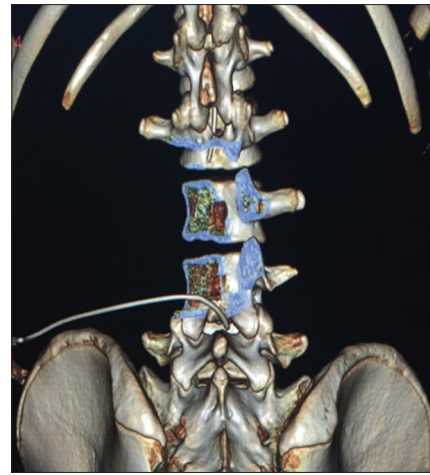

Figure 2: Proximal catheter of lumboperitoneal shunt disconnection

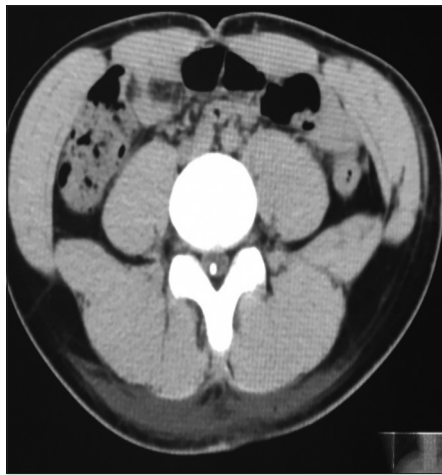


Figure 3: Closing of the proximal fibrous tract by tobacco-bag suture

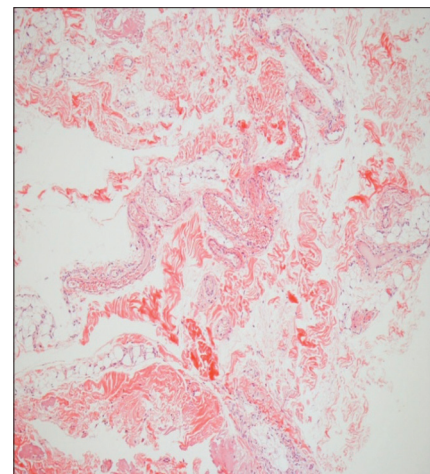


Figure 4: Collagen fibers, fat tissue, and small vessels observed in that fibrous tract

found that there is disconnection of the LP shunt. We found subcutaneous mass containing CSF, and after removal of this fibrous tract, the patient became symptomatic which suggest that the fibrous tract is still functioning. It is clinicoradiological assessment of the function of the fibrous tract. The emergency LP shunt was done and symptoms of the patient disappear instantly [Figure 5]. The patient recovered completely and showed no signs of shunt malfunction. This also denotes that when the patient is young and indulges in excessive sports activities, there is a high chance of shunt malfunction with the LP shunt as we could see in this case. Ventriculoatrial shunt is a good and proven alternative for the LP shunt malfunction.

Discussion

Use of silastic catheters for the use in medicine was in the era of 1950s.^[7] The material silicon elastomer has high flexibility, chemical stability, and nontoxic properties which made them the preferred choice for the use in the shunt system. The main problem with this shunt is lipophilicity which causes gradual degradation and deterioration of the shunt system. Shunt revision is the choice for a symptomatic patient with shunt malfunction; however, if the patient is asymptomatic with arrested

hydrocephalus, then it is a challenging task. As a policy for the management of arrested hydrocephalus we need to keep the patient in supervision without revision of the shunt but sometimes it becomes catastrophic. There are two possible, but not definitive, explanations for normal ICP in the shunt malfunction; patient one can be the arrested hydrocephalus with a nonfunctional shunt, and the second can be explained with a functional subcutaneous fibrous tract. The development of pericatheter subcutaneous reaction and fibrosis around the silicon shunt catheters has been documented histologically in two patients.^[8] Fibrosis and tethering to the skin can cause discomfort to the patients. The term “tract fibrosis” denotes for the findings of inflammatory tissue that results from scarring and/or calcinosis surrounding the catheter. These fibrotic tissues usually take a tubular shape, mirroring that of the catheter’s tube structure, so the term is coined tract fibrosis.^[9] Clyde and Albright mentioned evidence for the patent fibrous tract in fractured, outgrown, or disconnected ventriculoperitoneal (VP) shunts and they mentioned two case reports of this patent fibrous tract.^[5] Langmoen *et al.*

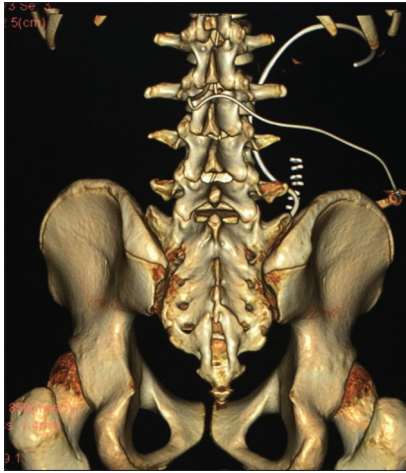


Figure 5: Lumboperitoneal shunt revision

noticed delayed hydrocephalus in one patient who had been asymptomatic after the removal of the fractured distal shunt catheter in the follow-up period.^[10] Rekate *et al.* mentioned two patients with Arnold–Chiari malformation who had a cardiac and or respiratory arrest in 9 months and 5 years after shunt removal or ligation of the disconnected or the outgrown shunt.^[6] Kazan *et al.* discussed the four cases which have a patent subcutaneous fibrous tract in children with VP shunt.^[11] Nakano *et al.* reported a fibrous tract formed around the peritoneal catheter which communicated with the lactiferous duct.^[12] Many spina bifida patients have surveillance scoliosis radiographs which may identify an incidental withdrawn peritoneal catheter. Clyde and Albright estimated that arrested hydrocephalus occurred in approximately 5% of patients with meningomyelocele with shunts. Our findings supported the theory that opening ICP might be normal with the existence of a patent fibrous tract; however, when we removed the nonfunctioning LP shunt and the fibrous tissue, the patient became symptomatic and we had to place shunt again.

Conclusion

Even though the shuntography cannot be performed, the clinical course can be strongly indicated that the fibrous tract remained patent after the shunt tube disconnection. LP shunt is a popular treatment for hydrocephalus treatment and the proximal catheter disconnection is not so frequently found. A shuntography can identify functioning of shunt and guide management; we should perform shuntography before removal the shunt even though the shunt is disconnected.

Declaration of patient consent

The authors certify that they have obtained all appropriate patient consent forms. In the form the patient(s) has/have given his/her/their consent for his/her/their images and other clinical information to be reported in the journal. The patients understand that their names and initials will not be published and due efforts will be made to conceal their identity, but anonymity cannot be guaranteed.

Financial support and sponsorship

Nil.

Conflicts of interest

There are no conflicts of interest.

References

1. Amacher AL, Wellington J. Infantile hydrocephalus: Long-term results of surgical therapy. *Childs Brain* 1984;11:217-29.
2. Feletti A, Avella D, Wikkels C, Klinge P, Hellström P. Ventriculoperitoneal Shunt Complications in the European Idiopathic Normal Pressure Hydrocephalus Multicenter Study. *Oper Neurosurg* 2018;1-6.
3. Davidson RI. Peritoneal bypass in the treatment of hydrocephalus: Historical review and abdominal complications. *J Neurol Neurosurg Psychiatry* 1976;39:640-6.
4. Chumas PD, Kulkarni AV, Drake JM, Hoffman HJ, Humphreys RP, Rutka JT. Lumboperitoneal shunting: A retrospective study in the pediatric population. *Neurosurgery* 1993;32:376-83.
5. Clyde BL, Albright AL. Evidence for a patent fibrous tract in fractured, outgrown, or disconnected ventriculoperitoneal shunts. *Pediatr Neurosurg* 1995;23:20-5.
6. Rekate HL, Nulsen FE, Mack HL, Morrison G. Establishing the diagnosis of shunt independence. *Monogr Neural Sci* 1982;8:223-6.
7. Keucher TR, Mealey J Jr. Long-term results after ventriculoatrial and ventriculoperitoneal shunting for infantile hydrocephalus. *J Neurosurg* 1979;50:179-86.
8. Sugar O, Bailey OT. Subcutaneous reaction to silicone in ventriculoperitoneal shunts. Long-term results. *J Neurosurg* 1974;41:367-71.
9. Lester L, Sharon L, David L, Lee PN, Colum N, Wan TS. Late pediatric ventriculoperitoneal shunt failures: A Singapore tertiary institutions experience. *Neurosurg Focus* 2016;41:7.
10. Langmoen IA, Lundar T, Vatne K, Hovind KH. Occurrence and management of fractured peripheral catheters in CSF shunts. *Childs Nerv Syst* 1992;8:222-5.
11. Kazan S, Açıkbay C, Rahat O, Tuncer R. Proof of the patent subcutaneous fibrous tract in children with V-P shunt malfunction. *Childs Nerv Syst* 2000;16:351-6.
12. Nakano A, Tani E, Sato M, Shimizu Y. Cerebrospinal fluid leakage from the nipple after ventriculoperitoneal shunt: Case report. *Surg Neurol* 1994;42:224-6.