

# Primary Central Nervous System Lymphoma Involving Entire Ventricular System

## Abstract

Primary central nervous system lymphoma (PCNSL) is a rare tumor that accounts for <1%–4% of primary CNS tumor.<sup>[1]</sup> PCNSLs are class of non-Hodgkin's lymphomas which are primarily of diffuse large B-cell origin (90%), with remaining being T-cell lymphoma (10%). Author report a rare case of PCNSL presenting as an intracranial mass involving the entire ventricular system, in an immunocompetent 36-year-old male with severe headache, decreased vision, and unsteady gait. The diagnosis was obtained by histopathological and subsequent immunohistochemistry.

**Keywords:** *Intraventricular lymphoma, primary central nervous system lymphoma*

## Introduction

Before the emergence of HIV/AIDS, primary central nervous system lymphoma (PCNSL) was most often seen either in the setting of known immunocompromised status or with advanced age. After emergence of the AIDS epidemic was mirrored by a rise in the incidence of PCNSL, and it soon became an AIDS-defining illness. The majority of the PCNSL cases present as solitary masses in cerebral hemisphere, thalamus, basal ganglia, and periventricular region. Only a few cases of PCNSL involving ventricular system have been reported in the literature. Our case involved the whole ventricular system (bilateral lateral, third, and fourth ventricle). To the best of our knowledge, only one case in the literature has been reported before this in which PCNSL involved the whole ventricular system.<sup>[2]</sup>

## Case Report

A 36-year-old male patient admitted with chief complaints of headache, decreased vision, and difficulty in walking for 15 days. General physical examination of the patient was unremarkable. On neurological examination, the higher mental function was normal. On cranial nerve examination, the patient had bilateral papilledema, motor, and sensory examination was normal. The patient had the presence of cerebellar sign bilaterally.

This is an open access journal, and articles are distributed under the terms of the Creative Commons Attribution-NonCommercial-ShareAlike 4.0 License, which allows others to remix, tweak, and build upon the work non-commercially, as long as appropriate credit is given and the new creations are licensed under the identical terms.

For reprints contact: reprints@medknow.com

Lymphoreticular system examination was unremarkable. On further evaluation, routine blood investigation including HIV was done which was nonreactive. Computed tomography (CT) scan showed the presence of multiple lobulated intensely enhancing intraventricular space occupying lesion in lateral, third, and fourth ventricle [Figure 1a]. Magnetic resonance imaging (MRI) brain of the same patient showed that the presence of multiple solid lobulated enhancing masses of variable size is seen involving lateral, third, fourth ventricles, and infiltrating into the periventricular white matter in bilateral frontal and parietal lobe [Figure 1b]. Magnetic resonance spectroscopy showed lactate and choline peaks elevated, and N-acetylaspartate peak was reduced suggestive of mitotic pathology. Screening of the whole spine with MRI was done which did not show any pathology. CT scan abdomen and thorax were unremarkable. The patient was planned for tumor decompression from fourth ventricle keeping in view possibility of early brainstem compression as well as obtaining a tissue diagnosis. Midline suboccipital craniectomy with tumor decompression was done. Intraoperatively, the tumor was grayish white, suckable, and highly vascular. Histopathological examination of the submitted tissue was suggestive of round cell tumor. The biopsy submitted showed cerebellar tissue with diffusely

**Hemant Kumar,  
Achal Sharma,  
Vinod Sharma,  
Shashi Singhvi<sup>1</sup>**

*Department of Neurosurgery,  
S.M.S. Medical College,  
Department of Pathology,  
Patho Care and Research  
Centre, S.M.S. Medical College,  
Jaipur, Rajasthan, India*

**Address for correspondence:**  
Dr. Hemant Kumar,  
Department of Neurosurgery,  
S.M.S. Medical College,  
Jaipur, Rajasthan, India.  
E-mail: hemantvarshney06@  
gmail.com

### Access this article online

Website: [www.asianjns.org](http://www.asianjns.org)

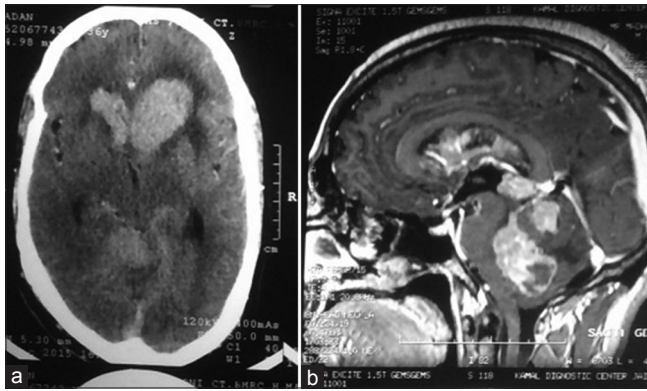
DOI: 10.4103/ajns.AJNS\_94\_16

### Quick Response Code:



**How to cite this article:** Kumar H, Sharma A, Sharma V, Singhvi S. Primary central nervous system lymphoma involving entire ventricular system. *Asian J Neurosurg* 2020;15:126-7.

**Submission:** 08-03-2016      **Accepted:** 29-03-2017  
**Published:** 25-02-2020



**Figure 1:** (a) Computed tomography scan showing multilobulated homogenous contrast-enhancing mass in lateral ventricles and fourth ventricle. (b) Magnetic resonance imaging showing multilobulated homogenous enhancing mass in lateral, third, and fourth ventricles

infiltrating large neoplastic lymphocyte-like round cell with brisk mitotic activity. The cells are large; nuclei are round to oval with predominant nucleoli. Mitotic and apoptotic activity are seen frequently [Figure 2a]. On immunomarker, the cells were positive for Pax5, leukocyte common antigen (CD45), CD20, with Ki-67 (MIB index) being approximately 80%. The tumor cells were negative for synaptophysin, EMA, Alk1, NF, p53, TDT, CD3, CD 4, CD8, CD19, CD99, GFAP, and S100 [Figure 2b]. Immunomarkers were for non-Hodgkin's lymphoma type, diffuse large B-cell lymphoma.

## Discussion

CNS lymphomas are highly chemo- and radiation-sensitive tumors and management of these tumors is histopathological confirmation by either open or stereotactic biopsy followed by chemotherapy or radiotherapy or both. Primary intraventricular lymphomas are rare entity.<sup>[3-5]</sup> Only a few cases of intraventricular PCNSL have been reported in the literature, of which three cases were in the fourth ventricle,<sup>[3,6-8]</sup> four cases were in the third ventricle,<sup>[3,9,10]</sup> and three cases were in the lateral ventricle,<sup>[11,12]</sup> while only one case as per literature available was identified with simultaneous involvement of the lateral and fourth ventricles. CNS lymphoma is known to present in many different forms. As described, in our case report, PCNSL should be considered as one of the differentials diagnosis of diffuse intraventricular masses. So that, operative interventions can be avoided and biopsy either stereotactic or open should be obtained followed by chemotherapy and radiotherapy.

## Financial support and sponsorship

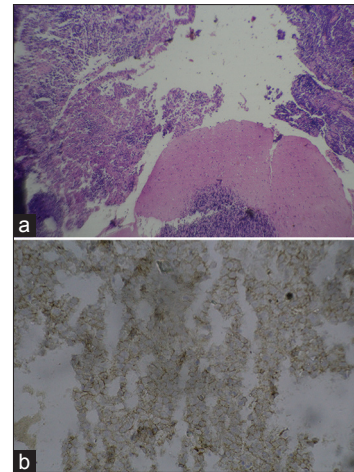
Nil.

## Conflicts of interest

There are no conflicts of interest.

## References

1. Rubenstein J, Ferreri AJ, Pittaluga S. Primary lymphoma of



**Figure 2:** (a) Cerebellar tissue with diffusely infiltrating sheath of large neoplastic cells with necrosis (HPE,  $\times 10$ ). (b) Diffuse membrane staining of CD20 (HPE,  $\times 60$ )

the central nervous system: Epidemiology, pathology and current approaches to diagnosis, prognosis and treatment. *Leuk Lymphoma* 2008;49 Suppl 1:43-51.

- Qin JZ, Wu YK, Yang ZJ, Lv J, Dang YY, Zhang HT, *et al.* Endoscopic biopsy of a B-cell lymphoma involving the entire ventricular system: A case report. *Exp Ther Med* 2016;11:325-7.
- Cecchi PC, Billio A, Colombetti V, Rizzo P, Ricci UM, Schwarz A. Primary high-grade B-cell lymphoma of the choroid plexus. *Clin Neurol Neurosurg* 2008;110:75-9.
- Park SW, Yoon SH, Cho KG. An endoscopically proven ventriculitis-type, cyst-like intraventricular primary lymphoma of the central nervous system. *Acta Neurochir (Wien)* 2006;148:981-4.
- Bühning U, Herrlinger U, Krings T, Thiex R, Weller M, Küker W. MRI features of primary central nervous system lymphomas at presentation. *Neurology* 2001;57:393-6.
- Haegelen C, Riffaud L, Bernard M, Morandi X. Primary isolated lymphoma of the fourth ventricle: Case report. *J Neurooncol* 2001;51:129-31.
- Hill CS, Khan AF, Bloom S, McCartney S, Choi D. A rare case of vomiting: Fourth ventricular B-cell lymphoma. *J Neurooncol* 2009;93:261-2.
- Werneck LC, Hatschbach Z, Mora AH, Novak EM. Meningitis caused by primary lymphoma of the central nervous system. Report of a case. *Arq Neuropsiquiatr* 1977;35:366-72.
- Kelley TW, Prayson RA, Barnett GH, Stevens GH, Cook JR, Hsi ED. Extranodal marginal zone B-cell lymphoma of mucosa-associated lymphoid tissue arising in the lateral ventricle. *Leuk Lymphoma* 2005;46:1423-7.
- Jung TY, Jung S, Lee MC, Lee KH. Extranodal marginal zone B-cell lymphoma mimicking meningioma in lateral ventricle: A case report and possible pathogenesis. *J Neurooncol* 2006;80:63-7.
- Terasaki M, Abe T, Tajima Y, Fukushima S, Hirohata M, Shigemori M. Primary choroid plexus T-cell lymphoma and multiple aneurysms in the CNS. *Leuk Lymphoma* 2006;47:1680-2.
- Bogdahn U, Bogdahn S, Mertens HG, Dommasch D, Wodarz R, Wunsch PH, *et al.* Primary non-Hodgkin's lymphomas of the CNS. *Acta Neurol Scand* 1986;73:602-14.