

# Iatrogenic Seizures during Intraoperative Transcranial Motor-Evoked Potential Monitoring

## Abstract

Intraoperative neurophysiological monitoring (IONM) is an important tool for early detection of inadvertent damage and guide intra-operative manipulation during complex neurosurgical procedures. However trans-cranial stimulation can evoke an iatrogenic seizure and it remains a real concern while using Tc-MEP. We report a case of intra-operative seizure during transcranial electrical stimulation for motor evoked potential monitoring in a patient without seizure disorder, who underwent surgery for thoracic intra-medullary tumor excision.

**Keywords:** *Intraoperative seizures, neurophysiological monitoring, neurosurgery, seizures, transcranial evoked potential*

## Introduction

Intraoperative neurophysiological monitoring (IONM) is an invaluable tool in the early detection of possible neurological damage. It guides intraoperative manipulation during complex neurosurgical procedures to avoid the damage and thus have better outcome. Transcranial motor-evoked potential (Tc-MEP) has evolved into one of the most favored means for safe neurosurgery. Except taking care of tongue bite and patient movement, the monitoring is considered quite benign by attending physicians and neurosurgeons. However, transcranial stimulation can evoke an iatrogenic seizure, and it remains a real concern while using Tc-MEP.

We report a case of intraoperative seizure during transcranial electrical stimulation for MEP monitoring in a patient without seizure disorder, who underwent surgery for thoracic intramedullary tumor excision.

## Case Report

A 35-year-old male patient was posted for laminectomy and intradural-extramedullary tumor excision at the thoracic vertebral level 4–5. The patient had a history of tingling sensation and weakness in both legs for 6 months and decreased sensation over the abdomen and legs for 4 months.

This is an open access journal, and articles are distributed under the terms of the Creative Commons Attribution-NonCommercial-ShareAlike 4.0 License, which allows others to remix, tweak, and build upon the work non-commercially, as long as appropriate credit is given and the new creations are licensed under the identical terms.

For reprints contact: reprints@medknow.com

He had no comorbidities or history of seizure or any other significant history. On examination, the patient was conscious, oriented with normal mentation. He had motor power of 4/5 with severe spasticity in the bilateral lower limbs with exaggerated deep tendon reflexes and bilateral extensor plantar response. Decreased sensation below D6–D7 level was also present.

The patient was planned for tumor excision in prone position with intraoperative Tc-MEP monitoring. Intubation was accomplished with fentanyl 2 µg/kg, propofol 2 mg/kg, and rocuronium 1 mg/kg. Soft bite block was inserted to prevent tongue bite and lip laceration during monitoring. Anesthesia was maintained with propofol infusion of 120–150 µg/kg/min with fentanyl infusion of 1 µg/kg/h and 40% oxygen in air to keep end-tidal carbon dioxide between 37 and 42 mmHg. Cork screw-type stimulating electrodes were placed 2 cm anterior to C3 and C4 scalp locations according to the International 10–20 System, and needle-type recording electrode was inserted in the bilateral abductor hallucis longus, extensor hallucis longus, tibialis anterior, quadriceps femoris, rectus abdominis, thenar, and hypothenar muscles.

Initial stimulation was done with a train of 8 at 275 pulse/second with single pulse duration of 75 µs with biphasic polarity and baseline responses were achieved

**How to cite this article:** Sokhal S, Goyal K, Sokhal N, Kumar N, Kedia S. Iatrogenic seizures during intraoperative transcranial motor-evoked potential monitoring. *Asian J Neurosurg* 2019;14:967-9.

**Suman Sokhal,  
Keshav Goyal,  
Navdeep Sokhal,  
Niraj Kumar,  
Shweta Kedia<sup>1</sup>**

*Department of Neuroanaesthesiology and Critical Care, Neurosciences Centre, All India Institute of Medical Sciences, <sup>1</sup>Department of Neurosurgery, All India Institute of Medical Sciences, New Delhi, India*

### Address for correspondence:

*Dr. Keshav Goyal,  
Department of Neuroanaesthesiology and Critical Care, 710, Neurosciences Centre, All India Institute of Medical Sciences, New Delhi - 110 029, India.  
E-mail: keshavgoyalster@gmail.com*

### Access this article online

**Website:** www.asianjns.org

**DOI:** 10.4103/ajns.AJNS\_96\_18

### Quick Response Code:



at 800 V [Figure 1a]. During the tumor excision, again transcranial stimulation was given. After stimuli, the patient had exaggerated contractions of all four limbs with simultaneous increased amplitude in MEP recordings in the upper limb control muscles and decreased amplitude in all lower limb muscles [Figure 1b]. Stimulation was ceased, but the contractions persisted after interruption of the stimulus. The patient was treated with 2 mg intravenous (IV) midazolam, resulting in discontinuation of seizure-like activity. Duration of seizure was 30 s. Arterial blood gases were normal throughout the procedure. No further MEP monitoring was done, and there was no recurrence of seizures. After dural closure, both infusions discontinued and the patient was taken on oxygen in nitrous (40:60) with desflurane (MAC 0.8%). After skin closure, desflurane and nitrous oxide were discontinued. Surgery took 3 h without any need of blood transfusion.

After turning the patient supine, he started breathing regularly and reversal was given. His core temperature was well maintained at 37°C, but the patient did not open eyes or respond. Arterial blood gas analysis was within normal limits. After 45 min, the patient started following commands. The patient was extubated. He was fully awake, conscious, and clinically intact with the same muscle power as preoperative period.

## Discussion

IONM is an established technique to predict any neural injury during spinal surgery. Usually, four types of IONM are used during spinal procedures: (1) Tc-MEPs, (2) somatosensory-evoked potentials, (3) pedicle screw stimulation, and (4) spontaneous and triggered electromyography.<sup>[1]</sup> Tc-MEP is one of the most widely used and reliable modalities, due to lack of averaging and effective muscle contraction to record potentials. It directly records the motor pathways as the patients are also more concerned of muscle power deficit.

However, the high voltage delivered during stimulation raises concerns for safety and thus prevention of

complications is important during MEPs monitoring. Tongue bite, lip laceration, cardiac arrhythmias, minor scalp burn, and seizures are various reported complications if stimulating criteria are within accepted range.<sup>[2]</sup>

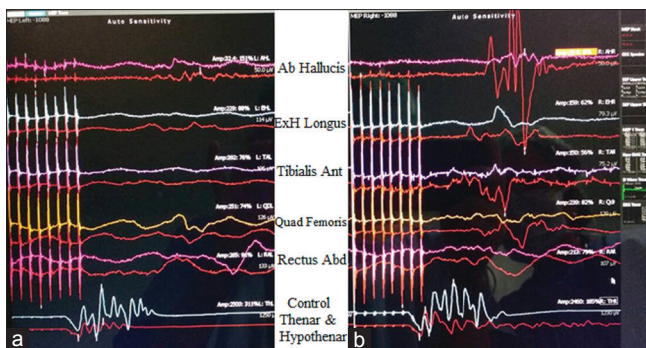
Transcranial electrical stimulation of the brain can trigger seizure-like direct cortical stimulation, but the incidence is very low. The reported incidence of intraoperative seizure during Tc-MEP range from 0.3% to 0.7%.<sup>[3]</sup> During the intraoperative period, apart from stimulus characteristics (intensity, frequency, and duration), history of epilepsy, anesthetic drugs, hypoxia, hypercarbia, hypoglycemia, electrolyte imbalances, etc., can provoke seizures.

In this case, the patient had no history of any seizure disorder in the past. The stimulation parameters for TC-MEPs were within accepted stimulation value.<sup>[4]</sup> Although we started with 200 V, the threshold was attained at 800 V which was toward upper range. The baseline MEP monitoring was uneventful; however, subsequently, the patient had an episode of generalized seizure during tumor excision with the same stimulation parameters. MEPs amplitude increased in control muscles but may be due to some exaggerated retraction at surgical site; during seizure, MEPs amplitude decreased below this level. Baseline and postseizure blood gas analysis did not show any respiratory or metabolic derangements. Seizure did not stop after discontinuing electrical stimulation but responded well to IV midazolam bolus. Afterward, having a concern of patient's safety in mind, no further stimulation was done. Propofol and fentanyl were used as maintenance agents. Propofol itself has a "proconvulsant" property as other anesthetics such as enflurane, etomidate, ketamine, and fentanyl.<sup>[5,6]</sup> Although these drugs can confound in evaluating the cause of seizure, there was no recurrence of seizure episode while continuing these drugs in the same dosage. Thus, MEP stimulation was likely an inciting factor for seizure. The patient showed a delayed emergence. This delay might have been due to effect of seizure or propofol infusion. Even with stable hemodynamics, we could not rule out nonconvulsive episodes.

Previous history of epilepsy raised intracranial pressure, cerebral lesions, convexity cranial defects, and implanted devices were relative contraindications to Tc-MEP in the past. However, now, these conditions have been successfully managed with Tc-MEP without any hazardous consequence. Every individual is different, and the benefits of MEP monitoring must be individualized and not generalized.<sup>[4,7]</sup>

## Declaration of patient consent

The authors certify that they have obtained all appropriate patient consent forms. In the form the patient(s) has/have given his/her/their consent for his/her/their images and other clinical information to be reported in the journal. The



**Figure 1: (a) Initial stimulation. (b) During seizure activity (Red color showing baseline activity. Ab hallucis – Abductor hallucis, Ex hallucis – Extensor hallucis longus, Tibialis Ant – Tibialis anterior, Quad Femoris – Quadriceps femoris, Rectus Abd – Rectus abdominus, Control muscles thenar and hypothenar)**

patients understand that their names and initials will not be published and due efforts will be made to conceal their identity, but anonymity cannot be guaranteed.

### Conclusion

Although the incidence is very low, seizure may occur during transcranial electrical stimulation for MEPs monitoring. If a seizure occurs, the risk must be balanced against the benefits to continue Tc-MEP monitoring.

### Financial support and sponsorship

Nil.

### Conflicts of interest

There are no conflicts of interest.

### References

1. Stecker MM. A review of intraoperative monitoring for spinal surgery. *Surg Neurol Int* 2012;3:S174-87.
2. MacDonald DB. Safety of intraoperative transcranial electrical stimulation motor evoked potential monitoring. *J Clin Neurophysiol* 2002;19:416-29.
3. Ulkatan S, Jaramillo AM, Téllez MJ, Kim J, Deletis V, Seidel K, *et al.* Incidence of intraoperative seizures during motor evoked potential monitoring in a large cohort of patients undergoing different surgical procedures. *J Neurosurg* 2017;126:1296-302.
4. Legatt AD, Emerson RG, Epstein CM, MacDonald DB, Deletis V, Bravo RJ, *et al.* ACNS guideline: Transcranial electrical stimulation motor evoked potential monitoring. *J Clin Neurophysiol* 2016;33:42-50.
5. Modica PA, Tempelhoff R, White PF. Pro-and anticonvulsant effects of anesthetics (Part I) *Anesth Analg* 1990;70:303-15.
6. Modica PA, Tempelhoff R, White PF. Pro-and anticonvulsant effects of anesthetics (Part II) *Anesth Analg* 1990;70:433-44.
7. Legatt AD. Current practice of motor evoked potential monitoring: Results of a survey. *J Clin Neurophysiol* 2002;19:454-60.