

## Collision Occurrence of Meningioma and Astrocytoma: A Case Report and Literature Review

### Abstract

A case of collision tumors occurring between two distinct primary brain tumors is reported. A 61-year-old female without history of radiotherapy or phakomatosis presented with progressively increasing headache and left hemiparesis. Investigation revealed a meningioma and a Grade II astrocytoma in the right frontal lobe. Simultaneous development of a meningioma and a low-grade glioma at adjacent sites is extremely rare. This is the third case reported in the literature. Some hypotheses are proposed to explain this phenomenon but most likely represent a coincidental event.

**Keywords:** Collision tumors, glioma, meningioma

### Introduction

Glioma and meningioma are the two most common primary intracranial tumors.<sup>[1]</sup> However, the simultaneous development of these tumors at adjacent sites in the same patient without a history of radiotherapy or phakomatosis is extremely rare.<sup>[2-6]</sup> The exact pathogenesis of this condition is still in controversies. Here, we present a case of collision tumors composed of a low-grade glioma and a meningioma. We discuss the challenges in obtaining an accurate preoperative diagnosis for these tumors, as well as review prior reported cases.

### Case Report

A 61-year-old female presented with 3 months of progressive headache. Neurological examination at hospitalization revealed mild left hemiparesis.

Magnetic resonance imaging of the brain showed two lesions in the right frontal lobe. One lesion was isointense on T1-weighted images and T2-weighted images and enhanced intensely after gadolinium injection. The second lesion was composed of nonenhancing cysts with a significant amount of surrounding edema [Figure 1].

Intraoperatively, the enhancing lesion was found to be an extra-axial tumor attaching to the dura mater and the other lesion was observed to be an intra-axial

tumor. Both the lesions were completely removed macroscopically. The patient improved clinically after the surgery and was discharged without any appreciable neurologic deficit. Histological examination of the extra-axial tumor revealed a fibroblastic meningioma [Figure 2] and the intra-axial lesion was diagnosed as a Grade II astrocytoma [Figure 3]. There was no histological invasion between the two tumors.

### Discussion

Since the first report in 1938, about 67 cases of simultaneous occurrence of meningioma and glioma have been reported in the literature, but the collision of two different histologic tumors in patients without prior radiation therapy or phakomatosis is extremely rare.<sup>[2-5,7]</sup> The first case of meningioma and glioma collision without a history of radiotherapy or phakomatosis was reported in 1976 by Strong *et al.*<sup>[8]</sup> We reviewed the literature and found 18 cases reported since then, including 10 males and 8 females with age ranging 12–87 years. Most of the managements for these cases were one-stage tumor removal. Histologically, most of them had high-grade gliomas. The present case is the third case of meningioma and low-grade glioma collision reported. Details of these cases are described in Table 1. Our understanding of intracranial meningioma and astrocytoma collision remains limited, but several hypotheses have been proposed.

**How to cite this article:** Truong VT, Tran DD, Dang CT. Collision occurrence of meningioma and astrocytoma: A case report and literature review. *Asian J Neurosurg* 2019;14:938-42.

**Van Tri Truong<sup>1,2</sup>,  
Duc Duy Tri Tran<sup>1,3</sup>,  
Cong Thuan Dang<sup>4</sup>**

Departments of <sup>1</sup>Neurosurgery and <sup>4</sup>Pathology, Hue University Hospital, Hue University of Medicine and Pharmacy, Hue University, Hue City, <sup>3</sup>Department of Neurosurgery, Xuyen A Hospital, Ho Chi Minh City, Vietnam, <sup>2</sup>Division of Orthopedics, Central Hospital of University of Montreal, University of Montreal, Montreal, Canada

### Address for correspondence:

Dr. Van Tri Truong,  
Department of Neurosurgery,  
Hue University Hospital, Hue  
University of Medicine and  
Pharmacy, Hue University, 41,  
Nguyen Hue Street, Hue City,  
Vietnam.  
Division of Orthopedics, Centre  
Hospitalier de l'Université  
de Montréal, University of  
Montreal, 1051, Sanguinet  
Street, Montreal, QC H2X 3E4,  
Canada.  
E-mail: drtruongtri@gmail.com

### Access this article online

**Website:** www.asianjns.org

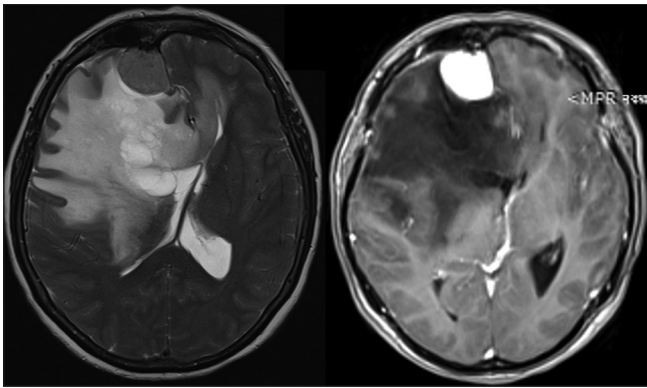
**DOI:** 10.4103/ajns.AJNS\_97\_19

### Quick Response Code:

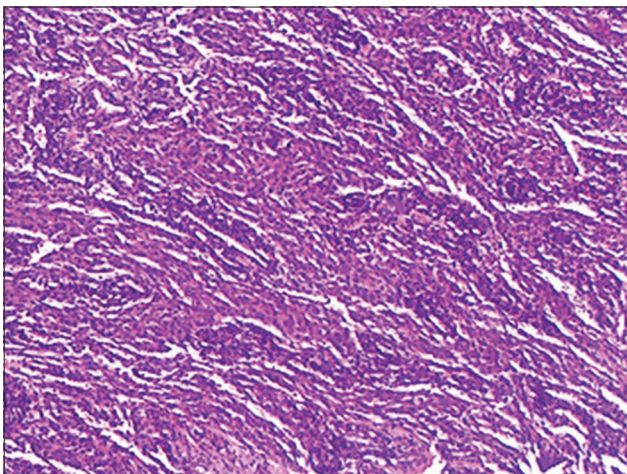


This is an open access journal, and articles are distributed under the terms of the Creative Commons Attribution-NonCommercial-ShareAlike 4.0 License, which allows others to remix, tweak, and build upon the work non-commercially, as long as appropriate credit is given and the new creations are licensed under the identical terms.

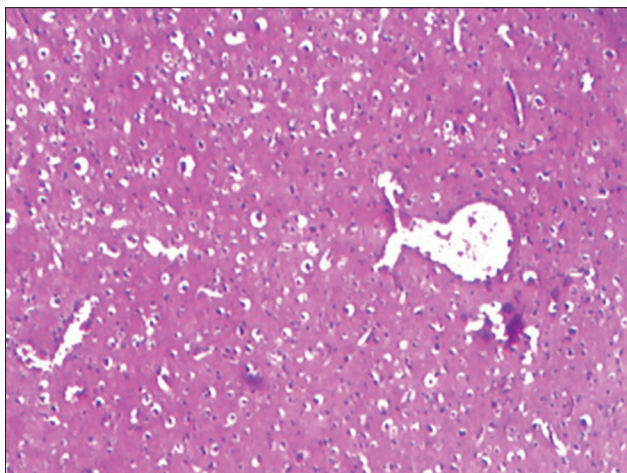
**For reprints contact:** reprints@medknow.com



**Figure 1:** Axial T2-weighted image (left) and axial T1-weighted image after gadolinium injection (right) revealed a well-defined enhanced tumor and a cystic tumor located at the right frontal lobe



**Figure 2:** H and E staining revealed a fibrous meningioma characterized by parallel fascicles of fibroblastic cells



**Figure 3:** H and E staining showed a Grade II astrocytoma tumor composed of fibrillary and gemistocytic neoplastic astrocytes on the background of the loosely structured with microcystic stroma

Some authors suggest that the initial tumor can act as an oncogenesis agent for the development of the other tumors.<sup>[4,7,21,22]</sup> The tumor growth in these cases follows the autocrine mechanism, due to the production of growth

factor and receptors for these factors. Platelet-derived growth factor (PDGF) is a likely substance.<sup>[21]</sup> It is found that three subunits of PDGF, the PDGF-AA, PDGF-BB, and PDGF-AB, are secreted by astrocytomas.<sup>[23,24]</sup> PDGF- $\beta$ -R receptor is present in meningioma, and PDGF-BB acting on these receptors is shown to stimulate meningioma cell division.<sup>[21]</sup> As a result, astrocytoma may stimulate adjacent meningioma formation in arachnoid cells by production of a common growth factor. However, this hypothesis fails to elucidate why adjacent meningioma formation does not happen in most cases of the astrocytomas.

Other authors hypothesize that meningiomas may irritate astroglial cells surrounding it, causing local cellular proliferation and eventually tumor formation.<sup>[5,19]</sup> In fact, this hypothesis is supported by a case of collision convexity meningioma and glioma reported by Vaquero *et al.* in 1990. In this case, histologically, a transient area between the meningioma and the astrocytoma was observed and two kinds of tumor cells were mixed in some areas.<sup>[19]</sup> In 2004, Drlicek *et al.* reported one case with a meningotheial meningioma WHO-Grade I located within the peripheral glioblastoma WHO-Grade IV, also supporting the above hypothesis.<sup>[16]</sup> Similarly, Prayson reported a meningioma in the sagittal sinus in the frontal lobe and a peripheral glioma invading each other pathologically.<sup>[18]</sup> However, collision tumors without histological invasion have also been reported. For example, in 2007, Nestler *et al.* reported a case of collision of a meningioma and a glioma, but the histological examination showed no invasion of the tissue between them.<sup>[14]</sup> Tugcu also reported a case of collision of a meningioma and a glioblastoma multiforme at the left parietal cortex without parenchymal invasion.<sup>[5]</sup> We also did not find any histological invasion between the two tumors in our case. This transformation hypothesis fails to explain why adjacent glial formation does not happen in most of the intracranial meningiomas. It also fails to explain the simultaneous occurrence of two distinct tumors in different brain areas.

Genetic factors are also suggested to play a role in the development of collision meningioma and glioma. In fact, a meningioma-associated tumor suppressor gene which is commonly inactivated in clinically aggressive meningiomas was found on the long arm of chromosome 14, identified as the N-myc downstream-regulated gene 2 (NDRG2).<sup>[25]</sup> A study in 2005 found that this gene was suppressed in glioblastoma tissue but expressed in normal brain tissue.<sup>[26]</sup> Thus, the suppression of NDRG2 gene may lead to the formation of meningioma and glioblastoma simultaneously. In 2015, Nestler *et al.* reported three cases of simultaneous of meningioma and glioblastoma, but specimens from two cases were examined for chromosomal aberration by conventional karyotyping as well as comparative genomic hybridization, and no common genetic aberration in tumor cells with a different histology was found.<sup>[14]</sup>

**Table 1: Reported cases of collision of meningioma and glioma**

Number of cases	Author, year	Age/sex	Meningioma Location	Glioma location	Clinical presentation	Imaging study	Management	Histology
1	Zhang <i>et al.</i> , 2018 <sup>[7]</sup>	66/female	Right parietal	Right parietal	Headache, vomiting	MRI	One-stage tumor removal	WHO I meningioma/GBM
2	Ruiz <i>et al.</i> , 2015 <sup>[9]</sup>	86/male	Right frontotemporal	Right frontotemporal	Left hemiparesis	MRI	One-stage tumor removal	WHO I meningioma/GBM
3	Zhang <i>et al.</i> , 2015 <sup>[6]</sup>	39/male	Left lateral ventricle trigone	Left lateral ventricle trigone	Headache, dizziness	MRI	One-stage tumor removal	WHO I meningioma/WHO II astrocytoma
4	Khalatbari <i>et al.</i> , 2010 <sup>[10]</sup>	12/male	Left lateral ventricle trigone	Left lateral ventricle trigone	Headache, seizure, right hemiparesis	MRI	One-stage tumor removal	Meningioma*/WHO III astrocytoma
5	Chen <i>et al.</i> , 2010 <sup>[11]</sup>	63/female	Left frontal	Left frontal	Headache, arm weakness	MRI	One-stage tumor removal	Fibroblastic meningioma/GBM
6	Suzuki <i>et al.</i> , 2010 <sup>[12]</sup>	75/female	Left temporal	Left temporal	Headache	MRI	One-stage tumor removal	Meningothelial meningioma/GBM
7	Mitsos <i>et al.</i> , 2009 <sup>[13]</sup>	73/female	Right sphenoid wing	Right temporal	N/A	MRI	One-stage tumor removal	Fibrillary meningioma/GBM
8	Nestler <i>et al.</i> , 2007 <sup>[14]</sup>	49/male	Left frontal falx	Left frontal	Disorientation, dysphasia	MRI	One-stage tumor removal	Fibrous meningioma/GBM
9	Tugcu <i>et al.</i> , 2006 <sup>[5]</sup>	42/male	Left parietal	Left parietal	Right hemiparesis, disturbed speech	MRI	One-stage removal	Transitional meningioma/GBM
10	Maiuri <i>et al.</i> , 2005 <sup>[15]</sup>	65/male	Falx (anterior third left)	Left frontal	Seizure	CT	One-stage removal	Meningioma*/WHO Grade II astrocytoma
11	Drlicek <i>et al.</i> , 2004 <sup>[16]</sup>	51/male	Left frontal	Left frontal	Headache, facial palsy	MRI	One-stage removal	WHO Grade I meningioma/GBM
12	Goyal <i>et al.</i> , 2003 <sup>[17]</sup>	72/male	Right sphenoid wing	Right temporal	Headache, seizure	MRI	One-stage removal	Fibroblastic meningioma/glioblastoma
13	Prayson <i>et al.</i> , 2002 <sup>[18]</sup>	87/female	Right frontal lobe	Right frontal lobe	Left hemiparesis, urinary incontinence	MRI	One-stage removal	Syncytial meningioma/WHO Grade III astrocytoma
14	Spallone <i>et al.</i> , 1991 <sup>[4]</sup>	48/female	Left cavernous sinus	Left paralateral ventricular	Headache and confusion	CT	Biopsy + radiation, refused surgery	Fibroblastic meningioma/malignant astrocytoma
15	Vaquero <i>et al.</i> , 1990 <sup>[19]</sup>	75/female	Left parietal lobe	Left parietal lobe	Episode of dysphasia and facial dysesthesia	CT	One-stage removal	Psammomatous meningioma/GBM
16	Marra <i>et al.</i> , 1977 <sup>[20]</sup>	63/male	Right parietal lobe	Right parietal lobe	Left-arm paresis, papilledema	Angiography, EEG, and isotope scan	One-stage removal	Meningotheliomatous meningioma/GBM
17	Strong <i>et al.</i> , 1976 <sup>[8]</sup>	56/female	Right frontoparietal parasagittal	Right frontoparietal	Left hemiparesis, headache, gait disturbance	CT	Two-stage removal	Meningioma*/GBM
18		53/male	Left sphenoidal wing	Left temporal lobe	Headache, dysphasia, right hemiparesis	Isotope scan, angiography	One-stage removal	Syncytial meningioma/GBM
19	Present case	61/female	Right frontal lobe	Right frontal lobe	Headache, left hemiparesis	MRI	One-stage removal	Fibrous meningioma/WHO Grade II astrocytoma

\*Subtype not described. GBM – Glioblastoma multiforme; N/A – Information not available, full text is in Polish; MRI – Magnetic resonance imaging; EEG – Electroencephalogram; CT – Computed tomography

Therefore, we are in favor of the hypothesis that the association of collision tumors in reported cases may be a coincidental event.<sup>[5,6,14,27]</sup>

To have an accurate preoperative diagnosis for these tumors is really difficult. The area with hyperintensity T2-weighted images surrounding a meningioma usually



represents peritumoral edema and should be distinguished from low-grade glioma in collision tumors involving meningioma and glioma.

It is important to have an appropriate surgical strategy for these patients. Most authors agree that removal of both tumors in one stage usually yields good results.<sup>[4,28]</sup> Some authors suggest that the removal of meningioma should be done first to avoid postoperative brain swelling after glioma resection.<sup>[4,5]</sup> However, brain swelling after meningioma resection is not uncommon and can worsen the neurological status. Another approach is to remove the symptomatic tumor first.<sup>[2,3]</sup> In our case, we removed both the lesions in one section because both tumors were located in the noneloquent area, and the approach was not difficult.

## Conclusion

The occurrence of collision tumors in patients without a history of radiotherapy or phakomatosis is rare. We report the third case of meningioma and low-grade astrocytoma collision in the frontal lobe. No clear explanation was found, and it is most likely a coincidence. Careful preoperative imaging evaluation is very important in these cases so that we may have a correct diagnosis and surgical strategy. In planning for surgery for collision tumors, one-stage resection is likely the best management.

## Declaration of patient consent

The authors certify that they have obtained all appropriate patient consent forms. In the form the patient(s) has/have given his/her/their consent for his/her/their images and other clinical information to be reported in the journal. The patients understand that their names and initials will not be published and due efforts will be made to conceal their identity, but anonymity cannot be guaranteed.

## Acknowledgement

The authors would like to thank you very much Dr. Albert Tu for his contribution in sharing his comments and English correction for this manuscript.

## Financial support and sponsorship

Nil.

## Conflicts of interest

There are no conflicts of interest.

## References

1. Annegers JF, Schoenberg BS, Okazaki H, Kurland LT. Epidemiologic study of primary intracranial neoplasms. *Arch Neurol* 1981;38:217-9.
2. Davis GA, Fabinyi GC, Kalnins RM, Brazenor GA, Rogers MA. Concurrent adjacent meningioma and astrocytoma: A report of three cases and review of the literature. *Neurosurgery* 1995;36:599-604.
3. Lee EJ, Chang CH, Wang LC, Hung YC, Chen HH. Two primary brain tumors, meningioma and glioblastoma multiforme, in opposite hemispheres of the same patient. *J Clin Neurosci* 2002;9:589-91.
4. Spallone A, Santoro A, Palatinsky E, Giunta F. Intracranial meningiomas associated with glial tumours: A review based on 54 selected literature cases from the literature and 3 additional personal cases. *Acta Neurochir (Wien)* 1991;110:133-9.
5. Tugcu B, Kepoglu U, Gunal M, Gunaldi O, Karakaya B, Demirgil BT, *et al.* Two distinct primary brain tumors, in same region of the same patient: A case report. *J Neurooncol* 2006;79:219-20.
6. Zhang D, Yu J, Guo Y, Zhao S, Shao G, Huang H, *et al.* An intraventricular meningioma and recurrent astrocytoma collision tumor: A case report and literature review. *World J Surg Oncol* 2015;13:37.
7. Zhang Z, Yang Y, Zhang K, Zhuang J, Shao F, Liu H, *et al.* Collision tumor of glioblastoma and meningioma: Case report and literature review. *World Neurosurg* 2018;117:137-41.
8. Strong AJ, Symon L, MacGregor BJ, O'Neill BP. Coincidental meningioma and glioma. Report of two cases. *J Neurosurg* 1976;45:455-8.
9. Ruiz J, Capilla E, Díaz JF, Ruiz JA, Andrade J, Hernández T, *et al.* Secretory meningioma with KLF4 K409Q mutation in collision with glioma. *Clin Neuropathol* 2015;34:322-9.
10. Khalatbari M, Borghei-Razavi H, Shayanfar N, Behzadi AH, Sepehrnia A. Collision tumor of meningioma and malignant astrocytoma. *Pediatr Neurosurg* 2010;46:357-61.
11. Chen G, Gao X, Liao Y, Xu B. A glioblastoma adjacent to a meningioma. *Br J Neurosurg* 2010;24:718-9.
12. Suzuki K, Momota H, Tonooka A, Noguchi H, Yamamoto K, Wanibuchi M, *et al.* Glioblastoma simultaneously present with adjacent meningioma: Case report and review of the literature. *J Neurooncol* 2010;99:147-53.
13. Mitsos AP, Konstantinou EA, Fotis TG, Lafazanos SA, Kontogeorgos G, Georgakoulas NV, *et al.* Sphenoid wing meningioma and glioblastoma multiforme in collision - case report and review of the literature. *Neurol Neurochir Pol* 2009;43:479-83.
14. Nestler U, Schmidinger A, Schulz C, Huegens-Penzel M, Gamerdinger UA, Koehler A, *et al.* Glioblastoma simultaneously present with meningioma – Report of three cases. *Zentralbl Neurochir* 2007;68:145-50.
15. Maiuri F, Cappabianca P, Iaconetta G, Esposito F, Messina A. Simultaneous presentation of meningiomas with other intracranial tumours. *Br J Neurosurg* 2005;19:368-75.
16. Drlicek M, Aichholzer M, Wurm G, Bodenteich A, Fischer J. Collisiontumour composed of glioblastoma and meningioma-a case report. *Pathologe* 2004;25:402-5.
17. Goyal A, Singh AK, Sinha S, Tatke M, Singh D, Gupta V, *et al.* Simultaneous occurrence of meningioma and glioma in brain: Report of two cases. *J Clin Neurosci* 2003;10:252-4.
18. Prayson RA, Chowdhary S, Woodhouse S, Hanson M, Nair S. Collision of a syncytial meningioma and malignant astrocytoma. *Ann Diagn Pathol* 2002;6:44-8.
19. Vaquero J, Coca S, Martínez R, Jiménez C. Convexity meningioma and glioblastoma in collision. *Surg Neurol* 1990;33:139-41.
20. Marra A, Ramponi G, Grimaldi G. Simultaneous occurrence of right supratentorial meningioma and glioblastoma multiforme. Case report. *Acta Neurochir (Wien)* 1977;36:83-91.
21. Black PM, Carroll R, Glowacka D, Riley K, Dashner K. Platelet-derived growth factor expression and stimulation in human meningiomas. *J Neurosurg* 1994;81:388-93.

22. Esiri M. Russell and Rubinstein's pathology of tumors of the nervous system. Sixth edition J Neurol Neurosurg Psychiatry 2000;68:538D.
23. Hermanson M, Funa K, Hartman M, Claesson-Welsh L, Heldin CH, Westermark B, *et al.* Platelet-derived growth factor and its receptors in human glioma tissue: Expression of messenger RNA and protein suggests the presence of autocrine and paracrine loops. Cancer Res 1992;52:3213-9.
24. Maxwell M, Naber SP, Wolfe HJ, Galanopoulos T, Hedley-Whyte ET, Black PM, *et al.* Coexpression of platelet-derived growth factor (PDGF) and PDGF-receptor genes by primary human astrocytomas may contribute to their development and maintenance. J Clin Invest 1990;86:131-40.
25. Lusi EA, Watson MA, Chicoine MR, Lyman M, Roerig P, Reifenberger G, *et al.* Integrative genomic analysis identifies NDRG2 as a candidate tumor suppressor gene frequently inactivated in clinically aggressive meningioma. Cancer Res 2005;65:7121-6.
26. Deng Y, Yao L, Chau L, Ng SS, Peng Y, Liu X, *et al.* N-myc downstream-regulated gene 2 (NDRG2) inhibits glioblastoma cell proliferation. Int J Cancer 2003;106:342-7.
27. Iyer VR, Sanghvi DA, Shenoy A, Goel A. Three distinct co-existent primary brain tumors in a patient. J Cancer Res Ther 2009;5:293-6.
28. Maiuri F, Cappabianca P, Iaconetta G, D'Acunzi G. Meningiomas associated with brain metastases. Zentralbl Neurochir 2002;63:111-5.