

Hydatid Cyst of Dorsal Spine Masquerading as Tubercular Infection: A Case Report and Review of Literature

Abstract

Hydatid cyst disease of the spine is rare, and only a few are reported in the scientific literature. This infection is caused by the larvae of *Echinococcus granulosus cestode*. The presentation is usually late because the patient remains asymptomatic for a longer duration after the infection. The initial form of treatment is always surgical in a symptomatic patient for excision of the diseased tissue. A 35-year-old male presented in the outpatient department with a chief complaint of mid-back pain and intermittent history of fever following his back surgery for 4 years. The patient has taken presumptive treatment for tuberculosis before presenting it to us. Radiological investigations dictate the presence of hydatid cyst in the D4 vertebra. Intact cysts were excised with perioperative albendazole coverage. The patient was mobilized on postoperative day-1 with Taylor's brace, and the brace was continued for 6 weeks. The patient was followed up at regular intervals for 1 year, and no recurrence was found. Hydatid cyst disease in the spine is a rare disease but associated with high morbidity despite significant advances in diagnostic imaging techniques and surgical treatment. For a provisional diagnosis, magnetic resonance imaging is the investigation of choice. Surgical decompression is the main stay of treatment along with antihelminthic therapy. A close follow-up is required after the initial treatment to find the recurrence at the earliest.

Keywords: Decompression, dorsal spine, hydatid cyst

Introduction

Hydatid cyst disease is a parasitic infection caused by the ingestion of larvae of *Echinococcus granulosus cestode*.^[1] The cestode's life cycle involves two hosts—

1. The definitive hosts: Dogs and
2. The intermediate or accidental host: Human beings.

Human beings become infected after the accidental ingestion of eggs of the cestode, which are often found in the dog's fecal matter. The Larvae of the cestodes hatch from the eggs in the human intestine. These larvae then erode the capillaries in the intestine and migrate throughout the human body. The hydatid cysts are most commonly found in the liver (60%–70%), followed by the lungs (10%–15%).^[2,3] Rarely it affects bone in around 0.5%–2% of cases and mainly involves the spine in about 0.5%–1% of cases.^[4] Out of all cases with involvement of the spine, thoracic spine involvement is most common (50%) followed by the lumbar spine (20%), sacral spine (20%), and cervical

spine (10%).^[5,6] It can manifest local bone destruction, collapse, and instability leading to radiculopathy, paraplegia, and quadriplegia.^[7,8] The diagnosis is usually late because of a painless asymptomatic lesion in the initial stage of disease.^[9] Here, we are presenting a case of hydatid cyst in the dorsal spine managed with decompression at a tertiary health care institute.

Case Report

A 35-year-old male presented in the outpatient department (OPD) with a chief complaint of mid-back pain for 4 years and intermittent history of fever. He also complained of intermittent fluid discharge from a scar in the upper back. He had undergone a surgery in his upper back 4 years ago. The details of the previous surgery were not available with the patient. He was on presumptive anti-tubercular treatment therapy for the past 6 months before visiting us, taking into consideration of the endemic region as prescribed by

**Gurudip Das,
Saurav Narayan
Nanda,
Nabin Kumar Sahu,
Doki Sunil Kumar,
Bishnu Prasad
Patro**

*Department of Orthopedics,
All India Institute of Medical
Sciences, Bhubaneswar, Odisha,
India*

Address for correspondence:
Dr. Saurav Narayan Nanda,
Flat No- 602, Type- IV Quarter,
All India Institute of Medical
Sciences, Housing Complex,
Bhubaneswar - 751 019,
Odisha, India.
E-mail: saurav.scb@gmail.com

Access this article online

Website: www.asianjns.org

DOI: 10.4103/ajns.ajns_199_21

Quick Response Code:



This is an open access journal, and articles are distributed under the terms of the Creative Commons Attribution-NonCommercial-ShareAlike 4.0 License, which allows others to remix, tweak, and build upon the work non-commercially, as long as appropriate credit is given and the new creations are licensed under the identical terms.

For reprints contact: WKHLRPMedknow_reprints@wolterskluwer.com

How to cite this article: Das G, Nanda SN, Sahu NK, Kumar DS, Patro BP. Hydatid cyst of dorsal spine masquerading as tubercular infection: A case report and review of literature. Asian J Neurosurg 2021;16:886-9.

Submitted: 11-May-2021

Revised: 12-Jul-2021

Accepted: 13-Jul-2021

Published: 18-Dec-2021

the previous physician. On examination, tenderness was elicited in the upper dorsal vertebra, and kyphotic deformity was found. There was no deficit. X-ray was found to be nearly normal except kyphosis in the region of D2–D6 and partial collapse of D4. On magnetic resonance imaging (MRI), hydatid cyst disease was confirmed to involve the D4 vertebra involving the paravertebral area [Figure 1]. Operative intervention was planned, and surgery was performed through the posterior approach. D4 spinous process and part of lamina were found deficient due to previous surgical intervention. Intact cysts in the paravertebral area were excised [Figure 2]. Intraoperatively, the vertebral column integrity was found to be intact after the total excision of all the cysts and surrounding soft tissues without any loss of stability. The wound was closed in layers after giving thorough wash. The excised hydatid cysts were sent for histopathological examination and that further confirmed the diagnosis [Figure 3]. The patient was subjected to perioperative and postoperative Albendazole treatment for 6 months. He was mobilized postoperative day-1 with Taylor's brace, and the brace was continued up to 6 weeks. He was followed up on an OPD basis at 2 weeks, 6 weeks, 3 months, 6 months, and 1 year. There was no recurrence till his last visit.

Discussion

Patients of spinal hydatidosis usually are asymptomatic and generally present with insidious onset of pain in the affected region. Few become symptomatic either due to cord compression or due to the collapse of the vertebral body, which usually happens after a prolonged infective period, causing a delay in diagnosis. However, half of the patients with spinal hydatid cyst disease may have neurological involvement at the time of presentation.^[10]

Radiological investigations in the form of plain radiographs and computed tomography (CT) scans can delineate bony destruction.^[11,12] MRI, however, is the investigation of choice.^[13,14] MRI provides detailed information on the extent of the lesion and the amount of cord compromise. The cysts are hypointense on T1-weighted images and hyperintense on T2-weighted sequences. The hydatid cyst usually contains a single thin wall, and the cystic fluid has the same intensity as cerebrospinal fluid on MRI images. The cyst walls or content do not show enhancement with gadolinium contrast. Biopsy or aspiration of the cyst has a significant risk of diffusion and precipitating anaphylactic reaction. Hence, these invasive investigations should not be done to establish the diagnosis.^[15]

Surgical resection of the cystic lesions en-bloc remains the treatment of choice. The histopathological examination establishes the diagnosis, as the lesion may mimic various other pathologies. The differential diagnosis can be a solitary bone cyst, aneurysmal bone cyst, arachnoid cyst, giant cell tumor, chondrosarcoma, neurofibromatosis, and tubercular spondylodiscitis. Misdiagnosis based on

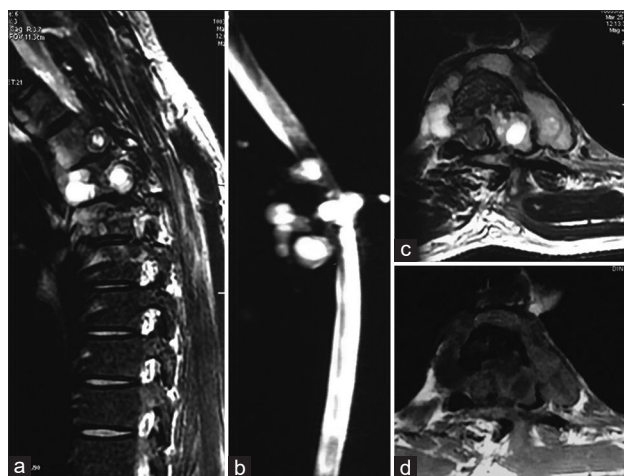


Figure 1: (a) Magnetic resonance imaging of the dorsal vertebra in the sagittal plane, T2 sequence showing hydatid cysts in the D4 region with partial collapse of D4 vertebra. (b) Magnetic resonance imaging of the dorsal vertebra in the sagittal plane, myelo sequence showing hydatid cysts in the D4 region. (c) Magnetic resonance imaging of the dorsal vertebra in an axial plane with T2 sequence showing hydatid cysts in the D4 region. (d) Magnetic resonance imaging of the dorsal vertebra in an axial plane, T1 sequence showing hydatid cysts in the D4 region

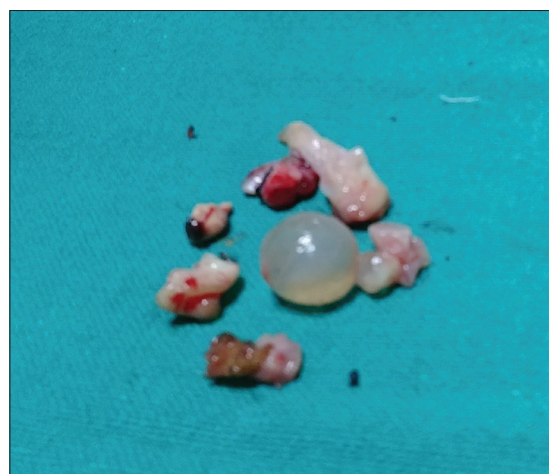

Figure 2: Intraoperative picture showing excised intact hydatid cysts

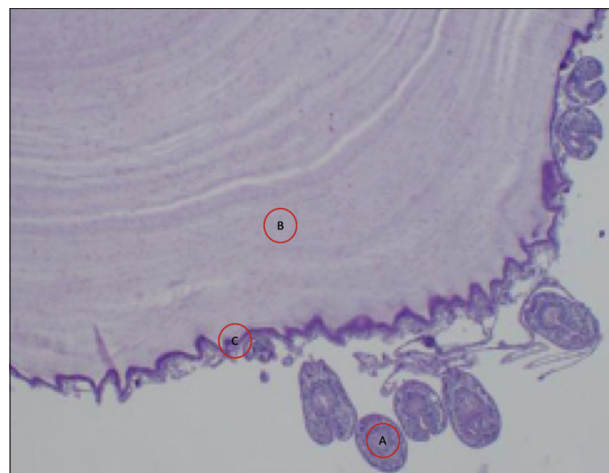


Figure 3: Histopathological examination. A – Scolex of the hydatid cyst. B – Cyst wall of the hydatid cyst. C – Germinative layer of the hydatid cyst

clinoradiological findings is common^[16] and may have disastrous consequences because of intraoperative rupture of the cyst wall. In our case, the patient was suspected of having tubercular spondylodiscitis and had been on anti-tubercular drugs for a prolonged period. Definitive diagnosis was made during surgery when the characteristic grape-like cysts were noted during surgery.

A posterior approach with laminectomy provides access to the intraspinal lesion.^[5] Anterior transthoracic approaches may be required if the cysts are predominantly in the prevertebral or paravertebral location. In our case, laminectomy was done to remove the intraspinal cysts. The paravertebral cysts were removed after costotransversectomy. No instrumentation was done. A review of literature done after surgery, however, revealed that reconstruction with transpedicular screws, metallic cages, or bone graft is usually recommended for maintaining spinal stability.

Dew/Braithwaite and Lees^[4] described a classification of spinal hydatid cystic lesions depending on its location as (1) Primary intramedullary hydatid cyst, (2) Intradural extramedullary hydatid cyst, (3) Extradural intraspinal hydatid cyst, (4) Intraosseous/vertebral hydatid cyst, and (5) Paravertebral hydatid cyst disease. This classification helps in planning the surgical approach for excision of the cysts. It also helps as a prognostic indicator for recurrence after surgery. Turgut *et al.*, in a series of 72 spinal cystic echinococcus lesions, found that intradural lesions had the least recurrence rate (RR) after surgery (0% in their series). They believed that this favorable outcome was because of solitary intradural cysts. Vertebral (RR 32%) and paraspinous (RR 33%) lesions were associated with far higher rates of recurrence than intraspinal extradural (RR 6%) location. The two main factors determining the RRs after surgery are— complete resection and unruptured resection of the daughter cysts. The intraoperative rupture of cyst causes an increase in a relapse rate exceeding 40%.^[17] Hence, spillage of the cyst contents and associated recurrence is often high.

Since the rupture of cysts and spillage of contents are almost inevitable during surgical resection, various scolicalidal agents are routinely used to sterilize the surgical field and prevent contamination. These scolicalidal agents are, however, not active against intact daughter cysts and are only effective against spilled protoscolices from the ruptured cysts. The intact daughter cysts require adjuvant chemotherapy with various benzimidazole derivatives (albendazole or mebendazole). The scolicalidal agents in vogue are— povidone-iodine, hypertonic saline, hydrogen peroxide, formalin, silver nitrate, cetrimide, and ethacridine lactate. Twenty percent hypertonic saline appears to be the most popular and effective agent among these options. The reason behind the popularity of hypertonic saline is its safety profile and easy availability.

Medical management with various benzimidazole derivatives like albendazole has been in vogue based on their efficacy in visceral hydatid lesions. However, their effectiveness in preventing recurrence in osseous lesions is debatable. Recently, few authors have reported satisfactory results with their use in extensive or inoperable hydatid disease. El Mufti *et al.*, in their series of inoperable spinal hydatid disease, reported a cure rate of 53% with albendazole treatment at 2 years follow-up. In the absence of sufficient data regarding the use of albendazole in spinal lesions, most surgeons follow a dosage regimen based on the WHO recommendations for visceral hydatidosis (15 mg/kg/day). Few authors advocate the initiation of albendazole therapy 4 h before surgery to ensure adequate blood levels during the perioperative period. Although there is no evidence-based study on the optimal duration of albendazole therapy, most authors use it for 6 months, with few advocating its use for longer. Indefinite use of these benzimidazoles has also been reported in few cases with extensive or recurrent hydatid lesions.

Treatment in the form of CT-guided Puncture of the cyst, aspiration of the cyst fluid, injection of a scolicalidal agent, and re-aspiration of the cyst content approach^[18] and radiotherapy^[19,20] are also reported in the literature with variable success rate. Despite anthelmintic therapy and aggressive surgical treatment, it has recurrence ranging from 30% to 100%.^[21]

Conclusion

Hydatid cyst disease in the spine is a rare disease but associated with high morbidity despite significant advances in diagnostic imaging techniques and surgical treatment. It should be considered a differential diagnosis in the case of spinal canal compression. For a provisional diagnosis, the MRI is the investigation of choice. Surgical decompression is the main stay of treatment along with antihelminthic therapy. This disease has high RRs, especially in cases with vertebral bone involvement. Hence, a close follow-up is required after initial treatment.

Clinical message

The hydatid cyst disease in the spine is a rare pathology and diagnosis can be challenging. This disease may mimic tuberculosis, which is one of the most typical diseases in the endemic region. Confirmation should be made with MRI in such cases to avoid misdiagnosis.

Financial support and sponsorship

Nil.

Conflicts of interest

There are no conflicts of interest.

References

1. Charles RW, Govender S, Naidoo KS. Echinococcal infection

- of the spine with neural involvement. *Spine (Phila Pa 1976)* 1988;13:47-9.
2. Scarlata F, Giordano S, Saporito L, Marasa L, Li Pani G, Odierna A, *et al.* Cystic hydatidosis: A rare case of spine localization. *Infez Med* 2011;19:39-41.
 3. Schnepfer GD, Johnson WD. Recurrent spinal hydatidosis in North America. Case report and review of the literature. *Neurosurg Focus* 2004;17:E8.
 4. Braithwaite PA, Lees RF. Vertebral hydatid disease: Radiological assessment. *Radiology* 1981;140:763-6.
 5. Islekel S, Zileli M, Ers ahin Y. Intradural spinal hydatid cysts. *Eur Spine J* 1998;7:162-4.
 6. Bhake A, Agrawal A. Hydatid disease of the spine. *J Neurosci Rural Pract* 2010;1:61-2.
 7. Joshi N, Hernandez-Martinez A, Seijas-Vazquez R. Primary sacral hydatid cyst. A case report. *Acta Orthop Belg* 2007;73:674-7.
 8. Somay H, Ayan E, Turk CC, Emon ST, Berkman MZ. Long-term disseminated recurrence in spinal hydatid cyst: A case report. *Turk Neurosurg* 2014;24:78-81.
 9. Papanikolaou A. Osseous hydatid disease. *Trans R Soc Trop Med Hyg* 2008;102:233-8.
 10. Morshed AA. Hydatid disease of the spine. *Neurochirurgia (Stuttg)* 1977;20:211-5.
 11. Hamdan TA, Al-Kaisy MA. Dumbbell hydatid cyst of the spine: Case report and review of the literature. *Spine (Phila Pa 1976)* 2000;25:1296-9.
 12. Kovoov JM, Thomas RD, Chandrashekar HS, Jayakumar PN, Pillai S, Shankar SK. Neurohydatidosis. *Australas Radiol* 2007;51:406-11.
 13. Kalkan E, Cengiz SL, Çiçek O, Erdi F, Baysefer A. Primary spinal intradural extramedullary hydatid cyst in a child. *J Spinal Cord Med* 2007;30:297-300.
 14. Coates R, von Sinner W, Rahm B. MR imaging of an intracerebral hydatid cyst. *AJNR Am J Neuroradiol* 1990;11:1249-50.
 15. Zlitni M, Ezzaouia K, Lebib H, Karray M, Kooli M, Mestiri M. Hydatid cyst of bone: Diagnosis and treatment. *World J Surg* 2001;25:75.
 16. Lotfinia I, Sayyahmelli S, Mahdkhah A, Shoja MM. Intradural extramedullary primary hydatid cyst of the spine: A case report and review of literature. *Eur Spine J* 2013;22 Suppl 3:S329-36.
 17. Arif SH, Zaheer S. Intradural extramedullary primary hydatid cyst of the spine in a child: A very rare presentation. *Eur Spine J* 2009;18 Suppl 2:179-82.
 18. Spektor S, Gomori JM, Beni-Adani L, Constantini S. Spinal echinococcal cyst: Treatment using computerized tomography-guided needle aspiration and hypertonic saline irrigation. Case report. *J Neurosurg* 1997;87:464-7.
 19. Go kalp HZ, Dinc er C, S ekerci Z, Birler K. Kranial Kist Hidatikler. *Tu rk No ro şiru ği Derg* 1989;1:65-71.
 20. Bao YX, Mao R, Xie ZR, Wen H. One case of radiotherapy on osteo- hydatidosis. *Chin J Parasitol Parasiten Dis (Chin)* 2010;28:320.
 21. Fiori R, Coco I, Nezzo M, Kabunda G, Umana GE, Fraioli MF, *et al.* Spinal Hydatidosis Relapse: A Case Report. *Case Reports in Orthopedics* 2014;2014:6. Article ID 207643. <https://doi.org/10.1155/2014/207643>.