

The Visual Perception and Attractiveness of Maxillary Central Incisor Abrasion as Evaluated via Eye-Tracking

Cássio Trevisan¹, Matheus Melo Pithon², Thiago Martins Meira^{1,3}, Caio Seiti Miyoshi¹, Armando Yukio Saga¹, Orlando Motohiro Tanaka¹

¹Orthodontics, School of Life Sciences, Pontifícia Universidade Católica do Paraná, Curitiba, Paraná, ²Orthodontics, Southwest Bahia State University (UESB), Jequié, ³Bahia State University (UNEB), Guanambi, Bahia, Brazil

Abstract

Aims: The aim of this study was to evaluate the visual esthetic perceptions of dentistry students and laypeople with regard to abrasions of the maxillary incisor edges in a frontal smile analysis. **Materials and Methods:** Abrasions were analyzed through a series of edited frontal photographs, at increments of 0.25, 0.5, 0.75, 1.0, and 1.5 mm, in two subjects (one male and one female, respectively). Raters were dentistry students and laypeople. To obtain ocular tracing data, two software programs Ogama and The Eye Tribe Tracker[®] were used together, which allowed us to visualize ocular movement in certain areas of interest. Specifically, the images were visualized by 30 dentistry students and 30 laypeople. Heat maps and scan paths were generated by the software programs to assess the main regions of ocular fixation. **Results:** According to the analyzed images, the larger the area of abrasion, the greater the visualization at that point. Small differences were observed in both groups; however, the students showed a higher concentration of attention in the region of abrasions as compared with the laypeople. **Conclusions:** There were differences between the groups. Dentistry students maintained their focus for most of the time in the region or near the region of abrasions, while laypeople largely diverged their gaze to other areas and allocated significant visual attention when they observed larger abrasions.

Keywords: Eye tracking, heat maps, incisor abrasion, perception, scan path

INTRODUCTION

For a long time, orthodontic treatment was performed mainly based on occlusal results. The need for treatment in patients with malocclusions and the outcomes of orthodontic treatment are typically assessed by orthodontists or the patients themselves.^[1]

Orthodontists generally employ cephalometry, model analysis, and the index of orthodontic treatment need in their assessments. Conversely, the patient self-evaluation methods include the psychosocial impact questionnaire on dental esthetics and the esthetic component of the index of orthodontic treatment need.^[2]

Dental wear can be described as the loss of hard dental tissue resulting from a physical or chemical cause; it is a broad term used to describe the combined processes of abrasion, erosion, and attrition.^[3]

In recent years, facial esthetics has become a main focus. For this reason, orthodontists around the world are working to

incorporate various tools designed to be used in improving the esthetics of the smile into their clinical routines.^[4] Dental and gingival asymmetries in maxillary incisors are common problems in adult patients and are primarily caused by natural wear, fractures, or onychophagy,^[5] with unequal crown heights being the resulting consequence.

In such a case, often, the patient has a maxillary central or lateral incisor that is shorter or narrower than the contralateral tooth. These asymmetric changes in tooth shape and alignment affect the perception of anterior tooth attractiveness as opposed to symmetric changes.

Address for correspondence: Prof. Orlando Motohiro Tanaka, School of Life Sciences, Pontifícia Universidade Católica do Paraná, Curitiba, Brazil. R. Imaculada Conceição 1155, Curitiba, PR, Brazil. E-mail: tanakaom@gmail.com

This is an open access journal, and articles are distributed under the terms of the Creative Commons Attribution-NonCommercial-ShareAlike 4.0 License, which allows others to remix, tweak, and build upon the work non-commercially, as long as appropriate credit is given and the new creations are licensed under the identical terms.

For reprints contact: reprints@medknow.com

How to cite this article: Trevisan C, Pithon MM, Meira TM, Miyoshi CS, Saga AY, Tanaka OM. The visual perception and attractiveness of maxillary central incisor abrasion as evaluated via eye-tracking. *Eur J Gen Dent* 2019;8:7-12.

Access this article online

Quick Response Code:



Website:
www.ejgd.org

DOI:
10.4103/ejgd.ejgd_141_18

For more objective orientations pertaining to the perception of smile esthetics, several studies were carried out involving the manipulation of digital images^[6,7] and recent investigations, such as those employing eye tracking, have explored the need for orthodontic treatment and treatment outcomes from the viewpoint of laypersons. Importantly, these efforts present a new option for evaluation as compared with traditional assessments based on photographs and the use of the visual analog scale.^[8]

The eye-tracking technique has been widely used in studies of esthetic perception, taking into account facial expression, gender, and ethnic judgment. The major advantage of it is that, with its use, there exists the possibility of recording the movements of the eyeballs while several stimuli compete for attention. Evaluating changes in attention hierarchy is considered to represent a strategy for extracting facial and cognitive information.^[9] Eye tracking also provides an objective method for assessing what people see, and data can establish a visual attention hierarchy^[10] such that the use of this technology may complement the understanding of the analysis that involves the psychosocial aspect of the esthetic sense in symmetrical and asymmetric cases as well as in instances of facial and dental malocclusion.

As dental asymmetry in the esthetic zone is a common problem, mainly caused by tooth wear or abrasions of the incisors and leading to unequal crown lengths, the objective of the present study was to evaluate the visual esthetic perception of the magnitude of abrasions in the maxillary central incisors from different categories of observers through employing the eye-tracking technique.

MATERIALS AND METHODS

The present study was analyzed and approved by the Ethics Committee of the university (name was omitted). The study included 30 dentistry students (15 men and 15 women) and 30 laypeople (15 men and 15 women) who did not receive prior notice of the purpose of the study. The selected images were digitally altered using Photoshop® (Adobe Systems Inc., San Jose, CA, USA) and included only extraoral smiling images. In addition, Photoshop® was also used to remove imperfections (e.g., scars, props, and spots on the skin) from the face that could draw the observer's attention away from the primary focus. Abrasions simulating tooth wear were edited by increasing them progressively in increments of 0.25, 0.5, 0.75, 1.0, and 1.5 mm. In all images, the gingival margins, papillae, and contralateral side along with the mandibular arch were kept aligned and level.

To obtain the ocular tracing, The Eye Tribe Tracker® software (The Eye Tribe Aps, Copenhagen, Denmark) was used in conjunction with the Ogama software (Freie Universität, Berlin, Germany) to observe and record the ocular movement of each evaluator in a given interest area. During the evaluation, 14 interest areas were mapped in the images: Specifically, the right eye (target 1), left eye (target 2), right eyebrow (target 3), left eyebrow (target 4), nose (target 5), right side of the

mouth (target 6), left side of the mouth (target 7), forehead (target 8), hair (target 9), right cheek (target 10), left cheek (target 11), chin (target 12), right ear (target 13), and the left ear (target 14), respectively [Figure 1]. Before participating in the project, raters signed an informed consent form, in which they affirmed they had good vision and were not taking any medicines that might interfere with their cognitive or motor skills.

Raters were informed that they could freely observe the images and were instructed to sit in a chair so that they felt comfortable at a distance of 60 cm–90 cm from a 17-inch (Dell P2317H; Dell Inc., Round Rock, TX, USA) monitor, upon which the images at a true size were projected vertically. The Eye Tribe Tracker® was positioned just below the monitor as recommended by the manufacturer. In the experiment itself, 12 images were projected (six images simulating central incisor abrasions that were projected for 3 s and six transition slides that were projected for 1 s, respectively). Between the displaying of each image, a green transition slide was included to prevent eye fatigue and to prevent the last fixation point of the previous image from interfering with the first fixation point of the next image – in other words, to have a “zero” regarding the focus of the observer's gaze. The software was calibrated to obtain more reliable data and, as a requirement, only the “perfect” calibration was considered.

The tracing of the generated data was done on a heat map and a scanpath. The heat map supplied information such as which areas were those most observed by the raters in a certain interest area as selected according to a color scale ranging from cold colors to warm colors (i.e., green to red). The report of hotter colors meant that more fixations had occurred at that point. This was in addition to information from the other areas that were considered to fall into the “other” category. Furthermore, scanpaths provided tracking order information by rater category.

RESULTS

The results indicated that, the higher the abrasion in the maxillary central incisor was, then the greater the focus of the

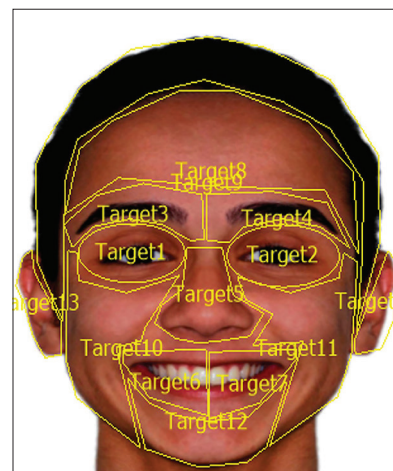


Figure 1: Interest area targets mapped in the face

ratars' eyes for this region was especially for dentistry students. In comparison, laypeople tended to diverge their gaze to other regions such as the eyes and upper lip; however, they also observed abrasions to a greater degree [Figures 2-4].

By evaluating the scanpaths of the images without abrasions, students directed their greatest amount of focus to the anterior region of the smile, diverging slightly to the right eye. In the 0.25mm abrasion images, students placed the greatest focus again on the anterior region, where the abrasions were present [Figure 5]. As a contrast, the laypeople involved in the present study concentrated on the area of wear but often diverged their gaze to the left ear and eyes. For images containing a 1.5mm abrasion, students had the greatest focus on the region of abrasion, diverging slightly to the eyes [Figure 4]. They also fixated predominantly on the affected region, changing their focus slightly at times to the eyes [Figure 5].

DISCUSSION

At present, esthetic dental concerns are on the rise, with many patients seeking out professionals to improve their smile and, consequently, their self-esteem. Eye-tracking technology has been used previously to objectively evaluate attention paid to the mouth, and tracking eye movements can offer insights into dentitions, faces, and smiles, along with a few details regarding laypeople's and dentists' tendencies.

As dental asymmetries in the esthetic zone are common problems, mainly caused by tooth wear or abrasions of the incisors, leading to unequal crown lengths, the objective of the current study was to evaluate the esthetic perceptions of two different groups (laypeople and dentistry students). Through eye tracking, the results were obtained with heat maps and scanpaths of the images, in which there was a range of tooth presentations from a central incisor without abrasions to a central incisor with 1.5-mm abrasions through gradual increases (i.e., 0.25, 0.5, 0.75, 1.0, and 1.5 mm).

When evaluating the images as a whole, a discrepancy of perception can be observed between the two groups of evaluators. Students viewing the nonabrasion images had a greater focus on the region of the abrasion, with little divergence to examining other areas, while conversely, the laypeople looked at several areas, placing their greatest focus on the region worn out in the final images in which the degrees of abrasion were higher [Figure 5].

Tooth wear can be described as the loss of hard dental tissue resulting from a physical or chemical attack; it is an all-embracing term to describe the combined processes of abrasion, erosion, and attrition.^[3]

Teeth worn by abrasions or any other reason usually have a favorable prognosis. The dentist, upon encountering a case of abrasion, tends, from an esthetic perspective, to elaborate on planning and resolution of the case. Among treatment

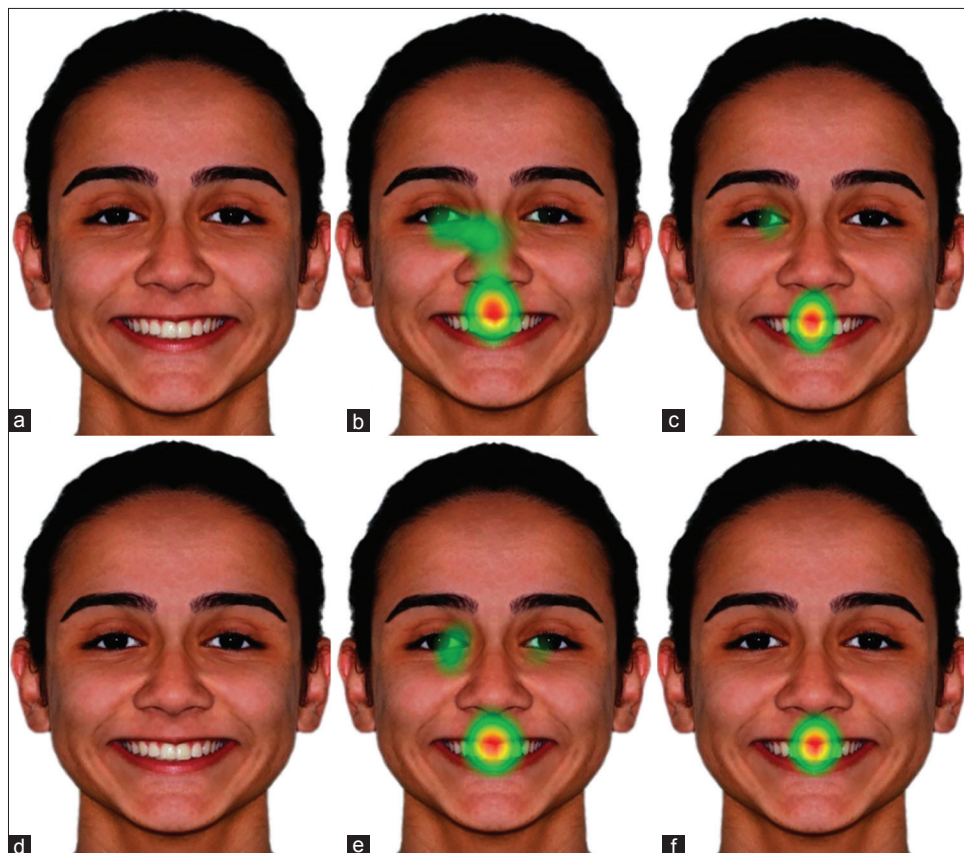


Figure 2: Heat maps. (a) No abrasion; (b) Laypeople; (d) Abrasion of 0.25 mm; (e) Laypeople; (c and f) Students

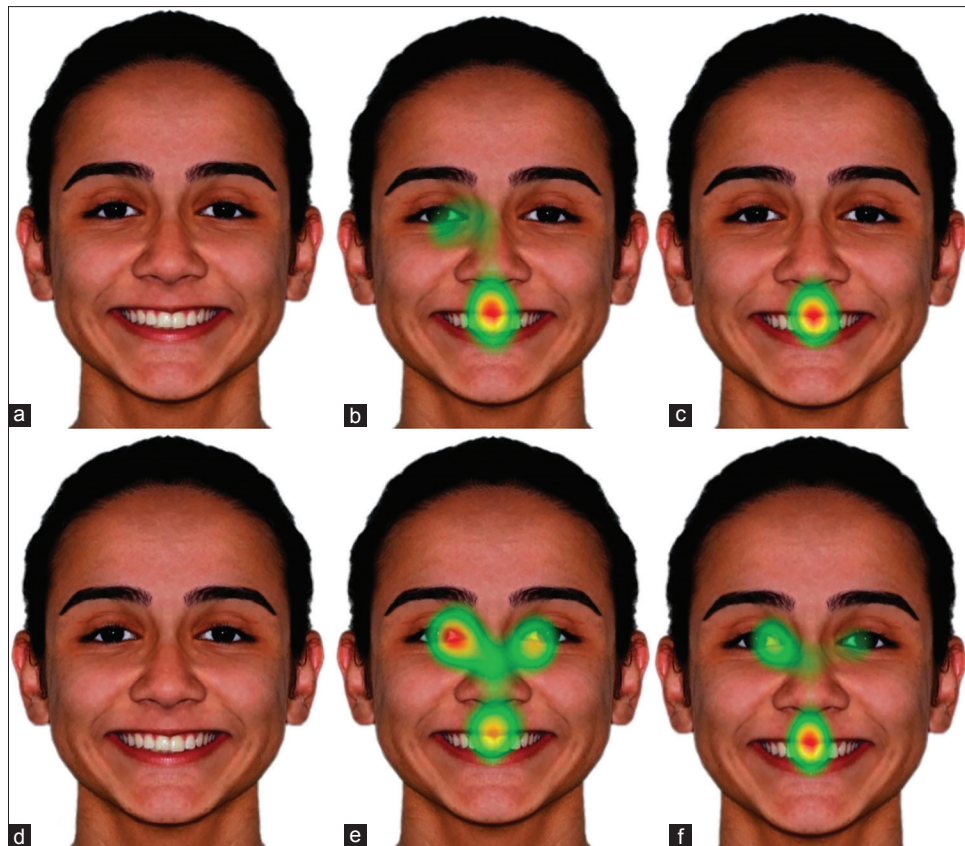


Figure 3: Heat maps. (a) Abrasion of 0.5 mm; (b) Laypeople; (d) Abrasion of 0.75 mm; (e) Laypeople; (c and f) Students

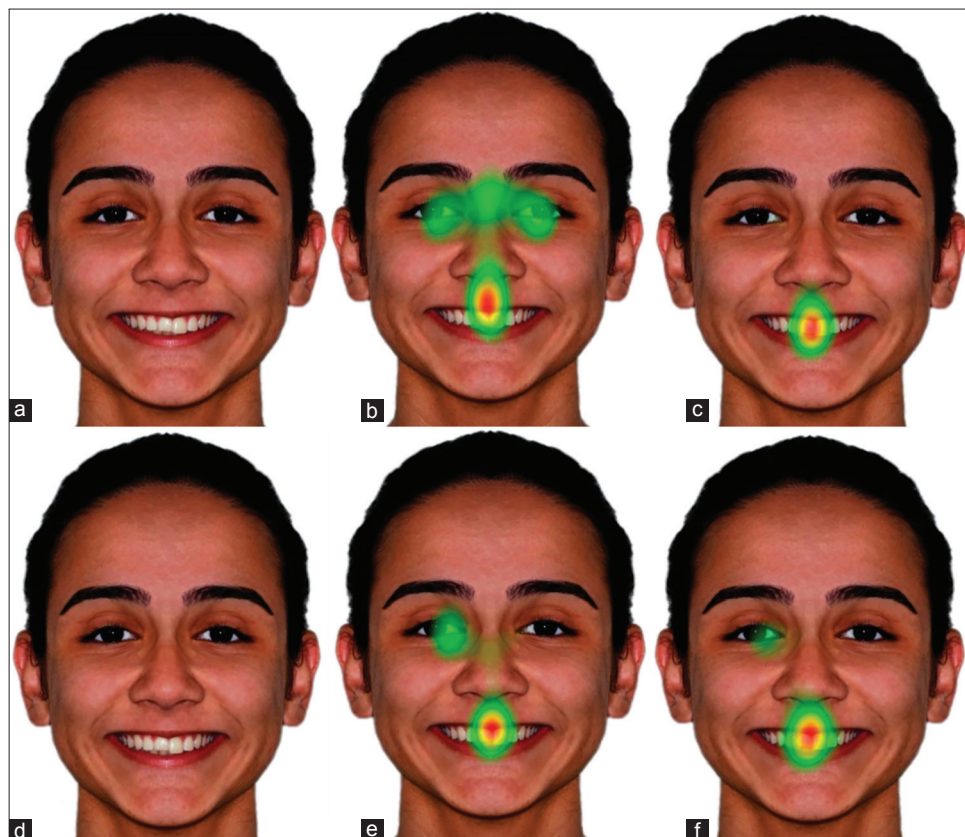


Figure 4: Heat maps. (a) Abrasion of 1.0 mm; (b) Laypeople; (d) Abrasion of 1.25 mm; (e) Laypeople; (c and f) Students

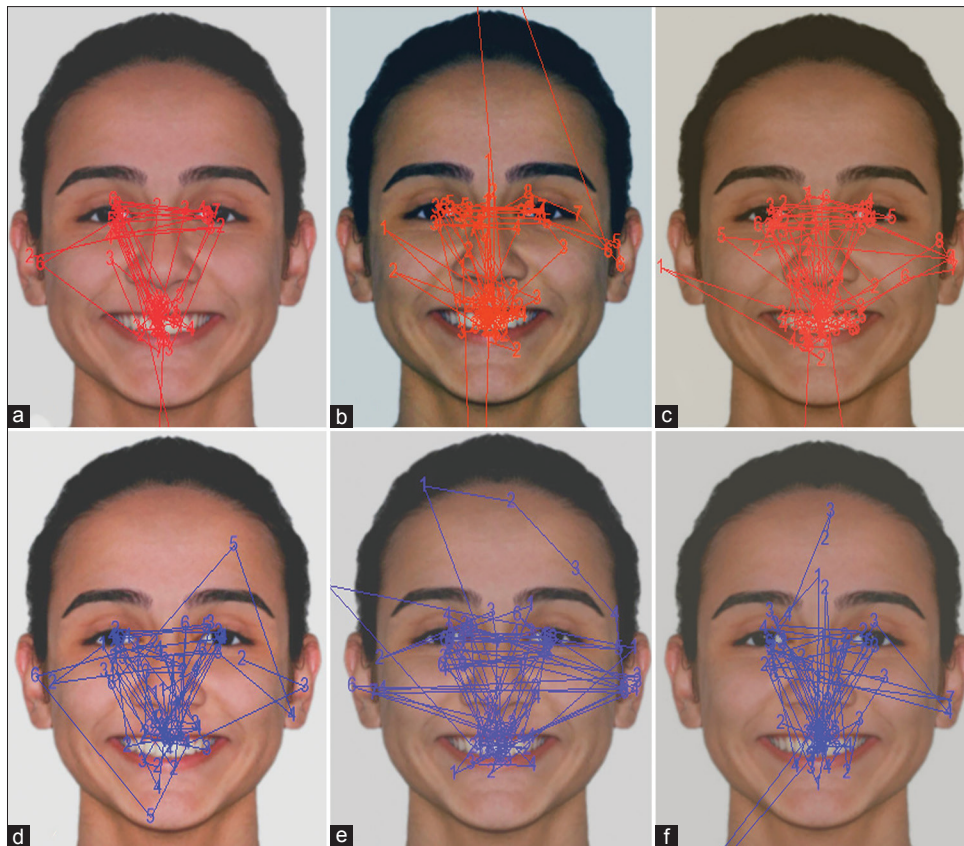


Figure 5: Scanpaths. Students (a) No abrasion; (b) Abrasion of 0.25 mm; (c) Abrasion of 1.5 mm; (d). Laypeople; (e) No abrasion, 0.25 mm; (f) Abrasion of 1.5 mm

alternatives, direct and indirect restorations are mentioned; however, before the conclusion of the case, one must also analyze what the cause of the problem was to potentially prevent a recurrence by mitigating causative factors.

When faced with a case, the dentist should first locate and measure the amount of tooth wear and then subsequently decide whether restoration is necessary, as highlighted by Machado *et al.*^[11] and Kokich *et al.*^[7] Specifically, they suggested that, in certain situations, if slight deviations are not recognized as unattractive, then the patient should perhaps not be referred for cosmetic restorations that would eventually need to be replaced or touched up.

In the current study, the evaluators, both laypeople and students, perceived dental disharmony in the presented images. The students tended to focus more precisely on the teeth because such is their area of practice; however, as everyone was unaware of the project's intent, one can observe in the results that areas observed outside the points of interest of the work exist. Laypeople looked more closely at the whole face, focusing on nearby points, and others far from the area of abrasion. The image with 0.75 mm of abrasion evaluated by laypeople was the only one that had the greatest distance focus, which was the right eye. The rest of the images had the majority of focus of the laypeople present on the upper lip region, which is close to the point of interest.

Clinical situations of abrasion can be observed in individuals with the habit of onychophagia, in which a series of rapid spasmodic bites, with the nails pressed firmly against the cutting edge of the teeth,^[5] cause (or not) some degree of dental wear.

It is important to note that the Ogama software has a capture capacity of approximately 85%. With this, the software may not have been totally faithful to the evaluator's analysis; however, the scanpaths demonstrate that the tracked eye movements were toward the abrasion, demonstrating the effectiveness of this study.

As the results and conclusions of the present study are based on averages, it is difficult to customize this information to a patient because of the subjectivity of evaluations of smile esthetics.^[7] Seeing as we used computer-manipulated patient images and the opinions of specific types of raters, the results should be cautiously interpreted. Therefore, we suggest that clinicians discuss the results of this study with their patients who have a dental abrasion and then request they decide what to do on their own based on the provided information.

CONCLUSIONS

In this study, evaluating raters' observations of different degrees of dental abrasion, there were differences between the

two groups of raters. Dental students primarily focused on the teeth in all images presented, with only slight differences in other areas, while laypeople diverged further into other interest areas with higher degrees of abrasion.

Declaration of patient consent

The authors certify that they have obtained all appropriate patient consent forms. In the form, the patients have given their consent for their images and other clinical information to be reported in the journal. The patients understand that their names and initials will not be published and due efforts will be made to conceal their identity, but anonymity cannot be guaranteed.

Acknowledgments

We thank all participants in this study, Grant from PIBIC-PUCPR - Fundação Araucária research council, and Daniel Daniel Damin da Silva for his help with the technical aspects of figures.

Financial support and sponsorship

Nil.

Conflicts of interest

There are no conflicts of interest.

REFERENCES

- Işiksal E, Hazar S, Akyalçın S. Smile esthetics: Perception and comparison of treated and untreated smiles. *Am J Orthod Dentofacial Orthop* 2006;129:8-16.
- Savastano NJ Jr., Firestone AR, Beck FM, Vig KW. Validation of the complexity and treatment outcome components of the index of complexity, outcome, and need (ICON). *Am J Orthod Dentofacial Orthop* 2003;124:244-8.
- Bernhardt O, Gesch D, Splieth C, Schwahn C, Mack F, Kocher T, *et al.* Risk factors for high occlusal wear scores in a population-based sample: Results of the study of health in pomerania (SHIP). *Int J Prosthodont* 2004;17:333-9.
- Khan M, Fida M. Assessment of psychosocial impact of dental aesthetics. *J Coll Physicians Surg Pak* 2008;18:559-64.
- Viazis AD, DeLong R, Bevis RR, Douglas WH, Speidel TM. Enamel surface abrasion from ceramic orthodontic brackets: A special case report. *Am J Orthod Dentofacial Orthop* 1989;96:514-8.
- Pithon MM, Santos AM, Couto FS, de Freitas LM, Coqueiro Rda S. Comparative evaluation of esthetic perception of black spaces in patients with mandibular incisor extraction. *Angle Orthod* 2012;82:806-11.
- Kokich VO, Kokich VG, Kiyak HA. Perceptions of dental professionals and laypersons to altered dental esthetics: Asymmetric and symmetric situations. *Am J Orthod Dentofacial Orthop* 2006;130:141-51.
- Wang X, Cai B, Cao Y, Zhou C, Yang L, Liu R, *et al.* Objective method for evaluating orthodontic treatment from the lay perspective: An eye-tracking study. *Am J Orthod Dentofacial Orthop* 2016;150:601-10.
- Manor BR, Gordon E. Defining the temporal threshold for ocular fixation in free-viewing visuocognitive tasks. *J Neurosci Methods* 2003;128:85-93.
- Richards MR, Fields HW Jr., Beck FM, Firestone AR, Walther DB, Rosenstiel S, *et al.* Contribution of malocclusion and female facial attractiveness to smile esthetics evaluated by eye tracking. *Am J Orthod Dentofacial Orthop* 2015;147:472-82.
- Machado RM, Assad Duarte ME, Jardim da Motta AF, Mucha JN, Motta AT. Variations between maxillary central and lateral incisal edges and smile attractiveness. *Am J Orthod Dentofacial Orthop* 2016;150:425-35.

Author Help: Online submission of the manuscripts

Articles can be submitted online from <http://www.journalonweb.com>. For online submission, the articles should be prepared in two files (first page file and article file). Images should be submitted separately.

1) First Page File:

Prepare the title page, covering letter, acknowledgement etc. using a word processor program. All information related to your identity should be included here. Use text/rtf/doc/pdf files. Do not zip the files.

2) Article File:

The main text of the article, beginning with the Abstract to References (including tables) should be in this file. Do not include any information (such as acknowledgement, your names in page headers etc.) in this file. Use text/rtf/doc/pdf files. Do not zip the files. Limit the file size to 1 MB. Do not incorporate images in the file. If file size is large, graphs can be submitted separately as images, without their being incorporated in the article file. This will reduce the size of the file.

3) Images:

Submit good quality color images. Each image should be less than 4096 kb (4 MB) in size. The size of the image can be reduced by decreasing the actual height and width of the images (keep up to about 6 inches and up to about 1800 x 1200 pixels). JPEG is the most suitable file format. The image quality should be good enough to judge the scientific value of the image. For the purpose of printing, always retain a good quality, high resolution image. This high resolution image should be sent to the editorial office at the time of sending a revised article.

4) Legends:

Legends for the figures/images should be included at the end of the article file.