

# The Art of Minimal Tooth Reduction for Veneer Restorations

Carlos Alberto Jurado, Jose Villalobos-Tinoco<sup>1</sup>, Akimasa Tsujimoto<sup>2</sup>, Pedro Castro<sup>3</sup>, Ysidora Torrealba<sup>4</sup>

Division of Digital Dentistry, A.T. Still University Arizona School of Dentistry and Oral Health, Mesa, Arizona, USA, <sup>1</sup>Department of Oral Rehabilitation, Autonomous University of Queretaro, Queretaro, Mexico, <sup>2</sup>Department of Operative Dentistry, Nihon University School of Dentistry, Tokyo, Japan, <sup>3</sup>Private Practice, Salvador, Brazil, <sup>4</sup>Department of Restorative Dentistry, University of Alberta Faculty of Medicine and Dentistry, Edmonton, Alberta, Canada

## Abstract

Minimal tooth reduction is crucial for the long-term success of adhesive restorations. It has been proven that bonding to enamel is more predictable in obtaining better long-term success than dentin due to its higher percentage of mineral content. The diagnostic wax-up and subsequent mock-up are the first diagnostic tools available to evaluate discrepancies between current and ideal tooth proportions. The intraoral mock-up provides the patient a tactile and visual evaluation of the size, shape, and shade of the proposed final restorations, and at the same time, the clinician can evaluate the smile line, lip support, phonetics, and occlusion. During the tooth preparation, the mock-up provides a reduction guide to the clinician to achieve the minimal required reduction for the final restoration avoiding the over-reduction and dentin exposure. This clinical report shows feldspathic veneer restorations provided with conservative tooth preparation. The long-term success of the restoration requires following well-defined protocols for restorative material selection, conservative tooth preparation, total isolation with rubber dam, and bonding ceramic protocols.

**Keywords:** Esthetic dentistry, isolation, prosthodontics, rubber dam, veneers

## INTRODUCTION

It has been demonstrated that conservative dentistry techniques rely on bonding and adhesive luting.<sup>[1-3]</sup> Bonding to enamel has been shown to be more durable than dentin due to intact enamel provides the most reliable substrate for etched porcelain laminate veneers.<sup>[4,5]</sup> An adequate tooth preparation must provide uniform reduction and sufficient clearance to allow the ideal thickness of the final restoration without causing any disturbance of the periodontal tissue, esthetics, and structural durability.<sup>[6]</sup> The clinician should follow a conservative way when restoring teeth that have been previously restored, especially for young adult patients.<sup>[7,8]</sup> Ceramic veneers have shown to be a long-lasting treatment when compared to composite veneers and provide higher long-term esthetics.<sup>[9,10]</sup> Veneers have become the most common conservative fixed restoration because they require only 25% of the amount of tooth reduction when compared to complete coverage crown restorations.<sup>[11]</sup> The excessive buccal reduction can lead to compromised bond strength due to exposure of the dentin.<sup>[12]</sup>

Clinical challenges associated with porcelain veneers include its fracture or chipping and luting composite resin shrinkage.<sup>[13-15]</sup> The success of ceramic veneer restorations depends on many

factors such as proper diagnosis, preparation design,<sup>[16]</sup> adhesive bonding techniques,<sup>[17,18]</sup> and patient home care with excellent oral hygiene.<sup>[19]</sup> Using new laboratory techniques and optimal dental materials, it is possible to produce ultrathin ceramic veneers with a thickness of 0.1–0.5 mm, which can be bonded to tooth surface with minimal or no tooth preparation in order to modify the position, color, and shape of the teeth.<sup>[20,21]</sup> Currently, there are several ceramic materials available in the market, such as lithium disilicate, feldspathic porcelain, feldspathic porcelain reinforced with leucite, and lithium disilicate reinforced with zirconia.<sup>[22-25]</sup> High survival rates with low failure numbers have been found for ceramic veneers bonded to enamel.<sup>[26,27]</sup>

During the diagnosis steps, it is essential the fabrication of an adequate diagnostic wax-up to evaluate the discrepancies

**Address for correspondence:** Dr. Carlos Alberto Jurado, Division of Digital Dentistry, A.T. Still University Arizona School of Dentistry and Oral Health, Mesa, Arizona, USA.  
E-mail: carlosjurado@atsu.edu

This is an open access journal, and articles are distributed under the terms of the Creative Commons Attribution-NonCommercial-ShareAlike 4.0 License, which allows others to remix, tweak, and build upon the work non-commercially, as long as appropriate credit is given and the new creations are licensed under the identical terms.

**For reprints contact:** reprints@medknow.com

**How to cite this article:** Jurado CA, Villalobos-Tinoco J, Tsujimoto A, Castro P, Torrealba Y. The art of minimal tooth reduction for veneer restorations. *Eur J Gen Dent* 2020;9:45-52.

**Received:** 26<sup>th</sup> September, 2019 **Accepted:** 17<sup>th</sup> November, 2019

**Publication:** 02<sup>nd</sup> January, 2020

### Access this article online

#### Quick Response Code:



**Website:**  
www.ejgd.org

**DOI:**  
10.4103/ejgd.ejgd\_173\_19

between current and ideal tooth measurements, restorative space available, occlusal scheme, and any treatment needed in the opposing arch.<sup>[28-31]</sup> This information can be transferred to the patient mouth as a diagnostic mock-up using bis-acryl material. During this step, the patient can physically evaluate the desired outcome and the clinician can modify specific areas as needed. The final result of the mock-up can be used as a reference for the fabrication of the final ceramic restorations.

Another advantage of the mock-up technique is its use as a reduction guide for the clinician during the teeth preparation. The use of a rubber dam before bonding the final ceramic restorations aims to prevent any contamination and maximize the bonding properties between the ceramic and the tooth surface.<sup>[32,33]</sup> This clinical report describes a conservative approach involving patient evaluation with a diagnostic mock-up, followed by conservative tooth preparations on the diagnostic mock-up, and complete isolation with rubber dam for the bonding procedure of feldspathic veneers.

### CASE REPORT

A 35-year-old female patient presented to the clinic with the chief goal of improving her smile [Figure 1]. During the clinical examination, it was noticed that central and lateral incisors (#7, 8, 9, and 10) were previously restored with direct composite veneers, and both upper canines (#6

and #11) had uneven incisal reduction [Figures 2-4]. The patient has been with these restorations for 5 years, and the composite veneers present yellow staining on all the buccal surfaces and around the margins. An adequate diagnostic wax-up (GEO Classic, Renfert, Hilzingen, Germany) was needed to evaluate the discrepancies between current and ideal tooth dimensions, restorative space available, and occlusion [Figure 5]. After the wax-up was approved by the patient, a diagnostic mock-up with a self-cured temporary composite material – bis-acryl (Structure Premium, VOCO GmbH, Cuxhaven) – was made in order to evaluate in placed the future dimensions of the proposed ceramic restorations [Figures 6 and 7]. The patient was pleased with the results of the diagnostic mock-up and requested to move forward in the treatment. The final treatment plan included porcelain ceramic veneers on teeth #6, 7, 8, 9, 10, 11, and 12.

At the following clinical appointment, the same previously approved mock-up with a self-cured material was created and placed intraorally. Horizontal and incisal vertical depth grooves were cut into the teeth with a round diamond bur (801 Spherical, JOTA AG, Rüthi, Switzerland) and marked with a red pencil (Colored Pencils, Prismacolor Verithin, Oak Brook, IL, USA) in order to have a controlled tooth reduction [Figures 8-10]. Conservative tooth reduction was performed on the diagnostic mock-up and with the aid of a reduction guide using the fine diamond bur with the conical end (850, JOTA AG) in high speed.

A putty reduction guide matrix (Hydrorise Putty, Zhermack SpA, Badia Polesine, Italy) was previously fabricated in order



Figure 1: Initial face smile

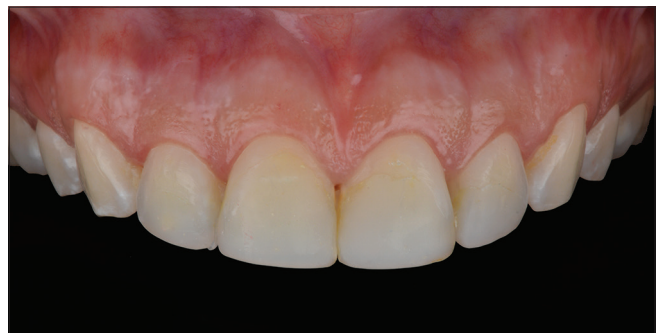

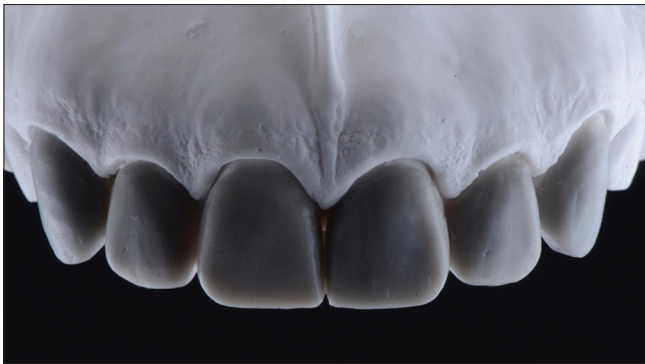
Figure 2: Initial intraoral frontal view

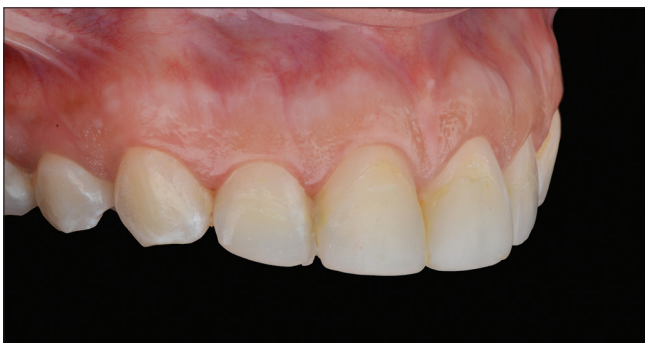

Figure 3: Initial intraoral right-side view

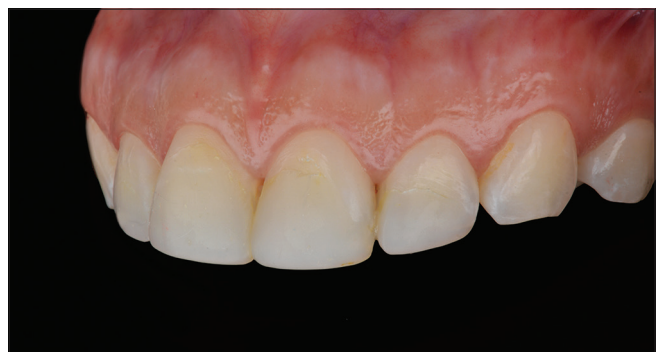

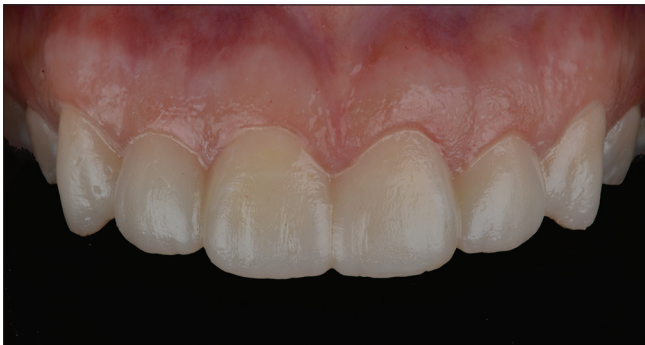Figure 4: Initial intraoral left-side view



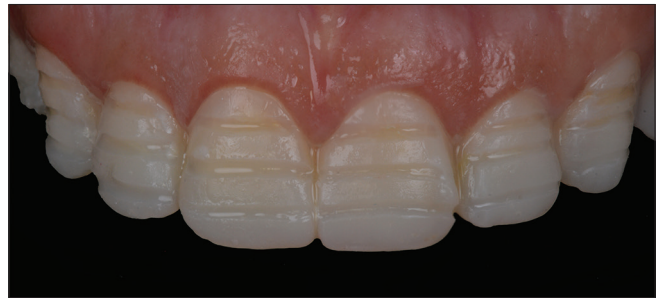**Figure 5:** Diagnostic wax-up



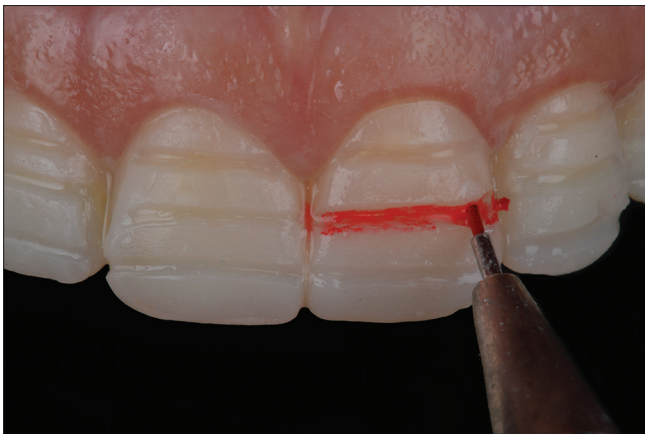**Figure 6:** Diagnostic mock-up smile



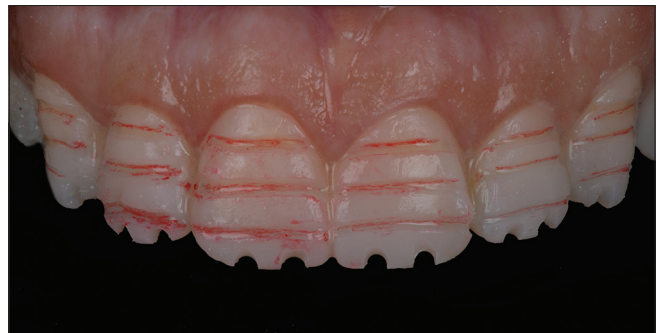**Figure 7:** Diagnostic mock-up intraoral



**Figure 8:** Reduction grooves on diagnostic mock-up



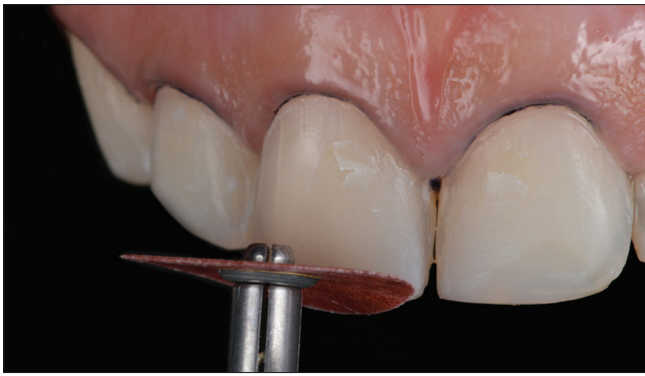**Figure 9:** Marking reduction grooves



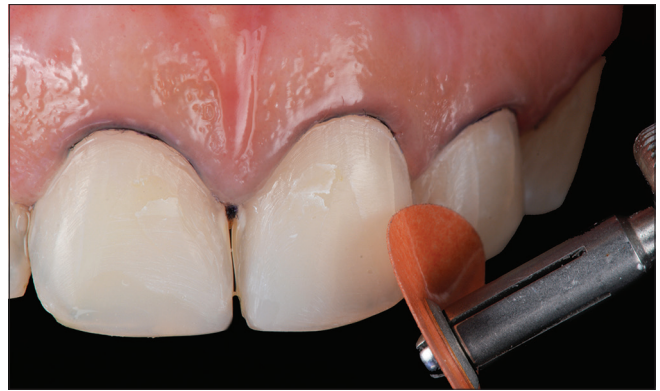**Figure 10:** Reduction grooves

to evaluate incisal and facial reduction, and a periodontal probe was used to measure the amount of tooth reduction. After conservative tooth preparations were completed, the teeth were polished and smoothed, and corners were rounded using coarse, medium, and fine discs (Sof-Lex discs, 3M Oral Care, St. Paul, MN, USA) [Figures 11-13]. After final tooth preparations were refined and polished [Figures 14-16], a double cord impression technique was used, first packing cord #00 and then #0 (Ultrapak, Ultradent Products Inc., South Jordan, UT, USA) [Figures 17 and 18], and the final impression was made using light body and heavy body consistency polyvinylsiloxane (Virtual 380, Ivoclar Vivadent, Amherst, NY, USA) [Figures 19 and 20].

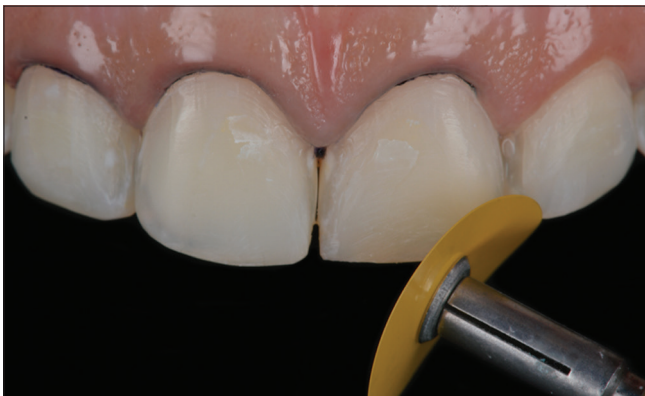Final impressions were poured out with type IV stone to obtain the master casts and individual alveolar dies (Fujirock, GC America Inc., Alsip, IL, USA) [Figure 21]. Feldspathic porcelain material was used to fabricate the veneers in order to fulfill the patient's high esthetic demands (Noritake Super Porcelain EX-3, Kuraray Noritake Dental Inc., New York, NY, USA) [Figures 22-27]. At the final cementation appointment, isolation was provided with rubber dam from #4 to #13, placing holder clamps on #4 and #13 (Rubber Dam Clamps #2, Hu-Friedy, Chicago, IL, USA). Moreover, clamps (Hygenic Brinker Clamp B4, Coltene/Whaledent Inc., Cuyahoga Falls, OH, USA) were placed on the specific tooth to which restoration would be bonded [Figure 28]. The placement sequence of the ceramic restorations was first #8



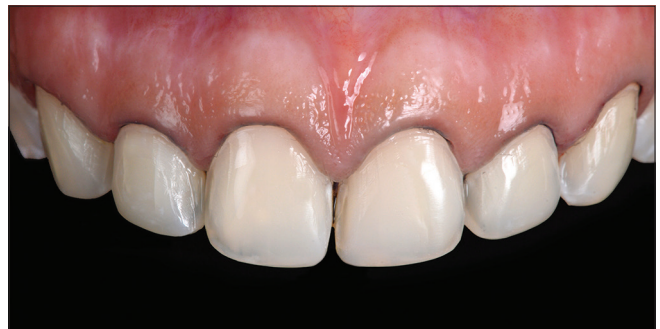**Figure 11:** Polishing tooth preparations with coarse polishing disc



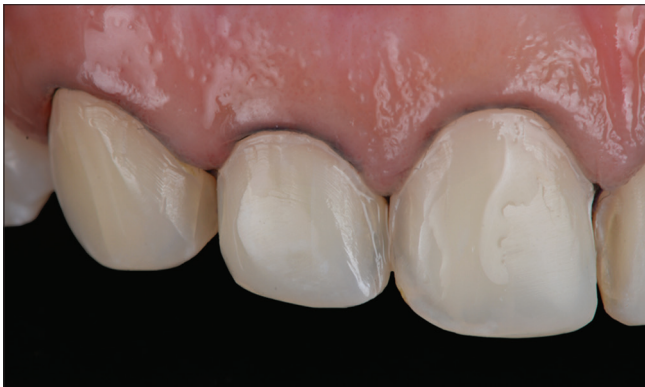**Figure 12:** Polishing tooth preparations with medium polishing disc



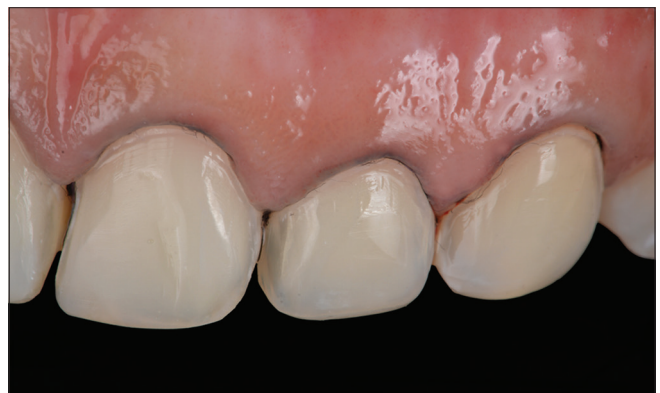**Figure 13:** Polishing tooth preparations with superfine polishing disc



**Figure 14:** Polished final preparation frontal view



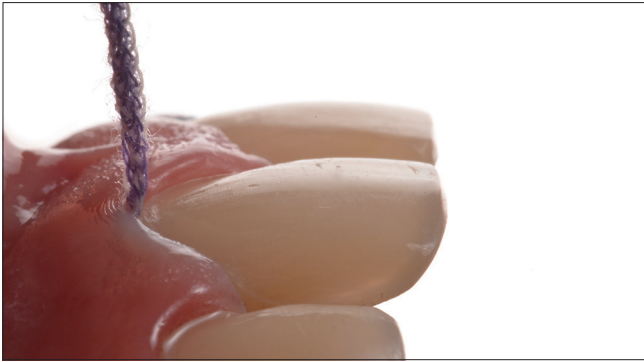**Figure 15:** Polished final preparation left-side view



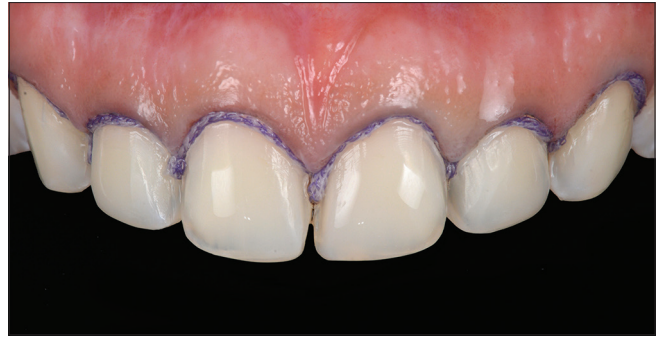**Figure 16:** Polished final preparation right-side view

and #9, then #7 and #10, and finally, #6 and #11. The try-in of the final restorations was performed with the try-in paste according to the manufacture recommendations. After the try-in and approval of the patient, the ceramic restorations received hydrofluoric acid surface treatment (IPS Ceramic Etching Gel, Ivoclar Vivadent) for 60 s, followed by rinsing and drying. Restorations were submerged in water and alcohol in an ultrasonic bath (5300 Sweep Ultrasonic Cleaner, Quala Dental Products, Nashville, TN, USA) for 5 min in order to remove any remaining acid. Next, silane (Monobond-S, Ivoclar Vivadent) was applied for 60 s, and then, the restoration was oil-free air-dried. The tooth surface was first treated with 32% phosphoric acid gel (Uni-

Etch w/Benzalkonium Chloride, Bisco Dental, Schaumburg, IL, USA) for 30 s and then rinsed and gently dried. Then, primer and adhesive were applied, air thinned (OptiBond FL, Kerr Dental, Orange, CA, USA) following the manufacturer's instructions, and light cured (VALO LED curing Light, Ultradent Products Inc.) for 20 s. Before the cementation of the veneers on the teeth #8 and #9, adjacent teeth were cover with Teflon tape to protect and avoid bonding agent and cement on the margins. A light-cure resin cement (Variolink Esthetic LC, Ivoclar Vivadent) was applied to both veneers for #8 and #9, and both the veneers were simultaneously seated on the teeth # 8–9 [Figure 29]. The excess of cement was removed with a microbrush and floss in the interproximal surfaces before light curing for



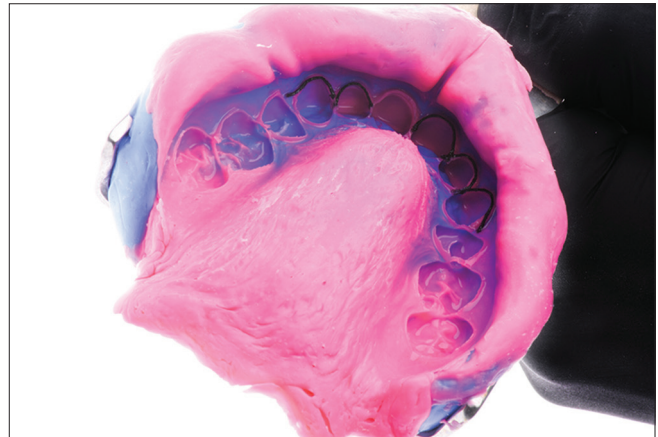
**Figure 17:** Packing cord before final impression



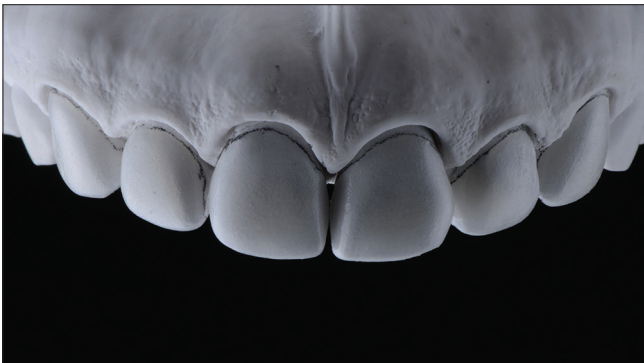**Figure 18:** Double cord impression technique for final impression



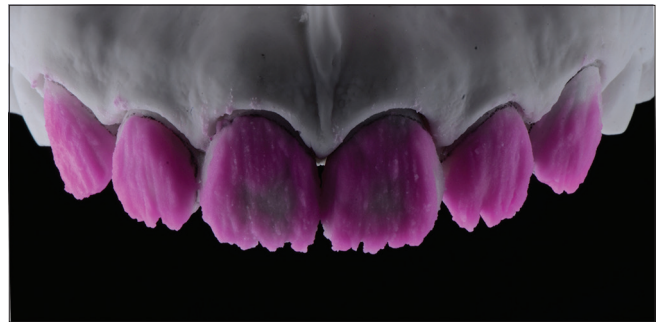**Figure 19:** Final impression intraorally



**Figure 20:** Final impression made



**Figure 21:** Master cast and alveolar dies fabricated



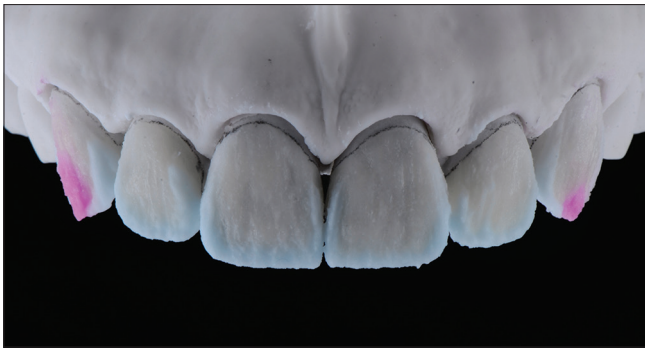
**Figure 22:** Dentin characterization in the feldspathic veneer fabrication

20 s on the facial, 20 s on mesial, 20 s on distal, and 20 s on the incisal surface. The same sequence was followed for the teeth and veneers on #7 and #10 and finally #6 and #11 [Figures 30 and 31]. Glycerin gel was then applied to the ceramic surfaces in order to prevent an oxygen inhibition layer (Liquid Strip, Ivoclar Vivadent), and the surfaces were again light cured for 20 s each.

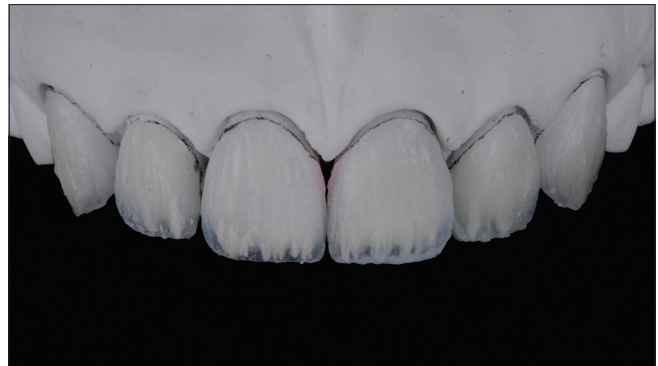
The excess of cement on the cervical area was removed with a #12 blade (Surgical Blade number 12, Salvin Dental Specialties, Charlotte, NC, USA), and the rubber dam was removed occlusion; excursive movements and protrusion were checked. The patient was pleased with the final outcome [Figure 32]. An occlusal guard was provided to wear at night in order to prevent any damage to the restorations. A 2-year follow-up was performed, and the patient was still pleased with the clinical result [Figures 33 and 34].

## DISCUSSION

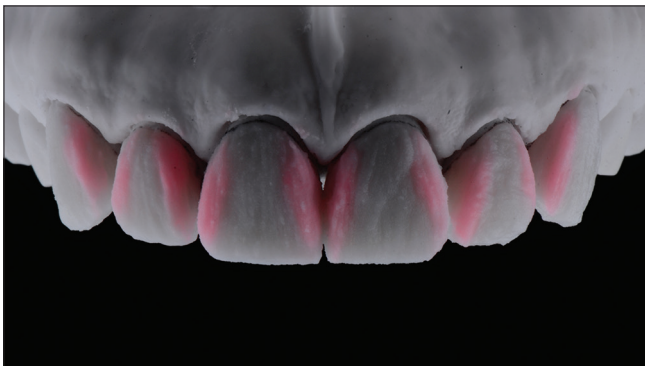
This clinical report describes how a well-planned diagnostic evaluation helps us to obtain desirable results at the end of the treatment and fulfill a patient's high esthetic demands. The wax-up information is transferred to the patient's mouth in order to provide a physical evaluation of the tentative design of the final restoration. At this stage, the patient has the opportunity to request modifications as needed and have a better idea of the dimensions of the final restorations according to the lips, smile, and facial symmetry. From the clinician perspective, the mock-up technique provides the opportunity to evaluate the esthetic results and at the same time provides a guide for a conservative reduction of the teeth. Reduction grooves in the diagnostic mock-up help the clinician to have a well-controlled



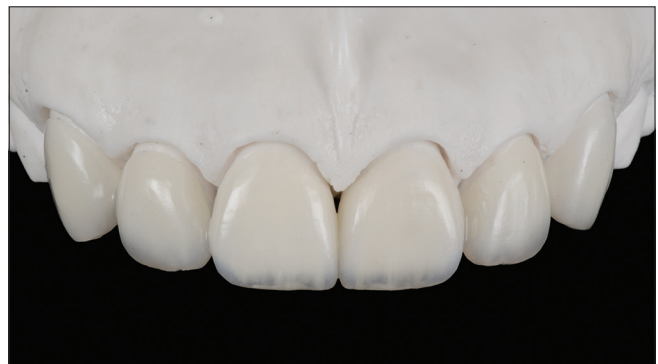**Figure 23:** Enamel characterization in the feldspathic veneer fabrication



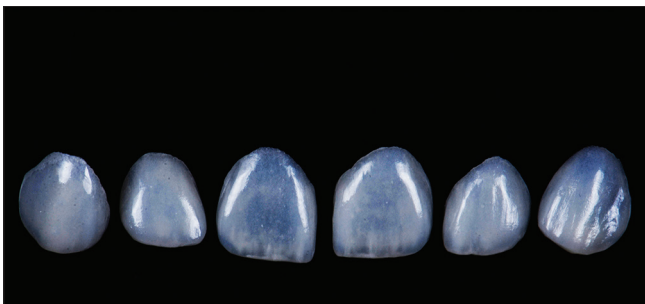
**Figure 24:** Incisal edge characterization in the feldspathic veneer fabrication



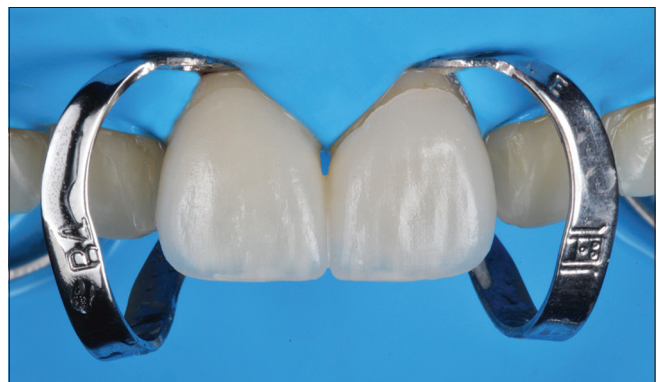**Figure 25:** Line angles definition in the feldspathic veneer fabrication



**Figure 26:** Feldspathic veneers fabricated



**Figure 27:** Ultra-thin feldspathic veneers fabricated



**Figure 28:** Rubber dam isolation for bonding ceramic veneers

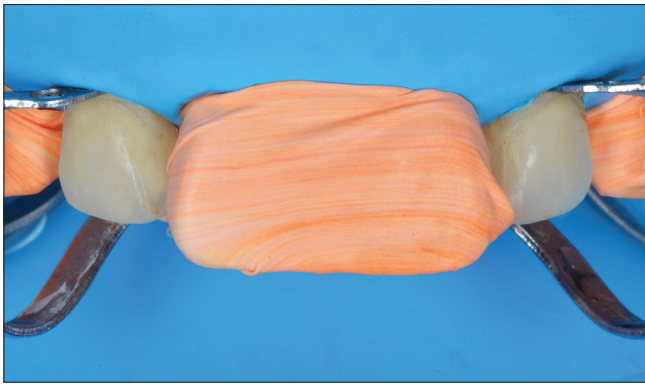
tooth preparation. Experienced restorative clinicians may not need any reduction groove in order to achieve ideal tooth reduction, but the authors highly recommend them in order to gain experience with these conservative preparations.

Complete isolation of the teeth during the final cementation with rubber dam is used in order to achieve ideal results with the adhesive materials. This clinical report demonstrated a technique in which a rubber dam was placed from the second premolar right to the second premolar left in order to secure with clamp retainers, and individual clamps were placed on each pair of teeth during the cementation of the ceramic veneers. This type isolation provides several advantages such as preventing contamination of the working field by saliva, blood, and sulcular fluids. Moreover, it improved the direct visibility because the rubber dam retracts the cheeks, lips, and tongue while working intraorally. It also prevents aspiration and laceration

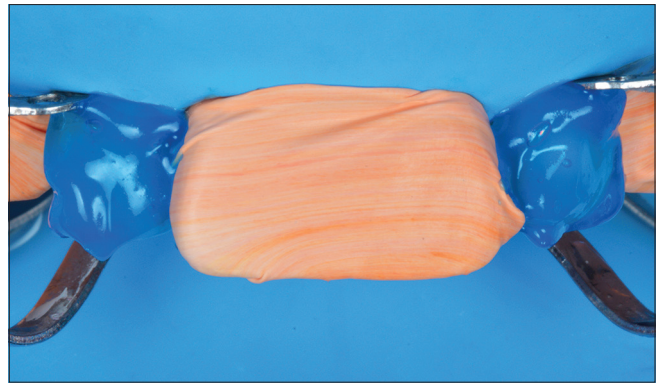
from instruments and speeds up the treatment procedure because the restorative dentist can focus on the clinical steps without worrying about the patient closing mouth. Obviously, clinicians can bond final restorations without providing total isolation with a rubber dam; however, minimal contamination may compromise the effectiveness of the bonding agent. Furthermore, the restorative dentist will need meticulous help from dental assistants and patient's cooperation in order to keep the working field without contamination.

## CONCLUSION

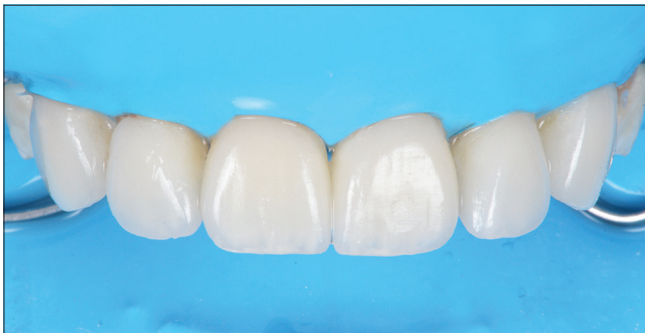The use of the intraoral diagnostic mock-up technique during the tooth preparation provides the opportunity to



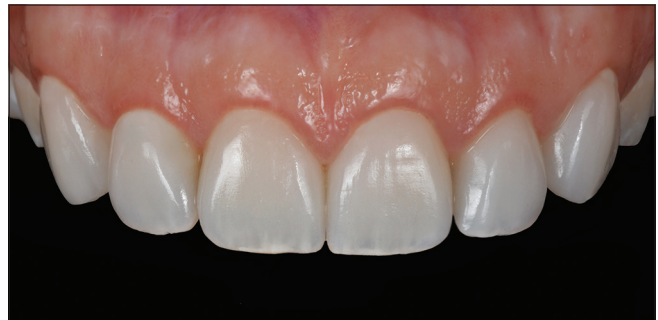**Figure 29:** Clamps of lateral incisors prior bonding ceramic restorations



**Figure 30:** Acid etching on lateral incisors prior bonding ceramic restorations



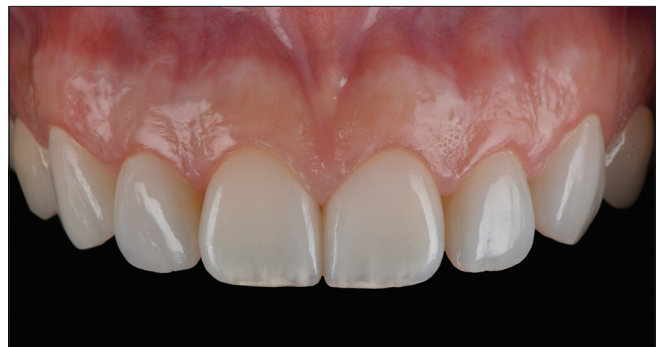**Figure 31:** Ceramic veneers bonded under rubber dam isolation



**Figure 32:** Final bonded restorations



**Figure 33:** Two-year follow-up smile



**Figure 34:** Two-year follow-up intraoral

have a controlled reduction needed for conservative veneer preparations. The goal for any bonding restoration is to maintain the tooth preparation in enamel in order to achieve an optimal bonded restoration. The application of complete isolation with rubber dam is needed in order to prevent contamination of the working field by saliva, blood, and sulcular fluids around the neck of the tooth. A well-planned diagnostic evaluation and execution of it with a conservative approach should improve the longevity of the restorations.

#### **Financial support and sponsorship**

Nil.

#### **Conflicts of interest**

There are no conflicts of interest.

#### **REFERENCES**

1. Nakabayashi N, Kojima K, Masuhara E. The promotion of adhesion by the infiltration of monomers into tooth substrates. *J Biomed Mater Res* 1982;16:265-73.
2. Van Meerbeek B, Vanherle G, Lambrechts P, Braem M. Dentin- and enamel-bonding agents. *Curr Opin Dent* 1992;2:117-27.
3. Horn HR. Porcelain laminate veneers bonded to etched enamel. *Dent Clin North Am* 1983;27:671-84.
4. Peumans M, De Munck J, Fieuws S, Lambrechts P, Vanherle G, Van Meerbeek B. A prospective ten-year clinical trial of porcelain veneers. *J Adhes Dent* 2004;6:65-76.
5. Dumfahrt H, Schäffer H. Porcelain laminate veneers. A retrospective evaluation after 1 to 10 years of service: Part II – Clinical results. *Int J Prosthodont* 2000;13:9-18.
6. Chen YW, Raigrodski AJ. A conservative approach for treating young adult

- patients with porcelain laminate veneers. *J Esthet Restor Dent* 2008;20:223-36.
7. Holm C, Tidehag P, Tillberg A, Molin M. Longevity and quality of FPDs: A retrospective study of restorations 30, 20, and 10 years after insertion. *Int J Prosthodont* 2003;16:283-9.
  8. Libby G, Arcuri MR, LaVelle WE, Hebl L. Longevity of fixed partial dentures. *J Prosthet Dent* 1997;78:127-31.
  9. Peumans M, Van Meerbeek B, Lambrechts P, Vanherle G. Porcelain veneers: A review of the literature. *J Dent* 2000;28:163-77.
  10. Wakiaga J, Brunton P, Silikas N, Glenny AM. Direct versus indirect veneer restorations for intrinsic dental stains. *Cochrane Database Syst Rev* 2004; CD004347.
  11. Edelhoff D, Sorensen JA. Tooth structure removal associated with various preparation designs for anterior teeth. *J Prosthet Dent* 2002;87:503-9.
  12. Öztürk E, Bolay Ş, Hickel R, Ilie N. Shear bond strength of porcelain laminate veneers to enamel, dentine and enamel-dentine complex bonded with different adhesive luting systems. *J Dent* 2013;41:97-105.
  13. Magne P, Douglas WH. Optimization of resilience and stress distribution in porcelain veneers for the treatment of crown-fractured incisors. *Int J Periodontics Restorative Dent* 1999;19:543-53.
  14. Magne P, Versluis A, Douglas WH. Effect of luting composite shrinkage and thermal loads on the stress distribution in porcelain laminate veneers. *J Prosthet Dent* 1999;81:335-44.
  15. Magne P, Kwon KR, Belser UC, Hodges JS, Douglas WH. Crack propensity of porcelain laminate veneers: A simulated operator evaluation. *J Prosthet Dent* 1999;81:327-34.
  16. Petridis HP, Zekeridou A, Malliari M, Tortopidis D, Koidis P. Survival of ceramic veneers made of different materials after a minimum follow-up period of five years: A systematic review and meta-analysis. *Eur J Esthet Dent* 2012;7:138-52.
  17. Lin T, Liu P, Ramp L, Essig M, Givan D, Pan Y. Fracture resistance and marginal discrepancy of porcelain laminate veneers influenced by preparation design and restorative material *in vitro*. *J Dentistry* 2012;40:202-9.
  18. Lacy AM, Wada C, Du W, Watanabe L. *In vitro* microleakage at the gingival margin of porcelain and resin veneers. *J Prosthet Dent* 1992;67:7-10.
  19. Della Bona A, Kelly JR. A variety of patient factors may influence porcelain veneer survival over a 10-year period. *J Evid Based Dent Pract* 2010;10:35-6.
  20. Carpena G, Ballarin A, Aguiar J. New ceramics approach for contact lens. *Odvotos Int J Dent Sci* 2015;17:12-8.
  21. Strassler HE. Minimally invasive porcelain veneers: Indications for a conservative esthetic dentistry treatment modality. *Gen Dent* 2007;55:686-94.
  22. Conrad HJ, Seong WJ, Pesun IJ. Current ceramic materials and systems with clinical recommendations: A systematic review. *J Prosthet Dent* 2007;98:389-404.
  23. Trinkner TF, Roberts M. Fluorapatite-leucite glass ceramic veneers for aesthetic anterior restorations. *Pract Proced Aesthet Dent* 2001;13:37-41.
  24. Soares PV, Spini PH, Carvalho VF, Souza PG, Gonzaga RC, Tolentino AB, *et al.* Esthetic rehabilitation with laminated ceramic veneers reinforced by lithium disilicate. *Quintessence Int* 2014;45:129-33.
  25. Manicone PF, Rossi Iommetti P, Raffaelli L. An overview of zirconia ceramics: Basic properties and clinical applications. *J Dent* 2007;35:819-26.
  26. Sadowsky SJ. An overview of treatment considerations for esthetic restorations: A review of the literature. *J Prosthet Dent* 2006;96:433-42.
  27. Cöttert HS, Dündar M, Öztürk B. The effect of various preparation designs on the survival of porcelain laminate veneers. *J Adhes Dent* 2009;11:405-11.
  28. Carlyle LW 3<sup>rd</sup>, Richardson JT. The diagnostic wax-up: An aid in treatment planning. *Tex Dent J* 1985;102:10-2.
  29. Phillips K, Morgan R. The acrylic occlusal plane guide: A tool for esthetic occlusal reconstruction. *Compend Contin Educ Dent* 2001;22:302-4, 306.
  30. Preston JD. A systematic approach to the control of esthetic form. *J Prosthet Dent* 1976;35:393-402.
  31. Yuodelis RA, Faucher R. Provisional restorations: An integrated approach to periodontics and restorative dentistry. *Dent Clin North Am* 1980;24:285-303.
  32. European Society of Endodontology. Quality guidelines for endodontic treatment: Consensus report of the European Society of Endodontology. *Int Endod J* 2006;39:921-30.
  33. Ahmad IA. Rubber dam usage for endodontic treatment: A review. *Int Endod J* 2009;42:963-72.