

# Symptomatic Neurocutaneous Melanosis with Unusual Benign Course: A Case Report and Review

Baker Mustafa Ayyash<sup>1</sup>, Waseem Mahmoud Fathalla<sup>2</sup>

Departments of <sup>1</sup>Pediatrics and <sup>2</sup>Pediatric Neurology, Mafraq Hospital, Abu Dhabi, United Arab Emirates

## Abstract

Neurocutaneous melanosis (NCM) is a rare, congenital, noninherited neurocutaneous syndrome characterized by the presence of “multiple or large congenital nevi” with central nervous system melanocytic deposits. Majority of cases are asymptomatic. Symptomatic cases present with hydrocephalus and signs and symptoms of increased intracranial pressure. The latter is associated with poor prognosis. We herein report an asymptomatic patient with giant congenital melanocytic nevi. He had a screening magnetic resonance imaging study at the age of 2 months that showed T1 hyperintensities in the region of amygdala of both temporal lobes. He was asymptomatic until the age of 4 years when he presented with seizure activity. A diagnosis of NCM was made. He was discharged on emergency antiepileptic medication. On regular follow-up, he remained seizure free for 1 year after the first episode of seizure. Unlike other cases reported in literature, this, to the best of our knowledge, is the first report of nonprogressive symptomatic NCM.

**Keywords:** Neurocutaneous melanosis, congenital melanocytic nevi, leptomeningeal melanosis, prognosis

## INTRODUCTION

Neurocutaneous melanosis (NCM) is a very uncommon, nonfamilial “neurocutaneous syndrome.” It is characterized by the presence of “multiple or large congenital nevi” with central nervous system (CNS) melanocytic deposits.<sup>[1]</sup> Rokitansky published the first report of NCM in 1861. In his report, he described a mentally disabled girl who was born with a “large congenital melanocytic nevus” and eventually died due to hydrocephalus complications. At autopsy, he found that she had brain melanocytic accumulations.<sup>[2]</sup> It was named NCM in 1948 by Van Bogaert. The accurate incident of NCM is unidentified. It is very rare, with only about 100–200 cases reported. Both sexes are affected equally, and there is no racial or ethnic predominance identified.<sup>[3,4]</sup>

## CASE REPORT

We report a boy who was born by normal vaginal delivery to nonconsanguineous healthy parents with unremarkable term pregnancy. At birth, he had a large hyperpigmented brownish-black patch with well-defined borders, extending over the abdomen mainly on the left side of the trunk and the back (crossing the midline both ventrally and posteriorly)

and extending down over the groin and to the mid-left thigh [Figures 1a and b]. He had also multiple satellite lesions on lower extremities and on the right face. He had normal growth parameters (weight: 3.3 kg, length: 34 cm, and head circumference: 52 cm). Magnetic resonance imaging (MRI) of the brain was done at the age of 2 months as part of routine investigations of giant congenital nevi. It showed symmetrical hyperintensities in the region of amygdala of both temporal lobes [Figure 2]. From neurodevelopment point of view, he was achieving appropriate milestones for age. Family history is negative for similar skin lesions or seizures.

At 4 years of age, he developed seizure activity postdental surgery while he was in recovery room. Seizure activity was described as right facial twitching which lasted for 2 min and aborted spontaneously. He presented to the pediatric neurology clinic for further assessment. On examination, he was vitally and hemodynamically stable. There were no

**Address for correspondence:** Dr. Baker Mustafa Ayyash,  
Department of Pediatrics, Mafraq Hospital,  
Abu Dhabi, United Arab Emirates.  
E-mail: drbakerayyash@hotmail.com

### Access this article online

Quick Response Code:



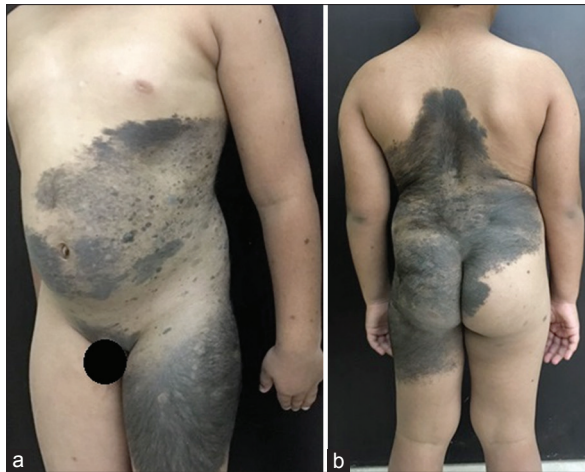Website:  
www.ijmbs.org

DOI:  
10.4103/ijmbs.ijmbs\_53\_17

This is an open access article distributed under the terms of the Creative Commons Attribution-NonCommercial-ShareAlike 3.0 License, which allows others to remix, tweak, and build upon the work non-commercially, as long as the author is credited and the new creations are licensed under the identical terms.

**For reprints contact:** reprints@medknow.com

**How to cite this article:** Ayyash BM, Fathalla WM. Symptomatic neurocutaneous melanosis with unusual benign course: A case report and review. *Ibnosina J Med Biomed Sci* 2018;10:28-31.



**Figure 1:** Large black macular lesions spread on the left side of the body including abdomen, pubic area, scrotum, and left thigh (a) scattered satellite lesions are seen. There is also a large black patch on the back, buttocks and left thigh (b)

significant findings on examination other than the congenital nevi. Electroencephalogram showed a borderline posterior rhythm slowing (could be a function of drowsiness); there were no epileptiform discharges. Based on his clinical and radiological findings, the diagnosis of NCM was made. He was not started on any treatment.

The child was discharged on emergency anticonvulsant medication and advised for regular follow-up with dermatology and pediatric neurology.

Currently, he is 5 years of age and has not developed any neurological symptoms for more than 12 months. Unlike other symptomatic cases reported in the literature, the present case did not show any progressive features of the disease.

## DISCUSSION

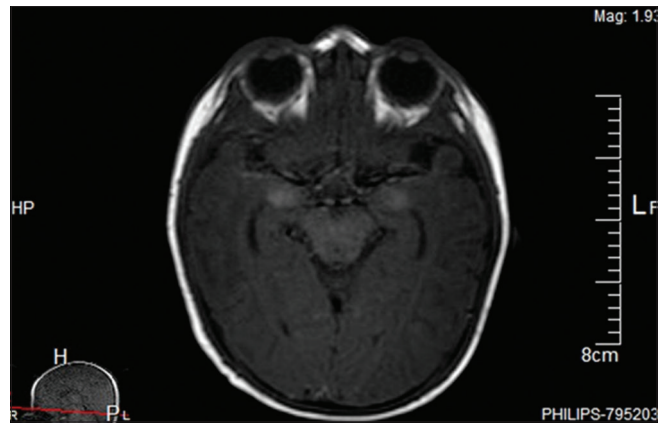
### Pathophysiology and genetics

Although the exact pathophysiology of NCM is not completely understood, it is suggested to be related to an embryonic defect that impedes “migration” of melanoblast cells from the “neural crest” to their final destinations in the skin and brain.<sup>[5]</sup>

Kinsler *et al.* recognized “Oncogenic missense mutations in codon 61 of NRAS” in the diseased skin and brain tissues in 80% (12 of 15) of children with NCM. However, these mutations were not found in unaffected tissues of the same patients, suggesting a mosaic nature of the oncogenic NRAS mutations.<sup>[6]</sup>

Moreover, in their prospective study, Salgado *et al.* demonstrated *BRAF*<sup>V600E</sup> mutations affecting some patients with NCM patients. The importance of this study is that patients identified with these mutations might benefit from using BRAF-targeted therapy such as vemurafenib and dabrafenib.<sup>[7]</sup>

However, these mutations are not found in every NCM, and more investigations are needed to be carried out.<sup>[8]</sup>



**Figure 2:** Magnetic resonance imaging (at age of 2 months) showed symmetrical hyperintensities in the region of amygdala of the both temporal lobes

### Associated syndromes

NCM is usually an isolated condition. However, multiple associations with other neurocutaneous disorders (Sturge–Weber syndrome, von Recklinghausen disease, or neurofibromatosis) and CNS structural abnormalities have been reported. Other important associations include Dandy–Walker complex, posterior fossa cysts, lipoma of the spine, arachnoid cyst, and tethered spinal cord.<sup>[9–11]</sup> The association of NCM with other abnormalities increases the risk of symptomatic NCM and is considered a poor prognostic factor.

Interestingly, there are some reports of very rare and unusual associations with NCM. For example, there is a report of a 12-year-old boy known to have NCM presenting with symptoms of new-onset type 1 diabetes. However, with proper treatment of his CNS malignant melanoma, the diabetes was resolved, and his antiglutamic acid decarboxylase (GAD) antibodies disappeared. It was suggested that the GAD antibodies may be attributed to a paraneoplastic phenomenon related to his malignant melanoma.<sup>[12]</sup> In another case report, a male newborn with NCM was found to have Hirschsprung’s disease. This association supported the idea of a similar pathogenesis of both diseases since they arose from neural crest migration defects.<sup>[13]</sup> Moreover, acute disseminated encephalomyelitis has been described in a 10-year-old patient with NCM.<sup>[14]</sup>

### Clinical features

#### Dermatological manifestations

Cutaneous lesions of NCM are characterized by hyperpigmented dark brown-to-black hairy nevi. In most of the cases, there will be a large (giant) nevus that is surrounded by multiple smaller satellite lesions.<sup>[1]</sup> Giant (large) nevi typically have a “cape-shaped or bathing suit” distribution. These lesions are present since birth and are growing proportionally to the patient growth. However, new lesions might appear slowly, and there is a possibility of malignant transformation.

There are some identified risk factors for developing NCM such as a number of satellite lesions and site and size of the giant

nevi.<sup>[15-18]</sup> Sibbald *et al.* found that, among all risk factors, the number of satellite lesions is the most significant.<sup>[15]</sup> According to Marghoob *et al.*, having >20 satellite lesions in patients with giant melanocytic nevi increased the likelihood of developing NCM by fivefolds as compared to those with ≤20 satellite lesions. They found also that 96% of NCM patients have their giant nevi located on “the posterior axis.”<sup>[16]</sup>

### Neurological manifestations

NCM may be asymptomatic or symptomatic. Asymptomatic NCM illustrates patients who have CNS melanosis identified by brain MRI without neurologic symptoms. On the other hand, patients with symptomatic NCM usually present with neurological manifestations such as convulsions and symptoms of raised intracranial pressure due to hydrocephalus such as vomiting, irritability, and headache. Infants present with poor feeding, irritability, and rapid increase in head circumference. Hydrocephalus is believed to develop as a result of heavy infiltration of melanocytes in the brain stem causing disturbance of cerebrospinal fluid resorption process. Other symptoms might include developmental delay and cranial nerve palsies. Symptoms may develop as early as 2 years of age.<sup>[2]</sup> There was a case of NCM reported in literature presented with quadriparesis.<sup>[19]</sup> Interestingly, Uguen *et al.* reported two cases of severe hydrocephalus of prenatal onset related to NCM.<sup>[20]</sup>

### Diagnostic criteria

The diagnosis of NCM is made depending on clinical manifestations and neuroimaging. The diagnostic criteria of NCM were first described by Fox in 1972. In 1991, Kadonaga and Frieden established “the currently accepted” criteria to diagnose NCM and are as follows: (1) large congenital melanocytic nevi (≥20 cm in adults, or ≥9 cm on the head or >6 cm on the trunk in neonate) or multiple (>3) associated with “meningeal melanosis or melanoma;” (2) absence of skin melanoma, apart from patients who have benign meningeal lesions approved by biopsy; (3) absence of meningeal melanoma, apart from patients who have benign skin lesions approved by biopsy.<sup>[21]</sup>

Patients who are found to have both cutaneous and meningeal melanoma at the same time are not included in the diagnosis of NCM due to possibility of meningeal melanoma being developed as a result of metastasis from the skin.

### Imaging

Although it is not the gold standard to diagnose NCM, transfontanellar ultrasound (US) can show the CNS lesions of NCM as echogenic foci. Knowing this can alert the radiologists to the potential diagnosis of NCM given the clinical history of congenital melanocytic nevi. Differential diagnosis of echogenic lesions on US in a neonate would include hemorrhage, primary or metastatic neoplasm, and hamartomas.<sup>[22]</sup>

Gadolinium-based MRI of the brain and spine is the gold standard. It is suggested to be done before 6 months of age, to avoid misinterpretation of normal myelination of the brain as

melanin deposits. The typical MRI finding is “T1 shortening” of the affected structures, which will appear as “hyperintensity on T1-weighted images.”<sup>[1]</sup>

The anterior temporal lobe, particularly the amygdala (as in our case), is the most frequent location where melanin deposits accumulate. Other locations include basilar meninges, brainstem, thalami, and base of the frontal lobe.<sup>[1,23]</sup>

In very few articles, “age-related MRI changes” in patients with NCM have been noticed.<sup>[1]</sup> For example, Bekiesi' nska-Figatowska *et al.* reported changes of MRI findings in seven patients with NCM as they get older. The changes were variable. Regression of MRI lesions was found in six cases, but also one case showed the progression of the lesions.<sup>[24]</sup> This study is the only one (in our knowledge) showing a case of progressive MRI lesions. All other reports show regression of the MRI lesions.

### Treatment

In general, there is no need to treat patients with asymptomatic NCM. There are some suggestions of preemptive interventions such as placing ventricular shunt if there are MRI findings that suggest progressive pathology that might lead to hydrocephalus in the future. However, the best practice is to interfere once the patient becomes symptomatic.<sup>[1,21]</sup>

On the other hand, there is not much we can do in terms of treatment for symptomatic NCM. Treatment options are so limited and usually unsatisfactory. The aim of current treatment options is palliative. These options include surgery, chemotherapy, and radiotherapy. Placement of a shunt with a filter is considered the best palliative option. The filter is used to prevent melanoma dissemination into the peritoneal cavity.<sup>[23]</sup>

Recently, experimental treatment with a mitogen-activated protein kinase kinase (MEK) inhibitor, MEK162, has been used in a patient with symptomatic NCM. The patient expired after 5 days of starting therapy which is too soon to anticipate any clinical efficacy of the treatment. Hence, the impact of MEK inhibitor was examined “at the protein level by immunohistochemical and Western Blot analyses” using specific antibodies. The study showed a promising effect of the NRAS-targeted therapy. More studies are required to evaluate the real effect of the treatment on symptomatic NCM.<sup>[8]</sup>

### Follow-up

For patients with asymptomatic NCM, they should be followed with regular clinical evaluation as well as serial MRI scans. However, there is no consensus on the interval of the MRI scans, and the decision should be judged case by case. Further to this, it is very important to have regular lifelong examinations of the lesions due to potential transformation into malignant melanoma.<sup>[25]</sup>

The role of pediatricians in the management of children with NCM is essential. Close follow-up with documentation of the size of nevi, measurement of head circumference, and neurodevelopmental assessment is necessary.<sup>[26]</sup>

## Prognosis

It is not easy to predict the outcome of asymptomatic NCM patients. However, the outcome of symptomatic NCM is extremely poor, even if not associated with malignant melanoma. NCM association with Dandy–Walker complex suggests more worrisome prognosis.

## Declaration of patient consent

The authors certify that they have obtained all appropriate patient consent forms. In the form the patient's guardian has given his consent for patient's images and other clinical information to be reported in the journal. He understands that names and initials will not be published and due efforts will be made to conceal their identity, but anonymity cannot be guaranteed.

## Disclosures

All authors contributed to the preparation, revision, and approval of the final version.

## Financial support and sponsorship

Nil.

## Conflicts of interest

There are no conflicts of interest.

## Compliance with ethical principles

A written consent was obtained from the father for photographs and reporting the case.

## REFERENCES

- Scattolin M, Lin J, Peruchi M, Rocha A, Masruha M, Vilanova LC. Neurocutaneous melanosis: Follow-up and literature review. *J Neuroradiol* 2011;38:313-8.
- Thiele EA, Korf BR. *Swaiman's Pediatric Neurology: Principles and Practice*. Edinburgh: Elsevier; 2012.
- Gocmen R, Guler E, Arslan EA. A case of neurocutaneous melanosis and neuroimaging findings. *J Radiol Case Rep* 2015;9:1-6.
- Shih F, Yip S, McDonald PJ, Chudley AE, Del Bigio MR. Oncogenic codon 13 NRAS mutation in a primary mesenchymal brain neoplasm and nevus of a child with neurocutaneous melanosis. *Acta Neuropathol Commun* 2014;2:140.
- Sarnat HB, Flores-Sarnat L. Embryology of the neural crest: Its inductive role in the neurocutaneous syndromes. *J Child Neurol* 2005;20:637-43.
- Kinsler VA, Thomas AC, Ishida M, Bulstrode NW, Loughlin S, Hing S, *et al*. Multiple congenital melanocytic nevi and neurocutaneous melanosis are caused by postzygotic mutations in codon 61 of NRAS. *J Invest Dermatol* 2013;133:2229-36.
- Salgado CM, Basu D, Nikiforova M, Bauer BS, Johnson D, Rundell V, *et al*. BRAF mutations are also associated with neurocutaneous melanocytosis and large/giant congenital melanocytic nevi. *Pediatr Dev Pathol* 2015;18:1-9.
- Küstters-Vandeveldel HV, Willemsen AE, Groenen PJ, Küsters B, Lammens M, Wesseling P, *et al*. Experimental treatment of NRAS-mutated neurocutaneous melanocytosis with MEK162, a MEK-inhibitor. *Acta Neuropathol Commun* 2014;2:41.
- Tian AG, Foster KA, Jakacki RI, Reyes-Múgica M, Greene S. Neurocutaneous melanosis is associated with tethered spinal cord. *Childs Nerv Syst* 2015;31:115-21.
- Sung KS, Song YJ. Neurocutaneous melanosis in association with Dandy-Walker complex with extensive intracerebral and spinal cord involvement. *J Korean Neurosurg Soc* 2014;56:61-5.
- Swar MO, Mahgoub SM, Yassin RO, Osman AM. Dandy-walker malformation and neurocutaneous melanosis in a three-month-old infant. *Sudan J Paediatr* 2013;13:61-5.
- Joseph KR, Difazio MP, Hartman KR, Ney JP. Neurocutaneous melanosis associated with autoimmune diabetes mellitus. *Neurology* 2007;68:1862-3.
- Iwabuchi T, Shimotake T, Furukawa T, Tsuda T, Aoi S, Iwai N, *et al*. Neurocutaneous melanosis associated with Hirschsprung's disease in a male neonate. *J Pediatr Surg* 2005;40:E11-3.
- Asano T, Hamada H, Takita Y, Watanabe M, Sugano H, Sudoh M, *et al*. Neurocutaneous melanosis with acute disseminated encephalomyelitis. *Eur J Pediatr* 2007;166:1065-6.
- Sibbald C, Randhawa H, Branson H, Pope E. Neurocutaneous melanosis and congenital melanocytic naevi: A retrospective review of clinical and radiological characteristics. *Br J Dermatol* 2015;173:1522-4.
- Marghoob AA, Dusza S, Oliveria S, Halpern AC. Number of satellite nevi as a correlate for neurocutaneous melanocytosis in patients with large congenital melanocytic nevi. *Arch Dermatol* 2004;140:171-5.
- DeDavid M, Orlow SJ, Provost N, Marghoob AA, Rao BK, Wasti Q, *et al*. Neurocutaneous melanosis: Clinical features of large congenital melanocytic nevi in patients with manifest central nervous system melanosis. *J Am Acad Dermatol* 1996;35:529-38.
- Lovett A, Maari C, Decarie JC, Marcoux D, McCuaig C, Hatami A, *et al*. Large congenital melanocytic nevi and neurocutaneous melanocytosis: One pediatric center's experience. *J Am Acad Dermatol* 2009;61:766-74.
- Khera S, Sarkar R, Jain RK, Saxena AK. Neurocutaneous melanosis: An atypical presentation. *J Dermatol* 2005;32:602-5.
- Uguen A, Laurent C, Samaison L, Boisselier B, Talagas M, Costa S, *et al*. Severe hydrocephalus caused by diffuse leptomeningeal and neurocutaneous melanocytosis of antenatal onset: A clinical, pathologic, and molecular study of 2 cases. *Hum Pathol* 2015;46:1189-96.
- Kadonaga JN, Frieden IJ. Neurocutaneous melanosis: Definition and review of the literature. *J Am Acad Dermatol* 1991;24:747-55.
- Chen YA, Woodley-Cook J, Sgro M, Bharatha A. Sonographic and magnetic resonance imaging findings of neurocutaneous melanosis. *Radiol Case Rep* 2016;11:29-32.
- Moreira BL, Grunewald T, Côrtes AA, Marussi VH, do Amaral LL. Neurocutaneous melanosis. *Radiol Bras* 2016;49:412-3.
- Bekiesińska-Figatowska M, Sawicka E, Żak K, Szczygielski O. Age related changes in brain MR appearance in the course of neurocutaneous melanosis. *Eur J Radiol* 2016;85:1427-31.
- Bittencourt FV, Marghoob AA, Kopf AW, Koenig KL, Bart RS. Large congenital melanocytic nevi and the risk for development of malignant melanoma and neurocutaneous melanocytosis. *Pediatrics* 2000;106:736-41.
- Boran P, Yücelten D, Subaşı B, Berenjian A. Pediatrician's role in the management of giant congenital melanocytic nevus: Case report. *Turk Klin Pediatr* 2015;24:72-5.

### Reviewers:

Mohamed El-Fikki (Alexandria, Egypt)  
Elhadi Aburawi (Al Ain, UAE)

### Editors:

Salem A Beshyah (Abu Dhabi, UAE)  
Elmahdi Elkhammas (Columbus, Ohio, USA)