

Syndromes with Involvement of Multiple Cranial Nerves: An Overview

Dear Editor,

We read the article entitled “Retropharyngeal soft-tissue mass with multiple cranial neuropathies” on the esteemed “Ibnosina Journal of Medicine and Biomedical Sciences” with great interest. Bennour *et al.* reported a case of a middle-aged male who presented with hemifacial pain. Later, the patient developed lesions from the third to the twelfth cranial nerves. A diagnosis of inflammatory pseudotumor of the retropharynx infiltrating the base of the skull and extending to the cavernous sinus was made.^[1]

Herein, we would like to provide a table [Table 1] and a figure [Figure 1] to better comprehend the syndromes with the involvement of multiple cranial nerves.^[2-5] Any process that affects the intracranial region may lead to lesions in more than one cranial nerve. In some conditions, a group of nerves can be affected in a specific anatomical region or following some anatomical pattern.^[2] Throughout the years, many studies showed patterns of lesions and the discoverers entitled these patterns with their own names; some of these eponyms are present in Table 1. These syndromes usually develop gradually and their clinical presentation may be complex, which explains their late diagnosis not being infrequent.^[4]

We included the Avellis', Jackson's, and Schmidt's syndromes to the table and figure. Some authors believe that these syndromes belong to the brainstem syndrome because they can also appear due to the vascular lesions to the medulla. However, it is worthy of mentioning that epidemiological studies showed that they more commonly occur due to extramedullary lesions.^[2] With this background,

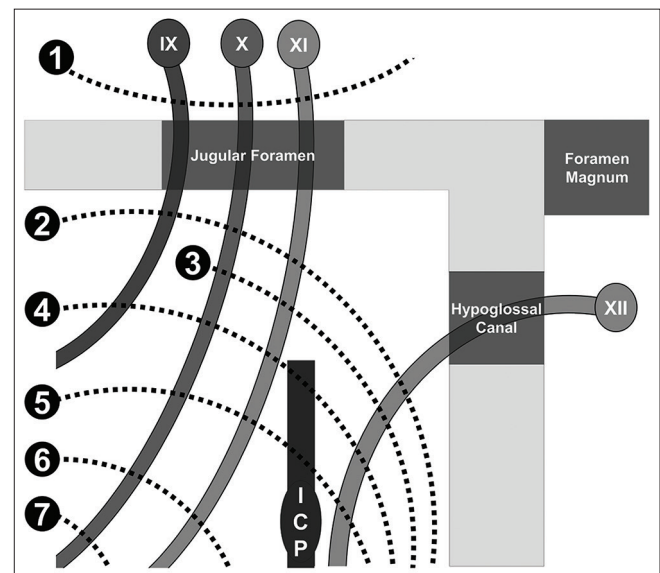


Figure 1: Schematic diagram of the jugular foramen syndromes. 1: Vernet (IX, X, and XI); 2: Collet-Sicard (IX, X, XI, and XII); 3: Jackson (X, XI, and XII); 4: Villaret (IX, X, XI, and XII + ICP); 5: Tapia (X, XI, and XII + ICP); 6: Schmidt (X and XI); 7: Avellis (X). ICP: Internal carotid plexus

Table 1: Syndromes with involvement of multiple cranial nerves

Eponym	Lesion location	Cranial nerves and other structures' involvement	Most common lesion leading to the syndrome (epidemiological studies)
Avellis	Medullary tegmentum	X	Vertebral artery thrombosis
Collet-Sicard (MacKenzie, Lannois-Jouty)	Posterior lateral condylar space	IX, X, XI, and XII	Neoplasm (glomus jugulare tumor)
Foix-Jefferson	Cavernous sinus	III, IV, V (1, 2), and VI + ICP	Tolosa-Hunt syndrome, tumor, and aneurysm
Garcin	Skull base	Variable III-XII	Neoplasm
Gradenigo	Apex of the petrous bone	V and VI	Inflammation and tumor
Jackson	Medullary tegmentum	X, XI, and XII	Extramedullary process
Negro-Jacod	Retrosphenoid space	II, III, IV, V, and VI	Tumor
Schmidt	Lower medullary tegmentum	X and XI	Extramedullary process
Tapia	Retroparotid space	X, XI, and XII + ICP	Tumor
Vernet	Jugular foramen	IX, X, and XI	Tumor, aneurysm, and trauma
Villaret	Retropharyngeal space	IX, X, XI, and XII + ICP	Neoplasm (glomus jugulare tumor)

ICP: Internal carotid plexus

we can assume that the syndrome presented by Bennour *et al.* is Garcin's.^[1] Therefore, we believe that the knowledge of these eponyms can help in the clinical practice to prompt localize the lesion, give a probabilistic etiological diagnosis, and avoid unnecessary examinations.

Author contributions

JPR and ALFC contributed equally. The figure was drawn by JPR.

Financial support and sponsorship

Nil.

Conflicts of interest

There are no conflicts of interest.

Compliance with ethical principles

Not applicable.

**Jamir Pitton Rissardo¹,
Ana Letícia Fornari Caprara¹**

¹Department of Medicine, Federal University of Santa Maria, Santa Maria, Rio Grande Do Sul, Brazil


Address for correspondence: Dr. Jamir Pitton Rissardo,
Rua Roraima, Santa Maria, Rio Grande Do Sul, Brazil.
E-mail: jamirrissardo@gmail.com

Received: 30-12-2019 **Accepted:** 31-12-2019 **Published:** 26-03-2020

REFERENCES

1. Bennour AM, Dughman AA, Elkhamee A. Retropharyngeal soft-tissue mass with multiple cranial neuropathies. *Ibnosina J Med Biomed Sci* 2019;11:185-7.
2. Campbell WW. Brainstem and multiple cranial nerve syndromes. Dejong's the Neurologic Examination. 7th ed. Philadelphia: Lippincott Williams and Wilkins; 2013. p. 335-56.
3. Barker RA, Scolding N, Rowe D, Larner AJ. The AZ of Neurological Practice: A Guide to Clinical Neurology. United Kingdom: Cambridge University Press; 2005. p. 367.
4. Gutiérrez Ríos R, Castrillo Sanz A, Gil Polo C, Zamora García MI, Morollón Sánchez-Mateos N, Mendoza Rodríguez A. Collet-Sicard syndrome. *Neurologia* 2015;30:130-2.
5. Keane JR. Combined VI and XII cranial nerve palsies: A clival syndrome. *Neurology* 2000;54:1540-1.

This is an open access journal, and articles are distributed under the terms of the Creative Commons Attribution-NonCommercial-ShareAlike 4.0 License, which allows others to remix, tweak, and build upon the work non-commercially, as long as appropriate credit is given and the new creations are licensed under the identical terms.

Access this article online	
Quick Response Code: 	Website: www.ijmbs.org
	DOI: 10.4103/ijmbs.ijmbs_87_19

How to cite this article: Rissardo JP, Caprara AL. Syndromes with involvement of multiple cranial nerves: An overview. *Ibnosina J Med Biomed Sci* 2020;12:74-5.

© 2020 Ibnosina Journal of Medicine and Biomedical Sciences | Published by Wolters Kluwer - Medknow

Reviewers:
Not applicable

Editors:
Elmahdi Elkhammas