

A Rare Encounter in Nonsuspecting Circumstances: First Congenital Visceral Leishmaniasis (Kala-Azar) in Libya

Amal Salem Elarabi¹, Zinab Ashour Saad^{1,2}, Walid K Saadawi³, Nadia Milad Aldobea³, Fauzi Abdalla Sagher^{1,2}

¹Department of Pediatric Gastroenterology and Hepatology, Tripoli University Hospital, ²Department of Pediatric, Faculty of Medicine, University of Tripoli, ³National Centre for Disease Control, Tripoli, Libya

Abstract

Congenital transmission of Leishmaniasis is very rare. It occurs through blood exchange from the mother to the child during pregnancy or delivery. We report the first confirmed congenital leishmaniasis in a 4-month-old Libyan boy with prolonged jaundice and hepatosplenomegaly. This was a congenital transmission from his mother who was asymptomatic and not known to have leishmaniasis, which was confirmed after the diagnosis of the infant. Despite treatment, the infant died. The diagnostic approach is illustrated by the case report. Poor obstetric history in the mother may be related to her own undiagnosed kala azar.

Keywords: Congenital kala azar, *Leishmania infantum*, visceral leishmaniasis

INTRODUCTION

Leishmaniasis, a vector-borne disease, is transmitted to humans through the bite of phlebotomine sand flies. *Leishmania donovani*, a protozoan parasite, is the primary causative agent for visceral leishmaniasis (VL). The incubation period after vector transmission is highly variable, typically 2–6 months, yet it may widely vary from 10 days to longer than 10 years. The classical manifestations of VL are persistent fever, weight loss, progressive anemia or pancytopenia, hepatosplenomegaly, and hypergammaglobulinaemia.^[1] Recognized risk factors for leishmaniasis include low socioeconomic status, malnutrition, and poor housing, and there is some evidence of genetic predisposition.^[1]

VL is estimated to affect about 200,000–400,000 cases/year. Majority (>90%) of people who develop VL live in poor rural regions of Bangladesh, Ethiopia, India, Nepal, Sudan, and Brazil.^[1] Nonvector transmission occurs occasionally through blood transfusions, contaminated needles of drug users, organ transplants, or laboratory infection.

Address for correspondence: Prof. Fauzi Abdalla Sagher, Department of Pediatric Gastroenterology, Hepatology and Nutrition, Tripoli University Hospital, Tripoli, Libya. Department of Pediatric, Faculty of Medicine, University of Tripoli, Tripoli, Libya. E-mail: f_sagher@yahoo.com

Submitted: 01-02-2020 **Revised:** 01-02-2020
Accepted: 01-02-2020 **Published:** 26-03-2020

This is an open access journal, and articles are distributed under the terms of the Creative Commons Attribution-NonCommercial-ShareAlike 4.0 License, which allows others to remix, tweak, and build upon the work non-commercially, as long as appropriate credit is given and the new creations are licensed under the identical terms.

For reprints contact: reprints@medknow.com

How to cite this article: Elarabi AS, Saad ZA, Saadawi WK, Aldobea NM, Sagher FA. A rare encounter in nonsuspecting circumstances: First congenital visceral leishmaniasis (kala-azar) in Libya. *Ibnosina J Med Biomed Sci* 2020;12:44-8.

Access this article online

Quick Response Code:



Website:
www.ijmbs.org

DOI:
10.4103/ijmbs.ijmbs_9_20

Congenital transmission may occur either through blood exchange from the mother to the child during delivery or by transplacental infection during pregnancy.^[1] We report the first Libyan case of congenital transmission of VL from an asymptomatic mother representing a rare encounter in nonsuspecting circumstances.

CASE REPORT

Case history

A 4-month-old Libyan male infant referred to pediatric gastroenterology and hepatology clinic in Tripoli University Hospital for prolonged jaundice and hepatosplenomegaly. He is a product of nonconsanguineous parents born by uneventful vaginal at term with a birth weight of 2 kg. He received the birth dose of vaccination and was fed by a mixture of breast and bottle feeding. His yellowish discoloration of skin and sclera was noticed by the parents at the age of 45 days, followed by abdominal distension not associated with fever or weight loss. The mother has three healthy children. However, 3 years previously, she lost one boy who died at the age of 3 months with a similar complaint. Furthermore, she had a twin intrauterine fetal death at 6 months of gestation immediately before the index case. The family lives in Ubari, a town in the far southwestern part of Libya. They live in an impoverished socioeconomic state, with a history of traditional remedies, and they reported no history of distant travel.

Physical examination

PO examination, the baby looked pale and icteric, with palmer erythema, and had generalized lymph-adenopathy and mouth thrash. No specific dysmorphic features were noted. His weight was 4.25 kg (i.e., <3rd centile), length was 58 cm (on the 3rd centile), and occipitofrontal head circumference was 37 cm (<3rd centile). Cardiorespiratory and central nervous systems were normal. The abdomen was distended, with visibly dilated veins and palpable liver (right lobe 9 cm and left lobe 4 cm below the costal margin). The liver was firm in consistency with sharp edge. The spleen was massively enlarged down to the left iliac fossa. No ascites was evident. He had a normal external male genitalia with severe napkin rash.

Investigations

Hematological and biochemical investigations revealed leukocytosis with neutrophilia and cholestasis, conjugated hyperbilirubinemia, and hepatocellular damage [Table 1]. Abdominal ultrasound scan showed hepatosplenomegaly obliterated fibrotic biliary radicals with bilateral medullary sponge kidneys and no ascites. Bone marrow aspiration was reported normal with no evidence of blast cells, or *L. donovani* antibodies, or histiocytes, or lipid foamy cells. Bone marrow biopsy revealed erythroid hyperplasia along with intermingling macrophages showing vacuolated and granular dots like, making the possibility of leishmaniasis high on the list [Figure 1]. DNA was extracted from the bone marrow using QIAamp Tissue Kit (Qiagen, Hilden, Germany) and screened for internal transcribed spacer 1 region of the rRNA genes in *Leishmania spp.* by polymerase chain reaction (PCR) using the primer pair LITSR (5-CTG GAT CAT TTT CCG ATG-3) and

Table 1: Laboratory investigations of the patient

Investigations	Results
WBC ($\times 10^3/\mu\text{L}$)	33.8
DLC	
Neutrophil (%)	27.1
Lymphocyte (%)	67.1
Eosinophil (%)	0.8
Basophil (%)	0.6
Hemoglobin (b/dl)	13.1
Reticulocyte count (%)	7
Platelet count ($\times 10^3/\mu\text{L}$)	158
Total IgE (IU/ml)	92
Total bilirubin (mg/dl)	17.6
Direct bilirubin (mg/dl)	12.4
ALT (IU/l)	113.2
AST (IU/l)	418.1
GGT (IU/l)	178
ALP (IU/l)	646
PT (s)	16.6
PTT (s)	75
INR	1.5
Cytomegalovirus IgM	Positive
Gamma globulin (g/dl)	1.2
Alpha-fetoprotein (pg/dl)	>1000
Total cholesterol (mg/dl)	84
Triglyceride (mg/dl)	187

WBC: White blood cell, DLC: Differential leukocyte count, ALT: Alanine aminotransferase, AST: Aspartate aminotransferase, GGT: Gamma-glutamyltransferase, ALP: Alkaline phosphatase, PT: Prothrombin time, PTT: Partial thromboplastin time, INR: International normalized ratio

L5.8S (5-TGA TAC CAC TTA TCG CAC TT-3). The PCR products were visualized using ultraviolet transillumination with GelRed™ dye (GIBCO BRL Life Technologies, Inc., Gaithersburg, MD, USA) on 1.55 agarose gel (SIGMA, St. Louis) in 1X TAE buffer for 45 min at 100 V after electrophoresis; the size of the amplified product was determined by comparison with a 100 bp ladder (Sigma-Aldrich, USA).^[2] The results were positive for *Leishmania infantum* [Figure 2].

Assessment of the mother

The mother is a 24-year-old native Libyan. She was healthy with no specific complaint or previous hospital admissions. Basic investigations including complete blood count, kidney and liver function tests, and abdominal ultrasound scan were all normal. Further investigations by serological test for *L. infantum* (ELISA IgG, DRG Diagnostics, Marburg-Germany) were positive, and her peripheral blood film showed a full field of *Leishmania* amastigote as shown in Figure 3.

Management and outcome

For the infant, antibiotic therapy (ceftriaxone) plus supportive therapy (fresh frozen plasma and fat-soluble vitamins) was started with no clinical improvement. Later, specific therapy with pentavalent antimonial sodium stibogluconate (pentostam) 20 mg/kg body weight was given immediately after bone marrow biopsy was taken. Unfortunately, the patient died after finishing the seventh dose of therapy. The mother received pentavalent antimonial therapy with sodium stibogluconate (pentostam) for 1 month. The mother was lost for follow-up after starting the therapy.

DISCUSSION

Kala azar was first described in Greece in 1835 and several decades later in India 1882.^[3] In Libya, VL is due to *L. infantum*. It occurs in two endemic areas, in the northeastern region precisely Al Jabel Al Akhdar, and in the southern region in Ubari where our infant and mother come from. Domestic dogs (*Canis familiaris*) are the primary reservoir hosts in the Mediterranean Basin. The Libya National Center for Disease Control (NCDC) reported five deaths out of 31 confirmed cases between 2013 and 2017.^[4,5]

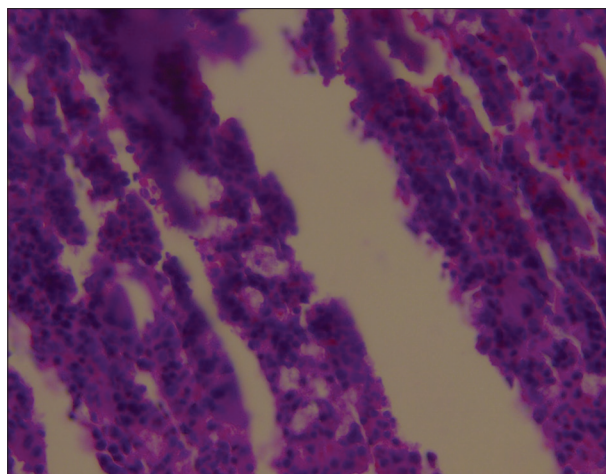


Figure 1: Bone marrow biopsy showing erythroid hyperplasia along with intermingling macrophages, vacuolated and granular dots like, making the possibility of leishmaniasis high on the list

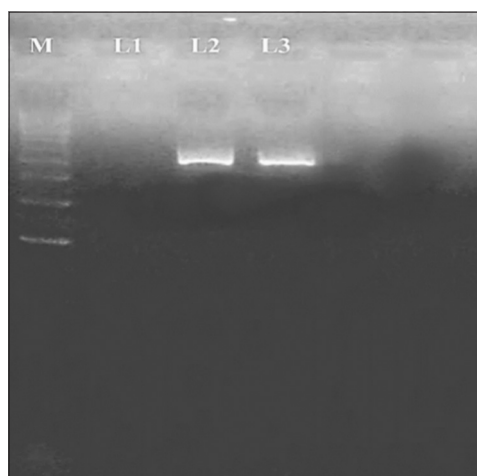


Figure 2: Gel images of representative polymerase chain reaction amplification of *Leishmania* DNA. Amplifications of the internal transcribed spacer 1 gene shown in lanes 3, M is 100 bp molecular marker, lane 1 is negative control, and lane 2 is a positive control

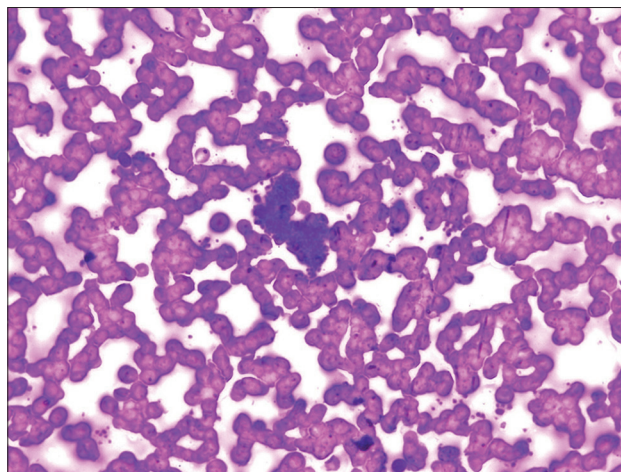


Figure 3: Peripheral blood film of the mother stained with Giemsa stain showing *Leishmania* amastigotes

Although most of the congenital VL (CVL) observed after the mother had symptomatic VL during pregnancy, two reported cases in Germany were congenitally infected from asymptomatic mothers. The first case was a 16-month-old boy reported by Meinecke *et al.*^[6] and the other one was a 9-month-old German girl who had never been to a VL-endemic area as reported by Boehme *et al.*^[7] In both cases, the mothers had never been symptomatic for VL, but laboratory investigations confirmed the infection. The present case is the first reported case of CVL in Libya and third reported case of congenitally transmitted visceral *Leishmania* from an asymptomatic mother in the world, as she was a young, healthy female and had never been symptomatic for *Leishmania* infection. She had no history of traveling outside Libya. However, she lives in an endemic area for VL, had a history of twin intrauterine fetal death at 6-month gestation before this pregnancy, in addition to the history of her son who presented with a similar history but died 3 years ago, all suggesting the congenital route of infection.

The diagnosis of *Leishmania* should be confirmed by either the microscopic identification of the amastigote or promastigote forms of the parasite in liver, spleen, or bone marrow biopsies or by the detection of the desoxyribonucleic acid of *Leishmania* in blood or biopsy material using PCR.^[7] In the present case, the diagnosis was undoubtedly confirmed by bone marrow PCR for the infant and direct visualization of amastigote in peripheral blood film of the mother.

The main drugs available for the treatment of VL are the systemic agents such as pentavalent antimonials (sodium stibogluconate [SSG] and meglumine antimoniate, amphotericin B, and liposomal amphotericin B (L-AmB), and the oral drug miltefosine.^[8] Liposomal amphotericin B (LAB) has better tissue penetration effect and is more effective at lower doses, reducing toxicities.^[8] Hence, it is strongly recommended as the first-choice drug in pregnancy due to its fewer materno–fetal adverse effects.^[9] There are no incidents of vertical transmission of the disease or any repercussion on the fetus reported following the use of L-AmB. Successful results for both mother and fetus with

liposomal amphotericin-B were reported in 2017 by P Periklis in Greece,^[10] in a symptomatic mother treated for VL 2 months before delivery. A single dose of liposomal amphotericin B (L-AmB) and multidrug therapy (L-AmB + miltefosine, L-AmB + paromomycin (PM), or miltefosine + PM) is the treatment of choice for VL in the Indian subcontinent. The combination of SSG with PM for 17 days is used as the treatment of choice in East Africa and Yemen, whereas L-AmBup at a total dose of 18–21 mg/kg remains the choice in Mediterranean Basin, Middle East, and Central Asia. Recently, miltefosine (hexadecylphosphocholine) is effective orally against kala azar. All clinical trials with this drug were conducted in India in VL patients. A regimen of 100 mg per day or 50 mg twice daily for 3–4 weeks was reported to achieve a cure rate of 100%. Gastrointestinal side effects were frequent (62%), but no patient discontinued the therapy.^[11]

CONCLUSIONS

The diagnosis of VL should be considered in children with fever and splenomegaly with or without pancytopenia. This should be the case despite the lack of the child's travel to an endemic area and lack of absence of evidence of the disease in the immediate environment. Albeit rare, leishmaniasis can be transmitted congenitally from an asymptomatic mother to her child. Late diagnosis as reported here is associated with poor outcome. Bad obstetric history of the mother could be related to her undiagnosed kala azar.

Declaration of patient consent

The authors certify that they have obtained all appropriate patient consent forms. In the form, the patient has given her consent for the history and radiological and pathological images and other clinical information to be reported in the journal. She understands that name and initial will not be published and due efforts will be made to conceal identity, but anonymity cannot be guaranteed.

Acknowledgment

The authors would like to express their cordial thanks and gratitude to Dr. Ahmed Elgrari, Director of Zoonotic Disease Control Administrative at

NCDC, and to Professor Bader Eddin B Annajar, Director General, NCDC, and all the staff of the Reference Laboratory of Parasitology and Vector borne Disease for their help in the management of this case.

Authors' contributions

All authors contributed to the assessment, investigations, and/or provision of the ancillary investigations. All authors were involved in the drafting, revision, and approval of the final version.

Financial support and sponsorship

Nil.

Conflicts of interest

There are no conflicts of interest.

Compliance with ethical principles

No prior formal ethical approval is required for individual case reports or anonymized small series. However, a consent was obtained from the mother for reporting of her case anonymously.

REFERENCES

1. Karimi A, Alborzi A, Amanati A. Visceral leishmaniasis: An update and literature review. *Arch Pediatr Infect Dis* 2016;4:e31612.
2. Dabirzadeh M, Hashemi M, Maroufi Y. Study of genetic variation of leishmania major based on internal transcribe spacer 1 (ITS1) in Chabahar, Iran. *Jundishapur J Microbiol* 2016;9:e33498.
3. Alencar JE, Neves J, Dietze R. Leishmaniose visceral (calazar). In: Veronesi R, Focaccia R, Dietze R, editors. *Tratado De Infectologia*. 9th ed. *Tratado de Infectologia*. Sa˜o Paulo: Atheneu; 1997.
4. Annajar B. Collaborative Research Opportunities in North Africa and the Middle East Conference. *Research Abstract*; 22-25 June, 2009.
5. Elhosk MA, Shaibi T, Annajar BB, Scalini A, Maroli M. A preliminary investigation on *Phlebotomus Longicuspis Nitzulescu* the suspected vector of visceral leishmaniasis in the North Eastern region of Libya. *Int J Adv Res* 2014;2:411.
6. Meinecke CK, Schottelius J, Oskam L, Fleischer B. Congenital transmission of visceral leishmaniasis (Kala Azar) from an asymptomatic mother to her child. *Pediatrics* 1999;104:e65.
7. Boehme CC, Hain U, Novosel A, Eichenlaub S, Fleischmann E, Löscher T. Congenital visceral leishmaniasis. *Emerg Infect Dis* 2006;12:359-60.
8. Sundar S, Chakravarty J. An update on pharmacotherapy for leishmaniasis. *Expert Opin Pharmacother* 2015;16:237-52.
9. Figueiro-Filho EA, Duarte G, El-Beitune P, Quintana SM, Maia TL. Visceral leishmaniasis (kala-azar) and pregnancy. *Infect Dis Obstet Gynecol* 2004;12:31-40.
10. Panagopoulos P, Mitsopoulos V, Papadopoulos A, Theodorou S, Christodoulaki C, Aloupogiannis K, *et al.* Visceral leishmaniasis during pregnancy: A rare case report from Greece. *PLoS Negl Trop Dis* 2017;11:e0005134.
11. Sangraula H, Sharma KK, Rijal S, Dwivedi S, Koirala S. Orally effective drugs for kala-azar (visceral leishmaniasis): Focus on miltefosine and sitamaquine. *J Assoc Physicians India* 2003;51:686-90.

Reviewers:

Ashraf Elghul (Abu Dhabi, UAE)
 Ahmed El-Kased (Menofya, Egypt)
 Ahmed Elhassi (Benghazi, Libya)
 Eman Abdelzaher (Alexandria, Egypt)

Editors:

Elhadi H Abu Rawi (Al Ain, UAE)
 Salem A Beshyah (Abu Dhabi, UAE)