

A Case of Mature Cystic Teratoma in an 8-year-old Girl: A Rare Case Report

Abstract

Ovarian tumors are commonly seen in reproductive age group in women. However, when they occur at extremes of age, the suspicion of malignancy increases. The detection of dermoid cyst at 8 years of age is uncommon and hence is being reported to acquaint the doctors of this possibility. Awareness of benign tumors in small children can help in proper counseling of patient party and planning the surgical procedure.

Keywords: Age, malignancy, mature cystic teratoma

**Manika Agarwal,
Shweta Mishra**

Department of Obstetrics and Gynaecology, North-Eastern Indira Gandhi Regional Institute of Health and Medical Sciences, Shillong, Meghalaya, India

Introduction

Mature cystic teratoma is the most frequent neoplastic tumor of children and adolescents, accounting for more than one-half of ovarian neoplasm in women younger than 20 years of age.^[1] We are presenting this case because on search of literature, we could not find a case of mature cystic teratoma in such a young child, except for one case of 20-month-old infant who had a complaint of urinary retention.

Case Report

An 8-year-old girl presented with a complaint of dull aching pain in abdomen for 3–4 weeks. On examination, the vitals were stable; secondary sexual characteristics were not well developed. On abdominal examination, a well-defined lump, smooth and mobile, was felt corresponding to 16–18 weeks of gestation. The lump was firm in consistency and was very mobile. Ultrasonography shows a cystic mass of size 9.30 cm × 5.87 cm in the pelvic region (? ovarian). Serum tumor markers done. Alkaline phosphatase was 263 U/L (raised), lactate dehydrogenase was 221 U/L, alpha-fetoprotein was 1.90 ng/mL, and total beta human chorionic gonadotrophin-2 was 0.68 mIU/mL.

The patient was taken for laparotomy. On opening the abdomen, the uterus was very small in size, right ovary was normal, and a

left ovarian cyst 8 cm in size with smooth surface [Figure 1] was found. An ovarian cyst in an 8-year-old girl may also have some malignant potential, so ovariectomy was done. The patient stood the procedure well. Histopathological examination of the specimen revealed uniloculated cyst with one tiny solid area. Wall thickness was 0.2 cm. The solid area showed tuft of hair and pultaceous material. Features were suggestive of mature cystic teratoma.

Discussion

In a study on 283 cases of mature cystic teratoma in National Taiwan University Hospital, Wu *et al.* found the youngest patient to be 12 years old and the oldest to be 76 years. The largest number of patient was found in the age of 20 and 30 years, and the mean age was 35.4.^[2] A case of urinary retention due to ovarian dermoid cyst in a 20-month-old infant girl has been reported by Matsumoto *et al.*^[3] The infant had a chief complaint of voiding difficulty and micturition pain. Excretory urogram, ultrasound, and computed tomography scan revealed a retrovesical mass which compressed the urinary bladder anterosuperiorly. On operation, they found that the tumor originated from the right ovary and was 6.2 cm × 5.0 cm × 5.0 cm in size, and the pathological diagnosis of the mass was ovarian dermoid cyst. The oldest patient reported to have a dermoid cyst is an 89-year-old woman. She had an adenosquamous carcinoma arising in a dermoid cyst.^[4]

Address for correspondence:

Dr. Shweta Mishra,
K-293-B, Ashiana,
Lucknow - 226 012,
Uttar Pradesh, India.
E-mail: dr.mishra.shweta@gmail.com

Access this article online

Website: www.ijmpo.org

DOI: 10.4103/ijmpo.ijmpo_109_16

Quick Response Code:



How to cite this article: Agarwal M, Mishra S. A case of mature cystic teratoma in an 8-year-old girl: A rare case report. Indian J Med Paediatr Oncol 2017;38:210-1.

This is an open access article distributed under the terms of the Creative Commons Attribution-NonCommercial-ShareAlike 3.0 License, which allows others to remix, tweak, and build upon the work non-commercially, as long as the author is credited and the new creations are licensed under the identical terms.

For reprints contact: reprints@medknow.com

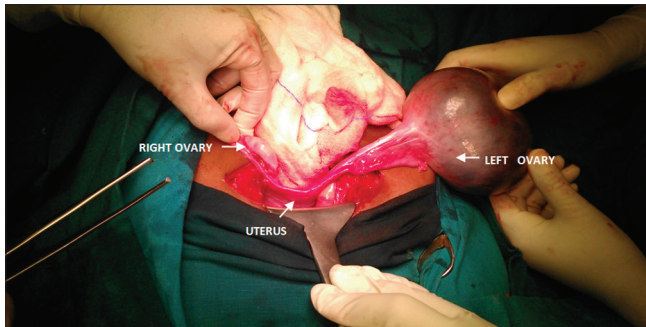


Figure 1: Mature cystic teratoma of left ovary in an 8-year-old girl

Conclusion

Mature cystic teratoma is generally seen in reproductive age group; however, rare cases may occur in prepuberty age group to women in postmenopausal age group. Although the rate of malignant transformation is only 1% in patients with mature cystic teratoma, this may be more commonly seen in those patients with extremes of age.

Financial support and sponsorship

Nil.

Conflicts of interest

There is no conflicts of interest.

References

1. Hillard PJ. Benign disease of female reproductive tract. In: Berek JS, editor. Berek and Novak's Gynaecology. 15th ed. Wolter's Kluwer, United Kingdom: Lippincott William & Wilkins; 2012. p. 398.
2. Wu RT, Torng PL, Chang DY, Chen CK, Chen RJ, Lin MC, *et al*. Mature cystic teratoma of the ovary: A clinicopathologic study of 283 cases. *Zhonghua Yi Xue Za Zhi (Taipei)* 1996;58:269-74.
3. Matsumoto M, Watanabe T, Uekado Y, Ohkawa T. A case of urinary retention due to ovarian dermoid cyst in a female infant. *Hinyokika Kyo* 1993;39:85-7.
4. Irie J, Kawai K, Kumagai K, Tsuchiyama H, Asano M. Adenosquamous carcinoma arising in a dermoid cyst (Benign cystic teratoma) of the ovary – A case report. *Gan No Rinsho* 1984;30:1840-4.