

A Report of a Rare Case of Hurthle Cell Carcinoma of Thyroid with Metachronous Renal Metastasis

Abstract

Renal metastasis from Hurthle cell thyroid carcinoma is an extremely rare phenomenon which when present usually indicates widely disseminated disease. Herein, we present a case of Hurthle cell carcinoma of thyroid in a 58-year-old gentle lady, with metachronous renal metastasis which happens to be the fourth reported case in English literature.

Keywords: Follicular carcinoma, Hurthle cell, renal metastasis, thyroid malignancies

Introduction

Hurthle cell carcinoma is a rare variant of follicular carcinoma of thyroid, accounting for about 3% of all thyroid malignancies.^[1] These tumors tend to recur locoregionally, and distant metastases are rather uncommon.^[2] However, distant failure represents the most frequent cause of thyroid cancer-related death in these patients. The most common sites of metastases encountered are lungs and bones.^[3] Renal metastasis is extremely rare. Herein, we present a case of Hurthle cell carcinoma of thyroid with metachronous renal metastasis. Extensive literature search suggests it to be the fourth reported case.^[2,4,5]

Case Report

An otherwise well, 58-year-old lady presented with swelling in the right side of the neck for 3 years in December 2014 which was rapidly progressing for the past 3 months. Contrast-enhanced computed tomography (CECT) scan of the neck, thorax, and abdomen revealed a large heterogeneous mass in the right lobe of thyroid with no evidence of distant metastasis. Fine-needle aspiration cytology from swelling showed predominantly Hurthle cells. She underwent total thyroidectomy in January 2015. Histopathologic examination of postoperative specimen showed features of

Hurthle cell carcinoma [Figure 1]. Tumor was seen involving capsule, surrounding soft tissue, skeletal muscle, and skin. Six lymph nodes (two each from paratracheal, Level III, and central lymph nodes) were dissected which were all involved by tumor. She was started on levothyroxine and underwent Iodine-131 whole-body scan, 6-week postsurgery, which showed thyroid remnant, left cervical Level VI lymph node, and bilateral pulmonary nodules. Hence, she was administered 150 mCi radioiodine (RAI) therapy thrice at 6-month intervals till April 2016. Post-third session therapy and Iodine-131 whole-body scan showed faint uptake in the right neck node. In December 2016, she developed a right cervical swelling in the neck, and on Iodine-131 whole-body scan, there was no uptake. CECT scan of the neck, thorax, and abdomen was done which showed multiple right cervical lymph nodes at Level II, III, IV and supraclavicular region, bilateral pulmonary nodules, and lytic destruction of left transverse process of D8 vertebra [Figure 2]. A large exophytic lesion (40 mm × 29 mm) was seen arising from the posterior interpolar region of the right kidney suggestive of renal metastasis [Figure 3]. Thyroglobulin was measured 2625 ng/ml. She was administered palliative radiotherapy of 20 gray (Gy) in five fractions over 1 week to the neck and 8 Gy in single fraction to D7–D9 vertebrae. Subsequently, she was started on oral sorafenib in view of progressive disease.

This is an open access journal, and articles are distributed under the terms of the Creative Commons Attribution-NonCommercial-ShareAlike 4.0 License, which allows others to remix, tweak, and build upon the work non-commercially, as long as appropriate credit is given and the new creations are licensed under the identical terms.

For reprints contact: WKHLRPMedknow_reprints@wolterskluwer.com

How to cite this article: Kumar R, Biswas R, Mathur S, Bhasker S, Damle N, Bal CS, *et al.* A report of a rare case of Hurthle cell carcinoma of thyroid with metachronous renal metastasis. *Indian J Med Paediatr Oncol* 2020;41:409-11.

Ritesh Kumar¹,
Rituparna Biswas¹,
Sandeep Mathur²,
Suman Bhasker¹,
Nishikant Damle³,
CS Bal³,
Ekta Dhamija⁴

¹Department of Radiation Oncology, Dr. B.R.A. IRCH, All India Institute of Medical Sciences, New Delhi, India,

²Department of Pathology, All India Institute of Medical Sciences, New Delhi, India,

³Department of Nuclear Medicine, All India Institute of Medical Sciences,

New Delhi, India, ⁴Department of Radiology, Dr. B.R.A. IRCH, All India Institute of Medical Sciences, New Delhi, India

Submitted: 06-Jul-2018

Accepted in Revised Form: 12-Sep-2018

Published: 27-Jun-2020

Address for correspondence:

Dr. Rituparna Biswas,
Department of Radiation Oncology, Dr. B.R.A. IRCH, All India Institute of Medical Sciences, New Delhi, India.
E-mail: mail4r_biswas@yahoo.co.in

Access this article online

Website: www.ijmpo.org

DOI: 10.4103/ijmpo.ijmpo_147_18

Quick Response Code:



Table 1: Previous published reports of Hurthle cell carcinoma of thyroid with renal metastases

Authors	Age (years)	Sex	Renal metastasis diagnosed by	Treatment received
Djekidel <i>et al.</i> ^[2]	75	Male	FDG positron emission tomography-CT scan, magnetic resonance imaging	Thyroidectomy, RAI therapy, radical nephrectomy, and palliative radiotherapy to vertebral metastasis
Claimon <i>et al.</i> ^[4]	62	Female	SPECT/CT imaging	Thyroidectomy and RAI therapy
Kushchayeva <i>et al.</i> ^[6]	70	Unknown	Unknown	Thyroidectomy, RAI therapy, and radical nephrectomy

CT – Computed tomography; RAI – Radioiodine; SPECT – Single-photon emission computed tomography; FDG – Fluoro-deoxyglucose

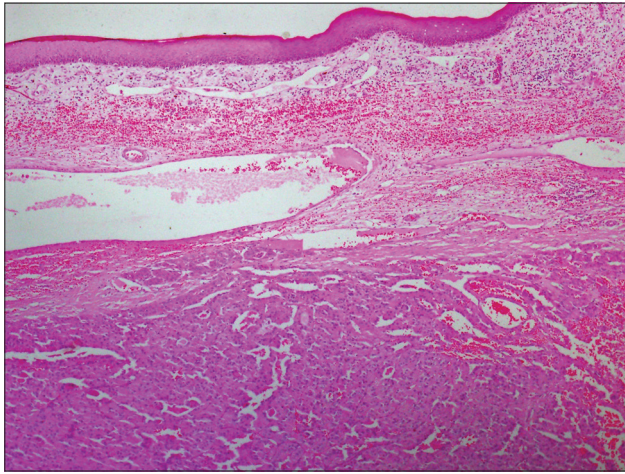


Figure 1: Histopathologic examination showing features of Hurthle cell carcinoma

Discussion

According to the World Health Organization classification, Hurthle cell thyroid carcinoma (HCTC) is considered to be an oxyphilic variant of follicular thyroid carcinoma (FTC).^[6] Although earlier studies reported inferior survival of these patients with HCTC,^[7] a recent study by Bhattacharyya^[1] showed similar outcome as compared with patients of FTC. However, it has been seen that HCTC is associated with higher rates of metastases compared to other subtypes. Lung and bone are the most common sites of distant metastases.^[3] Renal metastasis is a rare occurrence. Exhaustive search of English literature revealed that our presented case is the fourth case reported [Table 1]. In general, metastatic kidney lesion should ideally be proven by biopsy, but the diagnosis by imaging may also be acceptable in cases where the lesion is too small to be biopsied or biopsy is not possible due to medical comorbidities.^[4] In the index case, biopsy from the renal lesion was not done in view of strong clinicoradiological correlation. Treatment of metastatic HCTC is not well defined owing to its low incidence and hence fewer extensive experience. The management of distant metastases includes levothyroxine replacement, focal therapy, and systemic treatment (including RAI), and in patients with RAI-refractory disease, it includes the use of kinase inhibitors. Focal treatment is indicated in local tumor palliation and orthopedic or neurologic sequelae, for example, external beam radiotherapy (EBRT) for palliation of the bone and brain metastasis or surgical

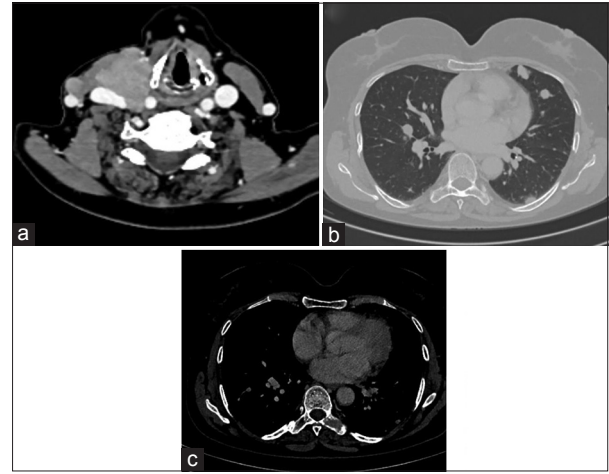


Figure 2: Contrast-enhanced computed tomography scan showing right cervical lymph nodes (a), bilateral pulmonary nodules (b), and lytic destruction of left transverse process of D8 vertebra (c)

fixation for fractures. RAI ablation is difficult in HCTC as most of them do not uptake RAI, and some of the tumors which show faint uptake is probably due to the follicular component.^[3] Chemotherapy is usually not effective.^[8] Among kinase inhibitors, sorafenib is approved by the US Food and Drug Administration for advanced differentiated thyroid cancer.^[9] Similarly, our patient was managed by sorafenib and local EBRT to the neck and D8 vertebrae.

Conclusion

Renal metastasis from HCTC is a rare occurrence which tends to be overlooked and usually occurs in the setting of extensive multiple organ metastases.

Declaration of patient consent

The authors certify that they have obtained all appropriate patient consent forms. In the form the patient(s) has/have given his/her/their consent for his/her/their images and other clinical information to be reported in the journal. The patients understand that their names and initials will not be published and due efforts will be made to conceal their identity, but anonymity cannot be guaranteed.

Financial support and sponsorship

Nil.

Conflicts of interest

There are no conflicts of interest.

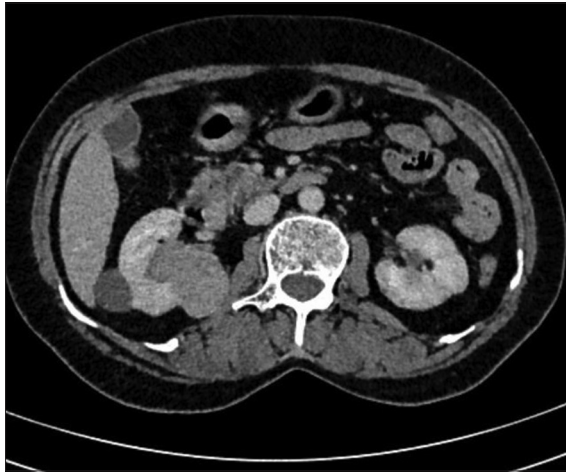


Figure 3: Contrast-enhanced computed tomography scan showing right renal metastasis

References

1. Bhattacharyya N. Survival and prognosis in Hürthle cell carcinoma of the thyroid gland. *Arch Otolaryngol Head Neck Surg* 2003;129:207-10.
2. Djekidel M, Gordon M, Shah RB, Gross MD, Avram A. Renal metastasis from Hurthle cell thyroid carcinoma and its evaluation with hybrid imaging. *Thyroid* 2010;20:429-33.
3. Zhang H, Zeng L, Liang C, Qiu H, Zhang M, Zhu Y, *et al.* Successful treatment of Hurthle cell thyroid carcinoma with lung and liver metastasis using docetaxel and cisplatin. *Jpn J Clin Oncol* 2012;42:1086-90.
4. Claimon A, Suh M, Cheon GJ, Lee DS, Kim EE, Chung JK, *et al.* Bilateral renal metastasis of Hürthle cell thyroid cancer with discordant uptake between I-131 sodium iodide and F-18 FDG. *Nucl Med Mol Imaging* 2017;51:256-60.
5. Besic N, Schwarzbartl-Pevce A, Vidregar-Kralj B, Crnic T, Gazic B, Marolt Music M, *et al.* Treatment and outcome of 32 patients with distant metastases of Hürthle cell thyroid carcinoma: A single-institution experience. *BMC Cancer* 2016;16:162.
6. Kushchayeva Y, Duh QY, Kebebew E, Clark OH. Prognostic indications for Hürthle cell cancer. *World J Surg* 2004;28:1266-70.
7. Watson RG, Brennan MD, Goellner JR, van Heerden JA, McConahey WM, Taylor WF, *et al.* Invasive Hürthle cell carcinoma of the thyroid: Natural history and management. *Mayo Clin Proc* 1984;59:851-5.
8. Lopez-Penabad L, Chiu AC, Hoff AO, Schultz P, Gaztambide S, Ordoñez NG, *et al.* Prognostic factors in patients with Hürthle cell neoplasms of the thyroid. *Cancer* 2003;97:1186-94.
9. Haugen BR, Sherman SI. Evolving approaches to patients with advanced differentiated thyroid cancer. *Endocr Rev* 2013;34:439-55.