

Modulated Radiotherapy with Concurrent and Adjuvant Temozolomide for Anaplastic Gliomas: Indian Single-center Data

Abstract

Objective: To evaluate early clinical outcome for anaplastic gliomas (AG) treated in the era of modulated radiotherapy (RT) and concurrent plus adjuvant temozolomide (TMZ) in an Indian setting. **Materials and Methods:** Fifty-three patients with AGs treated with modulated RT and concurrent (95%) and adjuvant TMZ (90%) were analyzed. About 80% of patients had Karnofsky performance status (KPS) at least 90 with 30% seizure at presentation. Postoperative magnetic resonance imaging was available in 65% cases and RT dose was 60 Gy in 30 fractions. First posttreatment imaging was performed at 1 month and then at 3 and 6 months post-RT and then every 3 months. Kaplan–Meier analysis was used to estimate disease-free survival (DFS) and overall survival (OS), and analysis was done using SPSS version 18.0. **Results:** With median follow-up of 25 months, 2-year DFS and OS were 75% and 88%. There were only 5% symptomatic central nerves system and 8% symptomatic hematological toxicities. At the 1st evaluation, 30.4% had complete response (CR), at 3 months 40%, and at 6 months 43%. At 6 months, only 4% had progressive disease. Forty-six patients were evaluable till the last follow-up with and 55% had stable to CR. On univariate analysis for DFS, KPS at presentation >90 ($P = 0.001$) and response at 6 months ($P = 0.02$) were significant and for OS KPS at presentation ($P = 0.004$) alone. **Conclusion:** Modulated RT with TMZ among Grade III glioma patients resulted in minimum treatment-related toxicities and encouraging survival. Molecular prognostic markers will determine most favorable groups in future.

Keywords: Anaplastic glioma, modulated radiotherapy, survival, temozolomide

Tejinder Kataria,
Trinanjan Basu,
Deepak Gupta,
Shikha Goyal,
Shahida Nasreen,
Shyam S Bisht,
Ashu Abhishek,
Susovan Banerjee,
Kushal Narang,
Ajaya N Jha¹,
Ishani Mohapatra²,
Jayesh A Modi³

Division of Radiation Oncology,
¹Division of Neurosurgery,
²Departments of Pathology
and ³Radiology and Imaging,
Medanta The Medicity,
Gurgaon, Haryana, India

Introduction

The primary brain tumors comprise 2% of all cancers.^[1] As per the World Health Organization classification, anaplastic gliomas (AGs) are Grade III malignant tumors and are managed on the line of glioblastoma multiforme (GBM) with maximal safe resection (MSR) followed by adjuvant radiotherapy (RT). Adjuvant RT has demonstrated improved survival both in terms of local control and overall survival (OS).^[2-5] Following the trend in management of GBM with RT with concurrent and adjuvant temozolomide (TMZ), the protocol has been adopted gradually to manage anaplastic Grade III gliomas.^[6,7] Till date, there are no prospective randomized data to validate the role of RT and TMZ for Grade III gliomas although retrospective single-center experiences have been encouraging.

Outside clinical trials, anaplastic astrocytomas (AA) are treated as GBM with RT and TMZ. AA lack 1p19q

co-deletion is considered to be as high risk as GBM. On the other hand, anaplastic oligodendrogliomas (AODG) that express 1p19q co-deletion can be managed with adjuvant procarbazine, carmustine, and vincristine (PCV) chemotherapy.^[8,9] TMZ has been favored keeping in mind the favorable toxicity profile and tolerability. Although there is no differential activity between the two, TMZ has been preferred due to reduced toxicity, tolerability, and ease of administration.^[10-12]

We evaluated our cohort of AG patients (AA, AODG, and anaplastic oligoastrocytoma [AOA]) treated uniformly with MSR followed by adjuvant RT plus concurrent TMZ and adjuvant TMZ. The survival outcomes and prognostic factors were assessed.

Materials and Methods

Between November 2011 and November 2014 consecutively treated 71 AG patients, data were evaluated. The uniform

Address for correspondence:

Dr. Trinanjan Basu,
Division of Radiation Oncology,
Medanta The Medicity,
Gurgaon, Haryana, India.
E-mail: trinanjan.doctor@gmail.com

This is an open access article distributed under the terms of the Creative Commons Attribution-NonCommercial-ShareAlike 3.0 License, which allows others to remix, tweak, and build upon the work non-commercially, as long as the author is credited and the new creations are licensed under the identical terms.

For reprints contact: reprints@medknow.com

How to cite this article: Kataria T, Basu T, Gupta D, Goyal S, Nasreen S, Bisht SS, *et al.* Modulated radiotherapy with concurrent and adjuvant temozolomide for anaplastic gliomas: Indian single-center data. *Indian J Med Paediatr Oncol* 2017;38:495-501.

Access this article online

Website: www.ijmpo.org

DOI: 10.4103/ijmpo.ijmpo_200_16

Quick Response Code:



criteria of MSR (gross-total resection [GTR] or near-total resection [NTR] or stereotactic [STS] biopsy) followed by adjuvant RT plus TMZ and adjuvant TMZ was applied, and at least 1 year of follow-up, posttreatment was also considered before analysis. Finally, 53 patients were analyzed after careful evaluation of clinical follow-up data from these network systems. The treatment protocol was the consensus decision of institutional neuro-oncology tumor board comprising of neurosurgeons, radiation oncologists, pathologists, and neuroradiologists and medical oncologists. Informed consent was taken for all patients before initiation of treatment.

Surgical characteristics

GTR was defined as no residual enhancement on postoperative magnetic resonance imaging (MRI) scans. NTR/near-total excision was defined as having thin rim of enhancement in resection cavity only. Subtotal resection was as having residual nodular enhancement. Few patients also had STS biopsy alone in view of location of the tumor and medical decompression. Whatever may be the surgery, postoperative biopsy report other than grade of tumor and molecular markers such as 1p19q co-deletion status was also ordered.

Radiotherapy protocol

Postoperative RT was carried out 1 week after stich removal, and in majority, the commencement was between 3 and 4 weeks after surgery. A postoperative contrast-enhanced MRI (CEMRI) scan of the brain was taken before RT planning. All patients were immobilized with thermoplastic head mask, and a 3-mm slice-thickness computed tomography (CT) scan was acquired from vertex to mid neck in supine position. If there were no contraindications, all patients had IV contrast injection while RT planning CT scan was done. The CT images were then transferred through DICOM to Focal Sim planning software (Elekta Crawley, UK) system. Planning CT was fused with MRI and target delineation was done according to Radiotherapy Oncology Group (RTOG) and European Society for Therapeutic Radiation Oncology- Advisory Committee on Radiation Oncology Practice guideline. A neuroradiologist was also called to verify the volumes. Gross tumor volume (GTV) included postoperative cavity, residual disease, and edema based on both T1 postcontrast and T2FLAIR sequences of MRI. Clinical target volume (CTV) was created by giving a 2-cm margin to GTV and then edited from natural barriers, and planning target volume was created by giving 0.5 mm margin to CTV as a standard departmental protocol. Besides target volumes, organs at risk including bilateral eyes, optic nerves, lenses, optic chiasm, brain stem, temporal lobes, normal brain, and hippocampus were delineated as per standard guideline.

RT technique was modulated radiation (either intensity-modulated radiotherapy [IMRT] or volumetric

modulated arc therapy [VMAT]). The prescribed total dose was 58–60 Gy in conventional fractionation (at 1.8–2 Gy per fraction), and the patients were treated from Monday through Friday.

Acute and late RT side effects were noted as per RTOG toxicity criterion, and quality of life (QOL) scales EORTC QOL Q C30 and BN 20 were administered at beginning of RT, on completion, and at each follow-up.

Temozolomide and supportive medications

Although edema was more prominent during RT, glucocorticoids were not given prophylactically and were administered if signs and symptoms of increased intracranial pressure were manifested. All patients had antiepileptic drugs with levetiracetam as sodium valproate and phenytoin are hepatic enzyme modulators.

Patients received concurrent TMZ at 75 mg/m² throughout RT period starting from the 1st day and also continued over the weekends till the last day of RT. Along with TMZ prophylactic antiemetics, mostly 5HT₃ inhibitors (granisetron or ondansetron) and proton pump inhibitors (pantoprazole) were given 30 min before receiving TMZ. TMZ was given 30–45 min before RT, and gap of 2 h between food and TMZ was maintained. TMZ was administered by a nurse in the radiation oncology day care so that the patient could be taken for radiation within the stipulated time of action of TMZ as radiosensitizer. Pneumocystis carinii pneumonia prophylaxis was not given routinely. Complete blood counts were done at least weekly (if not twice a week) while on RT. The acceptable blood parameters to continue RT plus TMZ were total leukocyte counts at least 4000/cmm, platelet counts >150,000/cmm, and hemoglobin level more or equals to 10 g/dl. Routine administration of growth factors was not considered, and if platelet counts dropped below 80,000/cmm, RT was stopped.

Follow-up

At completion of RT, TMZ was also stopped. Patients came for the first follow-up at 4 weeks from completion of RT with CEMRI of the brain. Adjuvant TMZ was started after verifying blood counts and MRI report at 150 mg/m² for 5 days in a month and from the 2nd cycle at 200 mg/m² up to 6 cycles at the same dosage if blood counts were adequate, interim MRI brain remained stable, and patient's Karnofsky performance status (KPS) was ≥70. Antiepileptics were continued throughout. CEMRI brain was repeated after three cycles of TMZ and also after completion of six cycles.

OS was calculated from the date of registration till the last follow-up, and disease-free survival (DFS) was calculated from the end of RT and TMZ till the last date of disease control. Radiological progression was validated through neuro-oncology meeting comprising of neurosurgeons, radiation oncologist, and neuroradiologists. Treatment options at progression were salvage surgery, re-RT, and

challenge with low-dose TMZ or bevacizumab. At the time of analysis, patients who were not available for follow-up for more than 6 months were considered lost to follow-up.

Patient and disease characteristics such as age, gender, histopathological type of AG, surgery type and extent, RT dose and TMZ details, post-RT response at completion, 3rd, and 6th months, and other characteristics were considered for OS and DFS calculation. The statistical analysis was done using IBM SPSS version 18.0 (UNICOM system, IBM Corporation, Armonk, New York).

Results

A total of 53 patients were analyzed. Out of the entire cohort, 71.6% were male and 28.4% were female. Median age was 40 years with majority (83%) had KPS \geq 90. The histopathological varieties were equally distributed with AODG (47.2%) being most common. Very few patients could undergo molecular testing for 1p19q due to logistic reasons. The detailed demographics are being represented in Table 1.

Treatment characteristics

Surgery

All the 53 patients were evaluated by neurosurgeon for surgical intervention. Twelve out of 53 patients had STS biopsy only keeping in mind the location of the primary tumor. About 65% of patients had postoperative MRI brain, and for the rest, we used the intraoperative MRI suite (Brain Lab) images for RT planning. Gross-total excision was done in about 50% of cases.

Table 1: Demographic profile of the cohort (n=53)

Characteristics	n (%)
Age	Median: 40 years Range: 13-75 years
Gender	Male: 38 (71.6) Female: 15 (28.3)
KPS	\geq 90: 44 (78.6) 70-80: 7 (12.5) <70: 2 (3.6)
Deficit at presentation	Yes: 9 (16.9) No: 44 (83)
Seizure at presentation	Yes: 20 (37.7) No: 33 (62.2)
Duration of symptoms	Median duration: 30 days
Diagnosis	AA: 18 (34) AODG: 25 (47.2) AOA: 10 (18.9)
1p19q studies	Both positive: 3 (5.6) Either positive: 1 (1.8) Both negative: 9 (16.9) NA: 40 (75.4)

KPS – Karnofsky performance status; AA – Anaplastic astrocytoma; AODG – Anaplastic oligodendroglioma; AOA – Anaplastic oligoastrocytoma; NA – Not available

Radiotherapy

All patients received postoperative RT. The RT technique was IMRT in 56% of cases, and about 40% had VMAT technique. Forty-six out of 53 patients (87%) received RT dose between 5800 and 6000 cGy in 200 cGy per fractions. All the patients received concurrent TMZ with interruption only if acute hematological toxicities. About 60% of patients completed total 6 cycles of adjuvant TMZ. The treatment was mostly well tolerated with Grade I nonspecific central nerves system toxicities and Grade I hematological toxicities (mostly thrombocytopenia). Only four patients had treatment interruption due to thrombocytopenia. The treatment characteristics are presented in Table 2.

Survival

At the first follow-up posttreatment, 30.4% of cases had complete response (CR), at 3 months 40%, and at 6 months 43%. At 6 months, only 10% (6 patients) had progressive disease. About 32% of patients had stable to partial response status at 6 months. Hence, majority of the patients had stable to CR at treatment completion with adjuvant TMZ.

Table 2: Treatment characteristics

Characteristics	n (%)
Surgery	Near-total/gross-total excision: 16 (30.1) Subtotal excision: 25 (47.1) Biopsy alone: 12 (22.6)
Postoperative MRI brain	No residual: 9 (16.9) Residual enhancement: 9 (16.9) Residual disease: 15 (28.3) NA: 20 (37.7)
Radiotherapy technique	VMAT: 21 (39.6) IMRT: 30 (56.6) Others: 2 (3.7)
Radiation dose	Median: 60 Gy Minimum: 45 Gy
Concurrent TMZ	Yes: 52 (98.1) No: 1 (1.8)
Adjuvant TMZ	>6 cycles: 1 (1.8) 6 cycles: 33 (62.2) 4-5 cycles: 9 (16.9) <3 cycles: 5 (9.4) None: 5 (9.4)
Total adjuvant TMZ duration	Median: 5 months
Hospital admission while treatment including adjuvant TMZ	Yes: 7 (13.2) No: 46 (86.7)
Hematological toxicities while on RT	Grade II: 4 (7.5) Grade I: 2 (3.7)
Acute CNS toxicities	Grade I: 25 (47.1) None: 28 (52.8)

MRI – Magnetic resonance imaging; VMAT – Volumetric modulated arc therapy; IMRT – Intensity-modulated radiotherapy; TMZ – Temozolomide; RT – Radiotherapy; CNS – Central nervous system; NA – Not available

The median follow-up duration was 25 months, and till the last follow-up, 46 out of 53 patients were evaluable with 8 deaths and 55% having stable to CR.

The median DFS and OS were 24 and 25 months, respectively. At 2 years, the DFS and OS were 75% and 88%, respectively, and at 3 years, it was 65% and 78%, respectively [Figures 1 and 2].

On univariate analysis for DFS, KPS at presentation >90 ($P = 0.001$) and response at 6 months ($P = 0.02$) were significant, and for OS, KPS at presentation ($P = 0.004$) was a significant factor [Figure 3]. GTR, no residual at postoperative MRI, up to six cycles of adjuvant TMZ, and CR at 6 months were favorable in terms of both DFS and OS [Figure 4]. Histopathological types were not significant for DFS and OS, and only three patients

were 1p19q co-deletion positive. The details are in Table 3.

QOL scales suggested decline in mood, cognition, fatigue and toilet control initially, and improvement beyond 3 months. There were no significant late effects till the last follow-up.

Discussion

Postoperative RT improves survival of Grade III and IV glial tumors have been explained long back in the Brain Tumor Study Group in 1978 and 1980.^[2,13] The introduction of TMZ has been monumental in the hitherto dismal scenario of GBM.^[6,7] The management of AGs has also been to various phases of RT alone, to BCNU chemotherapy to PCV for a specific subgroup to TMZ and other biological agents.^[14-16] The surgical techniques of

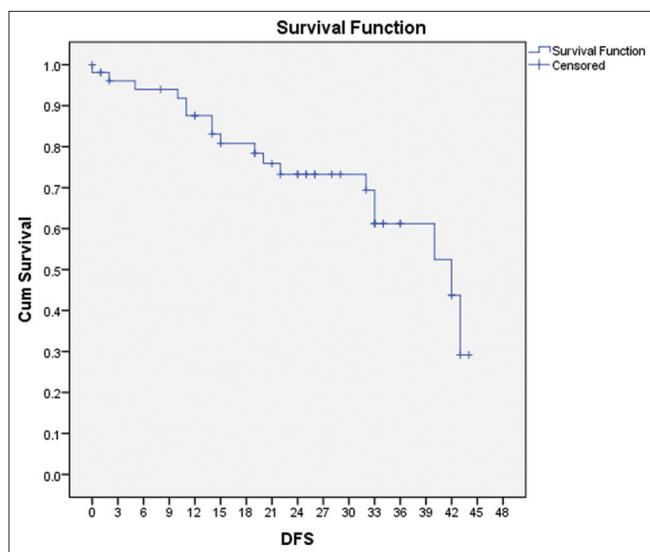


Figure 1: Disease-free survival of the cohort

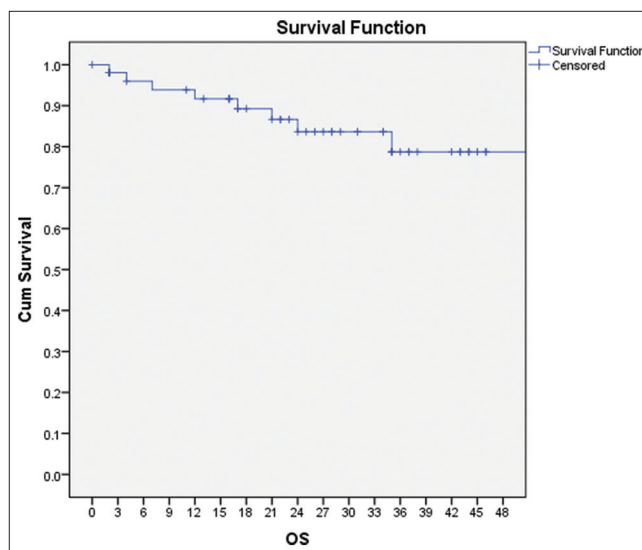


Figure 2: Overall survival of the cohort

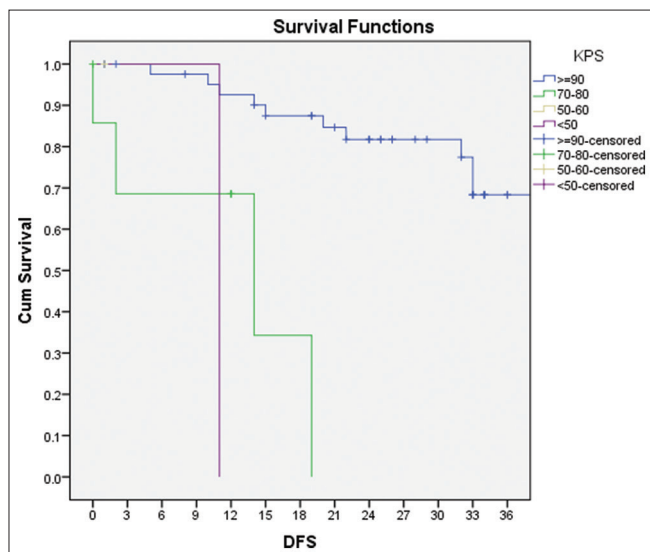


Figure 3: Karnofsky performance status and disease-free survival of the cohort

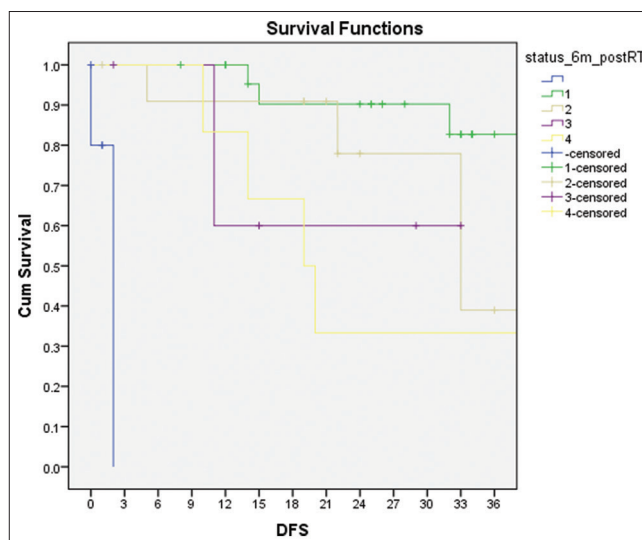


Figure 4: Disease-free survival and status 6-month postradiotherapy + temozolomide

Table 3: Response and survival data

Characteristics	n (%)
Status 1-month post-RT	CR: 17 (32.1) PR: 23 (43.4) SD: 10 (18.9) PD: 3 (5.7)
Status 3-month post-RT (n=51)	CR: 22 (41.5) PR: 19 (35.8) SD: 8 (15) PD: 2 (3.7)
Status 6-month post-RT (n=51)	CR: 24 (45.2) PR: 12 (22.6) SD: 8 (15) PD: 7 (13.2)
LFU-DFS status	NED: 17 (32) Stable disease: 15 (28.3) Progressive disease: 17 (32) Not known: 4 (7.5)
LFU-OS status	Alive: 38 (71.6) Dead: 8 (15) Lost to follow-up: 8 (15)
DFS	Median: 24 months 2 years: 75 3 years: 65
OS	Median: 25 months 2 years: 88 3 years: 78

CR – Complete response; DFS – Disease-free survival; PR – Partial response; SD – Stable disease; PD – Progressive disease; OS – Overall survival; RT – Radiotherapy; NED – No evidence of disease; LFU – Lost to follow-up

MSR, improvised RT techniques, and molecular markers have also played an important role in shaping the outcome among these patients, and continuous research is still going on.^[11,12,17,18] However, the optimal management still remains a gray zone area.

The varied histopathological and more importantly molecular parameter of AGs has also been a challenge toward effective therapy. We have AA which are mostly 1p19q co-deletion negative and thus behave like GBM and treated with RT and TMZ. Furthermore, on the other hand, we have AOA and AODG expressing co-deletion positivity and thus have always been favored as chemosensitive.^[19-21]

In 2009, the randomized NOA-04 trial highlighted a similar role of RT or chemotherapy as initial treatment of high-grade gliomas with AODG, MGMT status, and better surgical resection been superior. The molecular marker isocitrate dehydrogenase (IDH) has also shown to be most important in that study.^[22] The long-term results of the same trial also failed to prove superiority of PCV or TMZ against each other, but the need of RT and adjuvant treatment was proved beyond doubt.^[10]

The present standard of care outside clinical trials, in most centers, has been adjuvant RT and concurrent TMZ

followed by adjuvant TMZ. Various single-center data suggested the greater use of TMZ in AGs mainly due to ease of administration as outpatient, less toxicity.^[20,23,24] Till the time, we have robust evidence, institutional practice and multidisciplinary discussions, and adoption of a specific treatment regimen should be encouraged.

There are two trials which are specifically addressing these issues. The CATNON trial (European Organisation for Research and Treatment of Cancer [EORTC] 26053, NCT00626990) is examining the addition of TMZ to first-line RT, as concomitant or adjuvant TMZ or both, for patients with tumors without the 1p/19q co-deletion, most of which are AAs.^[25] On the other hand, the amended three-group CODEL trial (NCT00887146) will compare RT followed by PCV versus TMZ concurrent with RT followed by adjuvant TMZ versus TMZ alone.^[26]

Keeping with the developments worldwide, our study has been unique in evaluating a uniformly treated cohort of Grade III gliomas with 98% of patients receiving concurrent TMZ with postoperative RT and about 95% adjuvant TMZ. There have also been similar retrospective reviews, highlighting improved survival with RT and TMZ among AA.^[27] The study reported median OS of 32 months with more than 120 patients. Our data reported median OS of 25 months with 53 patients. Another study also showed median OS favoring toward TMZ than RT alone, but they used median 9.5 cycles of adjuvant TMZ.^[28]

Standard prognostic factors for survival in our study were similar to reported international literature. Presentation with epileptic seizure, KPS <70, and biopsy alone instead of surgical removal was poor prognostic factors. Similar results been reported in a surgical series with age ≥65 years, KPS <70, biopsy alone and no adjuvant treatment were confirmed negative prognostic factors for OS.^[29] Compostella *et al.* also reported few prognostic factors for AAs, and our study also had same observations in terms of KPS and epileptic seizures.^[30]

The biggest breakthrough in the management of high-grade gliomas is molecular classification and impact on survival.^[5] MGMT methylation and its impact on GBM survival have been well documented.^[6,7,31] The other important molecular is IDH and its mutation strongly predicts a favorable prognosis in patients with AA.^[32] The role of 1p19q co-deletion and management of AODG have also been long documented, and although very few patients in our study could afford, the ones with co-deletion positive fared better.^[33] There has been enormous research going on and the management of AGs will be tailored as per the molecular classification in near future.^[34,35]

Our study has its own limitations in terms of retrospective nature, limited number of AG patients, inappropriate molecular marker data, and documentation of QOL scales. We are aware of these and the same has been tested in a

prospective manner and the further results could answer them. However, we believe that this is the first ever Indian data for uniformly treated cohort of AG with modulated RT and TMZ and treatment compliance >95%. The results are encouraging and more number of patients with molecular marker data and longer follow-up will only consolidate the early findings.

Conclusion

The early results of AG patients treated uniformly with modulated RT and TMZ have been encouraging. Till we have the results of CANTON and CODEL trials, TMZ can safely be administered among Grade III gliomas receiving adjuvant RT. It is safe to administer, patients tolerate well, and especially with modulated RT minimizing RT dose to normal brain, the outcomes seems promising. We believe that this first ever reported Indian single-center data will invoke enthusiasm for larger prospective documentation with molecular markers and QOL issues.

Acknowledgment

We acknowledge the hard work put in by all the authors as well as other departmental staff in carrying out the research and finally a gratitude toward our ailing patients who inspire us to do better.

Financial support and sponsorship

Nil.

Conflicts of interest

There are no conflicts of interest.

References

- GLOBOCAN 2012 Ver. 1.0, Cancer Incidence and Mortality Worldwide: IARC Cancer Base No. 11. International Agency for Research on Cancer; 2013. Available from: <http://www.globocan.iarc.fr>. [Last accessed on 2014 Feb 19].
- Salazar OM, Rubin P, Feldstein ML, Pizzutiello R. High dose radiation therapy in the treatment of malignant gliomas: Final report. *Int J Radiat Oncol Biol Phys* 1979;5:1733-40.
- Buckner JC. Factors influencing survival in high-grade gliomas. *Semin Oncol* 2003;30 6 Suppl 19:10-4.
- Louis DN, Ohgaki H, Wiestler OD, Cavenee WK, Burger PC, Jouvet A, et al. The 2007 WHO classification of tumours of the central nervous system. *Acta Neuropathol* 2007;114:97-109.
- Louis DN, Perry A, Reifenberger G, von Deimling A, Figarella-Branger D, Cavenee WK, et al. The 2016 World Health Organization classification of tumors of the central nervous system: A summary. *Acta Neuropathol* 2016;131:803-20.
- Stupp R, Mason WP, van den Bent MJ, Weller M, Fisher B, Taphoorn MJ, et al. Radiotherapy plus concomitant and adjuvant temozolomide for glioblastoma. *N Engl J Med* 2005;352:987-96.
- Stupp R, Hegi ME, Mason WP, van den Bent MJ, Taphoorn MJ, Janzer RC, et al. Effects of radiotherapy with concomitant and adjuvant temozolomide versus radiotherapy alone on survival in glioblastoma in a randomised phase III study: 5-year analysis of the EORTC-NCIC trial. *Lancet Oncol* 2009;10:459-66.
- Cairncross G, Wang M, Shaw E, Jenkins R, Brachman D, Buckner J, et al. Phase III trial of chemoradiotherapy for anaplastic oligodendroglioma: Long-term results of RTOG 9402. *J Clin Oncol* 2013;31:337-43.
- van den Bent MJ, Brandes AA, Taphoorn MJ, Kros JM, Kouwenhoven MC, Delattre JY, et al. Adjuvant procarbazine, lomustine, and vincristine chemotherapy in newly diagnosed anaplastic oligodendroglioma: Long-term follow-up of EORTC brain tumor group study 26951. *J Clin Oncol* 2013;31:344-50.
- Wick W, Roth P, Hartmann C, Hau P, Nakamura M, Stockhammer F, et al. Long-term analysis of the NOA-04 randomized phase III trial of sequential radiochemotherapy of anaplastic glioma with PCV or temozolomide. *Neuro Oncol* 2016;18:1529-37.
- Speirs CK, Simpson JR, Robinson CG, DeWees TA, Tran DD, Linette G, et al. Impact of 1p/19q codeletion and histology on outcomes of anaplastic gliomas treated with radiation therapy and temozolomide. *Int J Radiat Oncol Biol Phys* 2015;91:268-76.
- Brandes AA, Tosoni A, Cavallo G, Reni M, Franceschi E, Bonaldi L, et al. Correlations between O6-methylguanine DNA methyltransferase promoter methylation status, 1p and 19q deletions, and response to temozolomide in anaplastic and recurrent oligodendroglioma: A prospective GICNO study. *J Clin Oncol* 2006;24:4746-53.
- Walker MD, Strike TA, Sheline GE. An analysis of dose-effect relationship in the radiotherapy of malignant gliomas. *Int J Radiat Oncol Biol Phys* 1979;5:1725-31.
- Walker MD, Alexander E Jr., Hunt WE, MacCarty CS, Mahaley MS Jr., Mealey J Jr., et al. Evaluation of BCNU and/or radiotherapy in the treatment of anaplastic gliomas. A cooperative clinical trial. *J Neurosurg* 1978;49:333-43.
- Stenning SP, Freedman LS, Bleeher NM. An overview of published results from randomized studies of nitrosoureas in primary high grade malignant glioma. *Br J Cancer* 1987;56:89-90.
- Lonardi S, Tosoni A, Brandes AA. Adjuvant chemotherapy in the treatment of high grade gliomas. *Cancer Treat Rev* 2005;31:79-89.
- Lassman AB, Iwamoto FM, Cloughesy TF, Aldape KD, Rivera AL, Eichler AF, et al. International retrospective study of over 1000 adults with anaplastic oligodendroglial tumors. *Neuro Oncol* 2011;13:649-59.
- Paulsson AK, McMullen KP, Peiffer AM, Hinson WH, Kearns WT, Johnson AJ, et al. Limited margins using modern radiotherapy techniques does not increase marginal failure rate of glioblastoma. *Am J Clin Oncol* 2014;37:177-81.
- Wick W, Wiestler B, Platten M. Treatment of anaplastic glioma. *Cancer Treat Res* 2015;163:89-101.
- Lassman AB. Procarbazine, lomustine and vincristine or temozolomide: Which is the better regimen? *CNS Oncol* 2015;4:341-6.
- Lecavalier-Barsoum M, Quon H, Abdulkarim B. Adjuvant treatment of anaplastic oligodendrogliomas and oligoastrocytomas. *Cochrane Database Syst Rev* 2014;(5):CD007104.
- Wick W, Hartmann C, Engel C, Stoffels M, Felsberg J, Stockhammer F, et al. NOA-04 randomized phase III trial of sequential radiochemotherapy of anaplastic glioma with procarbazine, lomustine, and vincristine or temozolomide. *J Clin Oncol* 2009;27:5874-80.
- Yu T, Kang HC, Lim DH, Kim IH, Chung WK, Suh CO, et al. Pattern of care of anaplastic oligodendroglioma and oligoastrocytoma in a Korean population: The Korean Radiation Oncology Group study 13-12. *J Neurooncol* 2015;121:531-9.

24. Hart MG, Garside R, Rogers G, Stein K, Grant R. Temozolomide for high grade glioma. *Cochrane Database Syst Rev* 2013;(4):CD007415.
25. Phase III Trial of Anaplastic Glioma Without 1p/19q LOH (CATNON). Identifier: NCT00626990. Available from: <http://www.ClinicalTrials.gov>. [Last accessed 2017 Jul 26].
26. Jaeckle K, Vogelbaum M, Ballman KV, et al. CODEL (Alliance-N0577; EORTC-26081/22086; NRG-1071; NCIC-CEC-2): Phase III Randomized Study of RT vs. RT+TMZ vs. TMZ for Newly Diagnosed 1p/19q-Codeleted Anaplastic Oligodendroglial Tumors. Analysis of Patients Treated on the Original Protocol Design. *Neurology* 2016;86 Suppl 16: Abstract PL02.005.
27. Strowd RE, Abuali I, Ye X, Lu Y, Grossman SA. The role of temozolomide in the management of patients with newly diagnosed anaplastic astrocytoma: A comparison of survival in the era prior to and following the availability of temozolomide. *J Neurooncol* 2016;127:165-71.
28. Shonka NA, Theeler B, Cahill D, Yung A, Smith L, Lei X, *et al.* Outcomes for patients with anaplastic astrocytoma treated with chemoradiation, radiation therapy alone or radiation therapy followed by chemotherapy: A retrospective review within the era of temozolomide. *J Neurooncol* 2013;113:305-11.
29. Rogne SG, Konglund A, Scheie D, Helseth E, Meling TR. Anaplastic astrocytomas: Survival and prognostic factors in a surgical series. *Acta Neurochir (Wien)* 2014;156:1053-61.
30. Compostella A, Tosoni A, Blatt V, Franceschi E, Brandes AA. Prognostic factors for anaplastic astrocytomas. *J Neurooncol* 2007;81:295-303.
31. Hegi ME, Diserens AC, Gorlia T, Hamou MF, de Tribolet N, Weller M, *et al.* MGMT gene silencing and benefit from temozolomide in glioblastoma. *N Engl J Med* 2005;352:997-1003.
32. Kizilbash SH, Giannini C, Voss JS, Decker PA, Jenkins RB, Hardie J, *et al.* The impact of concurrent temozolomide with adjuvant radiation and IDH mutation status among patients with anaplastic astrocytoma. *J Neurooncol* 2014;120:85-93.
33. Rajmohan KS, Sugur HS, Shwetha SD, Ramesh A, Thennarasu K, Pandey P, *et al.* Prognostic significance of histomolecular subgroups of adult anaplastic (WHO Grade III) gliomas: Applying the 'integrated' diagnosis approach. *J Clin Pathol* 2016;69:686-94.
34. Eckel-Passow JE, Lachance DH, Molinaro AM, Walsh KM, Decker PA, Sicotte H, *et al.* Glioma groups based on 1p/19q, IDH, and TERT promoter mutations in tumors. *N Engl J Med* 2015;372:2499-508.
35. Yan H, Parsons DW, Jin G, McLendon R, Rasheed BA, Yuan W, *et al.* IDH1 and IDH2 mutations in gliomas. *N Engl J Med* 2009;360:765-73.