

Solitary Duodenal Metastasis from Renal Cell Carcinoma with Metachronous Pancreatic Neuroendocrine Tumor: Review of Literature with a Case Discussion

Abstract

Renal cell carcinoma (RCC) is a unique malignancy with features of late recurrences, metastasis to any organ, and frequent association with second malignancy. It most commonly metastasizes to the lungs, bones, liver, renal fossa, and brain although metastases can occur anywhere. RCC metastatic to the duodenum is especially rare, with only few cases reported in the literature. Herein, we review literature of all the reported cases of solitary duodenal metastasis from RCC and cases of neuroendocrine tumor (NET) as synchronous/metachronous malignancy with RCC. Along with this, we have described a unique case of an 84-year-old man who had recurrence of RCC as solitary duodenal metastasis after 37 years of radical nephrectomy and metachronous pancreatic NET.

Keywords: Late recurrence, pancreatic neuroendocrine tumor, renal cell carcinoma, second malignancy, solitary duodenal metastasis

Saphalta Baghmar,
S M Shashtry¹,
Rajesh Singla,
Yashwant Patidar²,
Chhagan B Bihari³,
S K Sarin¹

Departments of Medical
Oncology, ¹Hepatology,
²Radiology and ³Pathology,
Institute of Liver and Biliary
Sciences, New Delhi, India

Introduction

Renal cell carcinoma (RCC) is unique to have many unusual features such as metastasis to almost every organ in the body, late recurrences, and frequent association with second malignancy. The most common sites of metastasis are the lung, lymph nodes, liver, bone, adrenal glands, kidney, brain, heart, spleen, and skin. Solitary duodenal metastasis from RCC is one of the unusual sites of metastasis. Late recurrences can be as long as 32.7 years.^[1] Second malignancies associated with RCC have been reported with an incidence that varies from 5% to 27%.^[2,3] Here, we have reviewed all the reported cases of RCC with solitary duodenal metastasis and cases of synchronous/metachronous neuroendocrine tumor (NET). Here, we present a unique case of a patient with duodenal metastasis who presented with anemia and gastrointestinal (GI) bleeding, 37 years after nephrectomy. Duodenal biopsy performed revealed metastasis from RCC. He also had a history of recurrent diarrhea and abdominal pain, and on evaluation, he found to have cytology-proven metachronous pancreatic NET.

This is an open access journal, and articles are distributed under the terms of the Creative Commons Attribution-NonCommercial-ShareAlike 4.0 License, which allows others to remix, tweak, and build upon the work non-commercially, as long as appropriate credit is given and the new creations are licensed under the identical terms.

For reprints contact: reprints@medknow.com

Case Presentation

An 84-year-old man with a medical history notable for hypertension and RCC, 37 years postright radical nephrectomy status, presented to his primary care physician with fatigue. When found to be anemic, he was treated with iron supplementation and blood transfusions. His stool was heme-positive. There was no history of jaundice, abdominal distension, bleeding tendency, melena, or altered sensorium. Laboratory investigations on admission were significant for microcytic hypochromic anemia with hemoglobin 6.8 g/dl and hematocrit 16.8%. Liver enzymes and serum levels of the tumor markers CA 19-9 and carcinoembryonic antigen were within normal range. Serum chromogranin levels were more than 650 ng/ml.

His history also included his presentation with repeated increased frequency of stool 3–4/day, semisolid without blood or mucus in December 2006. 68Ga-labelled [1,4,7,10-tetraazacyclododecane-1,4,7,10-tetraacetic acid]-1-Nal3-octreotide (68Ga-DOTA-NOC) positron-emission tomography (PET) suggested enhancing pancreatic head (HOP) mass with central necrosis which was non-fluoro deoxycolic

How to cite this article: Baghmar S, Shashtry SM, Singla R, Patidar Y, Bihari CB, Sarin SK. Solitary duodenal metastasis from renal cell carcinoma with metachronous pancreatic neuroendocrine tumor: Review of literature with a case discussion. Indian J Med Paediatr Oncol 2019;40:S185-90.

Address for correspondence:
Dr. Saphalta Baghmar,
Department of Medical
Oncology, Institute of Liver and
Biliary Sciences, Vasant Kunj,
New Delhi - 110 070, India.
E-mail: drbsaphalta@gmail.com

Access this article online

Website: www.ijmpo.org

DOI: 10.4103/ijmpo.ijmpo_214_17

Quick Response Code:



glucose (FDG) avid on PET-computed tomography. With the suspicion NET, the patient was advised surgery, but he denied any intervention.

For the current presentation, the patient underwent upper GI endoscopy which was suggestive of a large hiatus hernia with a large polypoidal lesion in D1–D2 junction, with ulcerations, without any active bleed [Figure 1a]. Endoscopic ultrasound was done which showed an ill-defined mass lesion measuring 7.8 cm × 7.8 cm in the HOP, not infiltrating into adjacent duodenum. The superior mesenteric vein was splayed by the mass. Gastroduodenal

artery was piercing the mass, but the flow was intact. Duodenal polypoidal mass was arising from the second layer with intact third and fourth layer [Figure 1b].

The HOP mass (8.3 cm × 6.2 cm × 6.2 cm) was more 68Ga-DOTA-NOC avid while the D1–D2 mass (2.4 cm × 2.9 cm) was more FDG avid [Figure 2].

Tissue was obtained from both the pancreatic as well as the duodenal lesions. HOP mass turned out to be NET [Figure 3a, grade could not be ascertained as tissue was inadequate for Ki-67 index] while the duodenal lesion was recurrence of RCC [Figure 3b, showing surface epithelial denudation and lamina propria are infiltrated by tumor glands which are positive for CD10 [Figure 3c], Paired box (PAX) 8, and vimentin and negative for cytokeratin, CD20, synaptophysin, chromogranin, indicating metastatic RCC].

He was advised tablet sunitinib which is effective in both as the lesion was unresectable. He opted for only symptomatic management.

Discussion

Late recurrences

RCC has a potential to metastasize to any organ in an unpredictable manner, and late recurrence is a known

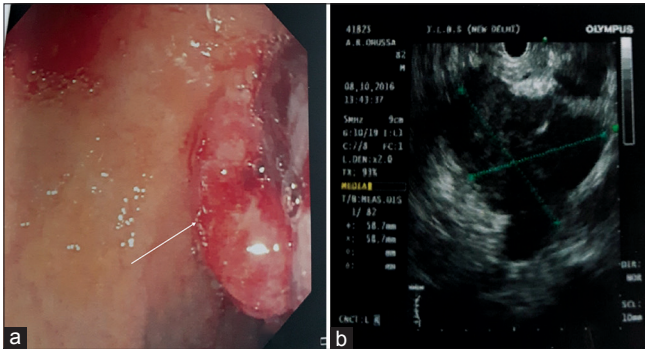


Figure 1: (a) Endoscopic image of polypoidal lesion (white arrow) in D1–D2 junction; (b) endoscopic ultrasound image showing pancreatic head mass

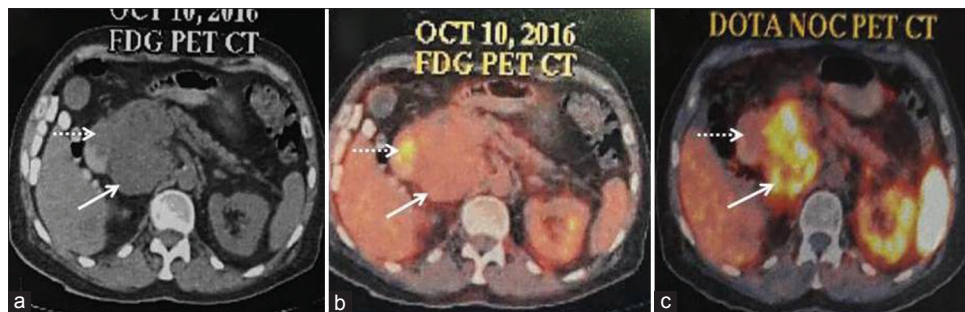


Figure 2: Axial fluoro deoxyglucose positron-emission tomography and (1,4,7,10-tetraazacyclododecane-1,4,7,10-tetraacetic acid)-1-Nal3-octreotide positron-emission tomography image of the upper abdomen reveal large soft tissue intensely (1,4,7,10-tetraazacyclododecane-1,4,7,10-tetraacetic acid)-1-Nal3-octreotide avid and fluoro deoxyglucose positron-emission tomography nonavid mass in the head and uncinate process of pancreas (white arrows in image a, b, and c) and another polypoidal intraluminal fluoro deoxyglucose positron-emission tomography avid and (1,4,7,10-tetraazacyclododecane-1,4,7,10-tetraacetic acid)-1-Nal3-octreotide nonavid mass in D2 part of duodenum (dashed white arrows in image a, b, and c)

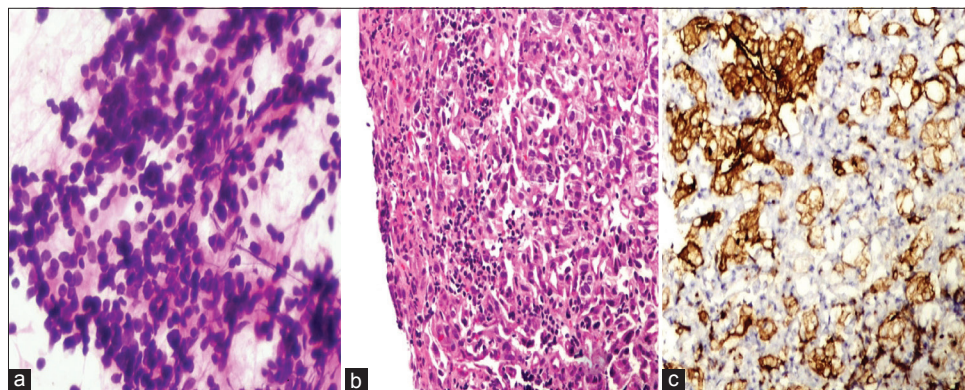


Figure 3: (a) Fine-needle aspiration cytology smear showing loosely cohesive sheet of monomorphic tumor cells with nuclear streaking. Nuclei have even distribution of stippled chromatin: indicating neuroendocrine tumor; (b) duodenal biopsy showing surface epithelial denudation and lamina propria is infiltrated by tumor glands; (c) the glands are positive CD10, indicating metastatic RCC

feature. Eleven percent of these metastases have been described in the literature as occurring more than 10 years after the initial radical surgical procedure.^[4] Ours has very exceptional late recurrence after 37 years. This suggests that very long follow-up and surveillance are necessary in RCC. It is important to remain vigilant in postnephrectomy patients on presentation of new clinical symptoms.

Sites of metastasis

The routes for metastasis can be hematogenous, lymphatic, or peritoneal dissemination as well as direct spread from an intra-abdominal malignancy.^[5] The most common sites of metastasis in the descending order of frequency are the lung, lymph nodes, liver, bone, adrenal glands, kidney, brain, heart, spleen, and skin.^[5] It is also known to have metastasis to unusual sites.^[6] Duodenal metastasis generally occurs when there is widespread nodal and visceral involvement and evidence of metastatic disease

elsewhere in the body.^[7] Our case had solitary duodenal metastasis from RCC which is rare and only few cases have been described in the English literature [Table 1]. The patients commonly present with GI bleeding and sequelae may include anemia, melena, fatigue, and early satiety as in our case or intestinal obstruction.^[19] Such metastatic lesions to the upper GI tract are sometimes diagnosed on endoscopy.^[28] Endoscopically, they are seen as submucosal tumors and polypoid masses, with erosion, plaque, or ulceration being the usual morphological findings.^[19] In the present case, the metastatic lesion was seen as ill-defined polypoidal mass lesion measuring 2.9 cm × 2.2 cm with ulceration in the second part of duodenum.

Treatment

Treatment options in a case of RCC metastasis depend on the extent and location of the lesion, so the therapy must be individualized. Procedures ranging from

Table 1: Summary of case reports on solitary duodenal metastasis from renal cell cancer in English literature

Ref	Year	Age/sex	Years postnephrectomy	Presentation	Treatment	Survival (months)
Baghmar <i>et al.</i>	This article	84/male	37	Easy fatigue, anemia	Supportive care	12
Geramizadeh <i>et al.</i> ^[8]	2015	61/male	16	GI bleeding	Classic Whipple	NA
Hu ^[9]	2014	57/male	12	Fatigue, dyspepsia, black tarry stools, generalized weakness	Pancreaticoduodenectomy	6
Zhao <i>et al.</i> ^[10]	2012	56/male	5	GI bleeding	Classic Whipple	NA
Yang <i>et al.</i> ^[11]	2012	72/male	10	GI bleeding	Classic Whipple	NA
Rustagi <i>et al.</i> ^[12]	2011	66/male	13	Easy fatigue, anemia, GI bleeding	Pylorus-preserving pancreaticoduodenectomy	NA
Vashi <i>et al.</i> ^[13]	2011	53/male	2 weeks	GI bleeding	Segmental resection	3
Adamo <i>et al.</i> ^[14]	2008	86/female	13	Easy fatigue, anemia	Classic Whipple	7
Sadler <i>et al.</i> ^[15]	2007	75/male	9	Anemia	Supportive care	NA
Pavlakis <i>et al.</i> ^[16]	2004	65/male	2	Obstruction	Intestinal resection	9
Chang <i>et al.</i> ^[17]	2004	63/female	9	GI bleeding	Radical subtotal gastrectomy	10
Loualidi <i>et al.</i> ^[18]	2004	76/male	5	GI bleeding	Palliative radiotherapy	NA
Nabi <i>et al.</i> ^[19]	2001	40/male	4	Epigastric pain, obstruction with bilious vomiting	Proximal gastrojejunol bypass	Died 7 days post-op of sepsis
Le Borgne <i>et al.</i> ^[20]	2000	72/female	7	GI bleeding	Classical Whipple	18
Le Borgne <i>et al.</i> ^[20]	2000	48/male	13	GI bleeding	Classical Whipple	53
Ohmura <i>et al.</i> ^[21]	2000	62/male	5	Obstruction	Embolization+local resection	-
Toh and Hale ^[22]	1996	59/female	10	Abdominal pain, anorexia	Duodenotomy, excision of mass	NA
Freedman <i>et al.</i> ^[23]	1992	65/male	12	GI bleeding, fatigue	Classical Whipple	66
Lynch-Nyhan <i>et al.</i> ^[24]	1987	16/male	1	GI bleeding	Embolization	6
Lynch-Nyhan <i>et al.</i> ^[24]	1987	61/male	6	Jaundice	Embolization	NA
McNichols <i>et al.</i> ^[4]	1981	52/male	10	Malabsorption	Diagnostic only	NA
Heymann and Vieta ^[25]	1978	64/male	8	GI bleeding	Complex procedure	3 weeks
Tolia and Whitmore ^[26]	1975	-/male	16	NA	NA	5
Lawson <i>et al.</i> ^[27]	1966	69/female	0	GI bleeding	Classical Whipple	NA

GI – Gastrointestinal; NA – Not available

Table 2: Summary of cases of neuroendocrine tumor with renal cell cancer

Author	Year	Age/sex	Site of NET origin	Treatment	Survival/follow up in months
Baghmar <i>et al.</i>	Present article	84/male	Pancreas	Supportive care	12
Edwards <i>et al.</i> ^[40]	2017	71/female	Ileocecal valve	Right hemicolectomy, radical nephrectomy	NA
Athiyappan <i>et al.</i> ^[41]	2015	56/male	Rectum	Radical nephrectomy and chemotherapy	3
Sun <i>et al.</i> ^[42]	2013	37/male	Horseshoe kidney	Surgical resection	9
Morelli <i>et al.</i> ^[43]	2007	27/male	Gallbladder	Cholecystectomy with partial hepatectomy and a polar renal resection	NA
Dafashy <i>et al.</i> ^[2]	2016	66/male	Ileum	Radical nephrectomy, ileal resection	20
Addeo <i>et al.</i> ^[44]	2013	27/female	Pancreas	Whipple procedure and wedge resections of the right renal neoplasm	6

NA – Not available; NET – Neuroendocrine tumor

Classic Whipple to transarterial embolization have been reported.^[14] For disseminated malignancy, mainly supportive care and therapeutic methods including palliative surgery, radiotherapy, chemotherapy, target therapy (sunitinib), or immune-stimulating agents (interleukin-2) have been used.^[6,29,30] In our case, the duodenal metastasis was large and unresectable, he was advised sunitinib, but he opted for best supportive care.

Survival

In a large series of unusual sites of metastasis from RCC reported that the patients who present with an initial solitary metastatic lesion to an unusual site had a better survival compared to patients who primarily presented with multiple metastases, 17.0 versus 3.0 months. Resection of the unusual metastasis improved survival.^[6] Kavolius *et al.*^[31] reported in their series of 278 patients with recurrent RCC after a disease-free interval longer than 1 year had better prognosis while Villarreal-Garza *et al.* found none.^[6]

Second primary malignancy

Incidence of synchronous or metachronous RCC with other malignancy has been reported in 3.7% of cases.^[32] Such malignancies include intrahepatic cholangiocarcinoma,^[33] hepatocellular carcinoma,^[34] nasopharyngeal carcinoma,^[35] urological cancers,^[36] stomach cancer, esophageal carcinomas, duodenal carcinoma,^[37] colorectal carcinomas, lung cancer, breast cancer, gynecological cancer, sarcoma and non-Hodgkin's lymphoma,^[38] and melanoma.^[39] We could find only six cases of synchronous/metachronous NET with RCC in the English literature [Table 2]. Our patient developed pancreatic NET during follow-up of RCC, postnephrectomy.

At present, he has duodenal metastasis from RCC measuring 2.9 cm × 2.4 cm and pancreatic NET measuring 8.4 cm × 6.2 cm × 6.2 cm.

Conclusion

To highlight, solitary metastatic RCC to the duodenum is extremely rare. Awareness of this entity and aggressive workup of GI symptoms in patients postnephrectomy for

RCC are very important. In these patients with symptoms of GI bleeding, fatigue, anemia, and early satiety or obstruction, all should undergo complete endoscopic evaluation and biopsy, as well as radiologic investigation to evaluate for the presence and the extent of metastatic disease. Any patient with solitary metastatic RCC to the duodenum should be considered a candidate for complete surgical excision if medically and technically feasible, both for palliation of symptoms, and because it gives the opportunity for better survival.

Based on this case report and the literature, we believe that the practicing physicians should be aware of the unique feature of RCC for risk of a simultaneous separate primary malignancy and approach patients' new symptoms with diligence. The presence of any clinical or radiological conflicting lesion should be further evaluated.

Declaration of patient consent

The authors certify that they have obtained all appropriate patient consent forms. In the form the patient(s) has/have given his/her/their consent for his/her/their images and other clinical information to be reported in the journal. The patients understand that their names and initials will not be published and due efforts will be made to conceal their identity, but anonymity cannot be guaranteed.

Financial support and sponsorship

Nil.

Conflicts of interest

There are no conflicts of interest.

References

- Thompson LD, Heffess CS. Renal cell carcinoma to the pancreas in surgical pathology material. *Cancer*. 2000;89:1076-88.
- Dafashy TJ, Ghaffary CK, Keyes KT, Sonstein J. Synchronous Renal Cell Carcinoma and Gastrointestinal Malignancies. *Case Rep Urol* 2016;2016:e7329463.
- Müller SA, Pahernik S, Hinz U, Martin DJ, Wente MN, Hackert T, *et al.* Renal tumors and second primary pancreatic tumors: a relationship with clinical impact? *Patient Saf Surg*. 2012;6:18.

4. McNichols DW, Segura JW, DeWeerd JH. Renal cell carcinoma: long-term survival and late recurrence. *J Urol* 1981;126:17-23.
5. Ritchie AW, Chisholm GD. The natural history of renal carcinoma. *Semin Oncol*. 1983;10:390-400.
6. Villarreal-Garza C, Perez-Alvarez SI, Gonzalez-Espinoza IR, Leon-Rodriguez E. Unusual Metastases in Renal Cell Carcinoma: A Single Institution Experience and Review of Literature. *World J Oncol*. 2010;1:149-57.
7. Dodge OG. The Spread of Tumours in the Human Body. *Br J Cancer*. 1974;29:343-4.
8. Geramizadeh B, Mostaghni A, Ranjbar Z, Moradian F, Heidari M, Khosravi MB, *et al.* An Unusual Case of Metastatic Renal Cell Carcinoma Presenting as Melena and Duodenal Ulcer, 16 Years After Nephrectomy; a Case Report and Review of the Literature. *Iran J Med Sci* 2015;40:175-80.
9. Jeming Hu, Sheng-Tang Wu, Yu-Chieh Lin. Metachronous Duodenal Metastasis from Renal Cell Carcinoma. *J Med Sci* 2014;34:186-9.
10. Zhao H, Han K, Li J, Liang P, Zuo G, Zhang Y, *et al.* A case of wedge resection of duodenum for massive gastrointestinal bleeding due to duodenal metastasis by renal cell carcinoma. *World J Surg Oncol* 2012;10:199.
11. Yang J, Zhang YB, Liu ZJ, Zhu YF, Shen LG. Surgical treatment of renal cell carcinoma metastasized to the duodenum. *Chin Med J (Engl)* 2012;125:3198-200.
12. Rustagi T, Rangasamy P, Versland M. Duodenal Bleeding from Metastatic Renal Cell Carcinoma. *Case Rep Gastroenterol*. 2011;5:249-57.
13. Vashi PG, Abboud E, Gupta D. Renal Cell Carcinoma with Unusual Metastasis to the Small Intestine Manifesting as Extensive Polyposis: Successful Management with Intraoperative Therapeutic Endoscopy. *Case Rep Gastroenterol*. 2011;5:471-8.
14. Adamo R, Greaney PJ, Witkiewicz A, Kennedy EP, Yeo CJ. Renal Cell Carcinoma Metastatic to the Duodenum: Treatment by Classic Pancreaticoduodenectomy and Review of the Literature. *J Gastrointest Surg* 2008;12:1465-8.
15. Sadler GJ, Anderson MR, Moss MS, Wilson PG. Metastases from renal cell carcinoma presenting as gastrointestinal bleeding: two case reports and a review of the literature. *BMC Gastroenterol*. 2007;7:4.
16. Pavlakakis GM, Sakorafas GH, Anagnostopoulos GK. Intestinal metastases from renal cell carcinoma: a rare cause of intestinal obstruction and bleeding. *Mt Sinai J Med N Y* 2004;71:127-30.
17. Chang WT, Chai CY, Lee KT. Unusual upper gastrointestinal bleeding due to late metastasis from renal cell carcinoma: a case report. *Kaohsiung J Med Sci* 2004;20:137-41.
18. Loualidi A, Spooren PF, Grubben MJ, Blomjous CE, Goey SH. Duodenal metastasis: An uncommon cause of occult small intestinal bleeding. *Neth J Med* 2004;62:201-5.
19. Nabi G, Gandhi G, Dogra PN. Diagnosis and management of duodenal obstruction due to renal cell carcinoma. *Trop Gastroenterol Off J Dig Dis Found* 2001;22:47-9.
20. Le Borgne J, Partensky C, Glemain P, Dupas B, de Kerviller B. Pancreaticoduodenectomy for metastatic ampullary and pancreatic tumors. *Hepatogastroenterology* 2000;47:540-4.
21. Ohmura Y, Ohta T, Doihara H, Shimizu N. Local recurrence of renal cell carcinoma causing massive gastrointestinal bleeding: A report of two patients who underwent surgical resection. *Jpn J Clin Oncol* 2000;30:241-5.
22. Toh SK, Hale JE. Late presentation of a solitary metastasis of renal cell carcinoma as an obstructive duodenal mass. *Postgrad Med J* 1996;72:178-9.
23. Freedman AI, Tomaszewski JE, Van Arsdalen KN. Solitary late recurrence of renal cell carcinoma presenting as duodenal ulcer. *Urology* 1992;39:461-3.
24. Lynch-Nyhan A, Fishman EK, Kadir S. Diagnosis and management of massive gastrointestinal bleeding owing to duodenal metastasis from renal cell carcinoma. *J Urol* 1987;138:611-3.
25. Heymann AD, Vieta JO. Recurrent renal carcinoma causing intestinal hemorrhage. *Am J Gastroenterol* 1978;69:582-5.
26. Tolia BM, Whitmore WF. Solitary metastasis from renal cell carcinoma. *J Urol* 1975;114:836-8.
27. Lawson LJ, Holt LP, Rooke HWP. Recurrent Duodenal Hemorrhage from Renal Carcinoma. *Br J Urol*. 1966;38:133-7.
28. Hsu CC, Chen JJ, Changchien CS. Endoscopic features of metastatic tumors in the upper gastrointestinal tract. *Endoscopy* 1996;28:249-53.
29. Bhatia A, Das A, Kumar Y, Kochhar R. Renal cell carcinoma metastasizing to duodenum: A rare occurrence. *Diagn Pathol* 2006;1:29.
30. Mascarenhas B, Konety B, Rubin JT. Recurrent metastatic renal cell carcinoma presenting as a bleeding gastric ulcer after a complete response to high-dose interleukin-2 treatment. *Urology*. 2001;57:168.
31. Kavolius JP, Mastorakos DP, Pavlovich C, Russo P, Burt ME, Brady MS. Resection of metastatic renal cell carcinoma. *J Clin Oncol Off J Am Soc Clin Oncol* 1998;16:2261-6.
32. Garcia JHP, Coelho GR, Cavalcante FP, Valença JT, Brasil IRC, Cesar-Borges G, *et al.* Synchronous hepatocellular carcinoma and renal cell carcinoma in a liver transplant recipient: a case report. *Transplantation*. 2007;84:1713.
33. Anthony MP, Makk H, Khong PL. An unusual case of synchronous renal cell carcinoma in a horseshoe kidney and intrahepatic cholangiocarcinoma. 2009. Available from: <http://hub.hku.hk/handle/10722/91298>. [Last cited on 2017 Jan 17].
34. Lee YS, Kim JH, Yoon HY, Choe WH, Kwon SY, Lee CH. A synchronous hepatocellular carcinoma and renal cell carcinoma treated with radio-frequency ablation. *Clin Mol Hepatol Clin Mol Hepatol* 2014;20:306-9.
35. Boruban C, Yavas O, Altundag K, Sencan O. Synchronous presentation of nasopharyngeal and renal cell carcinomas. *Int Braz J Urol* 2006;32:310-2.
36. Takehara K, Nishikido M, Koga S, Miyata Y, Harada T, Tamaru N, *et al.* Multifocal transitional cell carcinoma associated with renal cell carcinoma in a patient on long-term haemodialysis. *Nephrol Dial Transplant Off Publ Eur Dial Transpl Assoc - Eur Ren Assoc* 2002;17:1692-4.
37. Yang J, Lee H, Lee OJ, Bae D, Jeong S, Choi MK, *et al.* Synchronous double primary renal cell carcinoma and duodenal adenocarcinoma. *J Biomed Transl Res* 2016;17:70-4.
38. Papalampros AE, Petrou AS, Mantonakis EI, Evangelou KI, Giannopoulos LA, Marinos GG, *et al.* Coexistence of a colon carcinoma with two distinct renal cell carcinomas: a case report. *J Med Case Reports* 2011;5:134.
39. Maubec E, Chaudru V, Mohamdi H, Grange F, Patard JJ, Dalle S, *et al.* Characteristics of the coexistence of melanoma and renal cell carcinoma. *Cancer* 2010;116:5716-24.
40. Edwards DC, Gitman R, May NR, Amster MI. Extraordinarily Large Renal Cell Carcinoma With Metasynchronous Neuroendocrine Tumor of the Ileocecal Valve: A Rare Presentation of Disease. *Urology* 2017;99:e29-30.
41. Athiyappan K, Ramachandran R, Rajendiran S, Thangam V. Incidental Detection of Neuroendocrine Carcinoma of Rectum

- During Staging Workup of Renal Cell Carcinoma. *World J Oncol* 2016;6:491-4.
42. Sun K, You Q, Zhao M, Yao H, Xiang H, Wang L. Concurrent primary carcinoid tumor arising within mature teratoma and clear cell renal cell carcinoma in the horseshoe kidney: report of a rare case and review of the literature. *Int J Clin Exp Pathol* 2013;6:2578-84.
43. Morelli L, Pisciole F, Cudazzo E, Del Nonno F, Licci S. Simultaneous occurrence of metastasizing carcinoid tumour of the gallbladder and chromophobe renal cell carcinoma in a young man. *Acta Gastro-Enterol Belg* 2007;70:371-3.
44. Addeo A, Bini R, Viora T, Bonaccorsi L, Leli R. Von Hippel-Lindau and myotonic dystrophy of Steinert along with pancreatic neuroendocrine tumor and renal clear cell carcinomal neoplasm: Case report and review of the literature. *Int J Surg Case Rep* 2013;4:648-50.